

DOI: <https://dx.doi.org/10.18203/2320-1770.ijrcog20212940>

Original Research Article

## Laparoscopic evaluation of pelvic organ in case of subfertility

Polly Ahmed<sup>1\*</sup>, T. A. Chowdhury<sup>2</sup>, Kaniz Mahmud<sup>2</sup>

<sup>1</sup>Department of Obstetrics and Gynecology, United Hospital Ltd., Dhaka, Bangladesh

<sup>2</sup>Department of Obstetrics and Gynecology, Ibrahim Medical College and BIRDEM, Dhaka, Bangladesh

**Received:** 18 March 2021

**Accepted:** 25 May 2021

**\*Correspondence:**

Dr. Polly Ahmed,

E-mail: [publications971@gmail.com](mailto:publications971@gmail.com)

**Copyright:** © the author(s), publisher and licensee Medip Academy. This is an open-access article distributed under the terms of the Creative Commons Attribution Non-Commercial License, which permits unrestricted non-commercial use, distribution, and reproduction in any medium, provided the original work is properly cited.

### ABSTRACT

**Background:** Globally subfertility affects 10-15% of couple. All these people need proper evaluation and treatment. Now a days laparoscopy considered as a gold standard procedure for evaluation of pelvic organ. The aim of this study was to find out the different causes of female factor infertility with the help of laparoscopy.

**Methods:** This retrospective study was conducted in infertility clinic of BIRDEM hospital, Dhaka, Bangladesh during the period of May, 2007 to October 2007. The study group comprised 100 cases of infertile patients.

**Results:** In this study, among 100 patients 68% had primary and 32% had secondary infertility. In laparoscopy majority (55.0%) had normal ovary, 20.0% had cystic change with thick capsule in right ovary and 22% had in left ovary, 7.0% had endometriosis, 8.0% had adhesion, 10.0% had simple cyst in right ovary and 8% had in left ovary and rest could not be visualized. 79.4% right and 77.9% left fallopian tube patent in primary subfertility cases and 56.3% right and 59.4% left tube normal in secondary subfertility cases. Both fallopian tube patent in 62%, unilateral block 21% and bilateral block in 17% cases in this study peritoneum was normal in 78% cases, 8% cases there was endometriosis and 14% cases there was adhesion of fallopian tube with the ovary, adhesion of uterus with intestine and also with bladder.

**Conclusions:** Laparoscopy is an important tool for diagnosing anatomical and pathological abnormalities of pelvic organ which has a major role in subfertility management.

**Keywords:** Laparoscopy, Pelvic organ, Infertility

### INTRODUCTION

The desire for reproduction is one of the basic attributes of human being and is essential for continuation of species. Infertile couple often passes through a painful tragic life with psychological stress and social disgraces in our community. Infertility is defined as the inability to conceive after for 1 year of unprotected intercourse.<sup>1</sup> It is usually defined as primary when there is absence of preceding pregnancy and secondary when there has been a preceding pregnancy, irrespective of outcome. About 80% couples experiencing unprotected intercourse (4-5 times a week) usually achieving pregnancy within one year an additional 10% will achieve pregnancy in the second year.<sup>2</sup> As such 10% of remain infertile by the end of second year.<sup>3</sup> Male is directly responsible in 35%, the female in 40% and

both are responsible in 10-20% cases. The remaining is unexplained in spite of thorough investigations with modern technical knowledge.<sup>4</sup> It is also a strange that about 4 out of 10 patients of unexplained infertility conceive within 3 years without having any specific treatment.<sup>3</sup> Female infertility may be associated with anovulation, tubal factor, endometriosis, uterine, cervical and immunological factors. An accurate diagnosis is the key to successful treatment. After initial assessment with basic investigation Laparoscopy provide important information to find out the cause. Laparoscopy provide information regarding ovarian and tubal status, uterine normality and standard means of diagnosing various pelvic pathology e.g., pelvic inflammatory disease, endometriosis, pelvic congestion syndrome and tuberculosis. It is the most useful method of assessment of tubal patency. This study was carried out to assess the

pelvic organ, determine the different causes of female subfertility and their comparative frequency in patients with primary and secondary subfertility on laparoscopy at the study center.

**Objectives**

General objective of the study was to present the laparoscopic findings of pelvic organs in cases of subfertility.

Specific objectives of the study were to see the condition of ovaries and the tubo-ovarian relationship and presence of corpus luteum, to assess the condition of the tubes and find out the patency of tubes, to evaluate uterine pathology and to find out any peritoneal factors leading to infertility.

**METHODS**

This retrospective study was conducted in infertility clinic of BIRDEM hospital, Dhaka, Bangladesh from May, 2007 to October 2007. The sample size was 100. Before admission detailed history and clinical examination was done in gynaecology outpatients department. Then clinical examination was then done.

**Inclusion criteria**

Patients suffering from both primary and secondary infertility and age range of patients was 20-40 years were included in the study.

**Exclusion criteria**

Those patients whose husband had abnormality in semen analysis and the patients whose age was above 40 were excluded from the study.

Sets of basic investigations were carried out for fitness of anaesthesia before laparoscopy. Patients selected for Laparoscopy was admitted on 18-21 days of their menstrual cycle.

The study protocol was approved by ethical committee of Bangladesh college of surgeons and physicians (BCPS). Informed consent was taken from the participants before collection of any information.

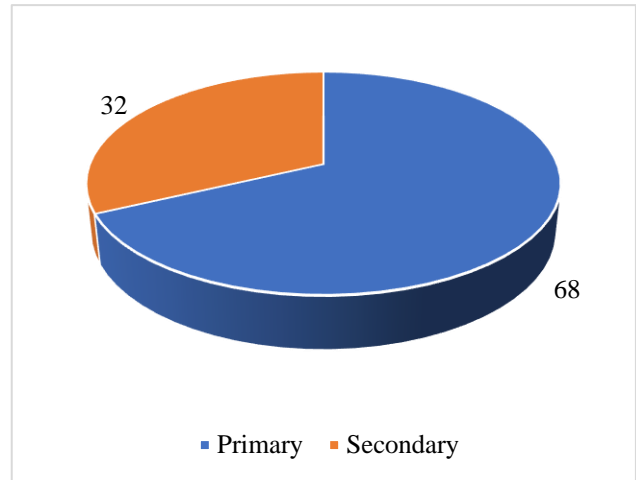
Data collected from each individual subject, were recorded on a pre-designed data collection form. Collected data were compiled and analysed using computer-based software, statistical package for social science (SPSS).

**RESULTS**

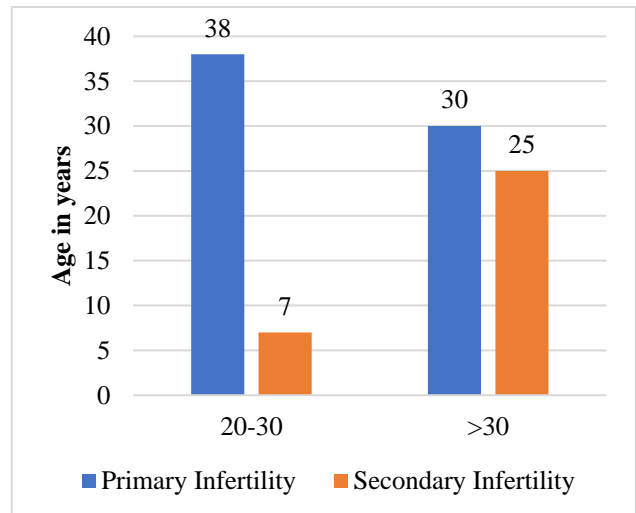
In this study, among 100 patients 68% had primary and 32% had secondary infertility (Figure 1).

Out of all patients of primary infertility 55.9% were within 20 to 30 years age group and 44.1% within above 30 years

age group. Within secondary infertility group 21.9% were within 20 to 30 years age group and 78.1% above 30 years age group (Figure 2).



**Figure 1: Types of infertility, (n=100).**



**Figure 2: Distribution of the patients by age group, (n=100).**

**Table 1: Menstrual history of 1° sub fertility and 2° sub fertility, (n=100).**

Menstrual history	Primary infertility		Secondary infertility		P value
	N	%	N	%	
<b>Menstrual cycle</b>					
Regular	40	58.8	28	87.5	0.004
Irregular	28	41.2	4	12.5	
<b>Amount of loss</b>					
Scanty	12	30	7	25	0.903
Average	20	50	15	53.6	
Excessive	8	20	6	21.4	
<b>Dysmenorrhea</b>					
Yes	20	29.4	8	75	0.647
No	48	70.6	24	25	

All patients of primary infertility 58.8% had regular, 44.2% had irregular cycle 30% had scanty, 20% had menorrhagia and 29.4% had dysmenorrhea. Within secondary infertility group 87.5% had regular, 12.5% had irregular cycle 25% had scanty, 21.4% had menorrhagia and 75% had dysmenorrhea. All patients of primary infertility 58.8% had regular, 44.2% had irregular cycle 30% had scanty, 20% had menorrhagia and 29.4% had dysmenorrhea. Within secondary infertility group 87.5% had regular, 12.5% had irregular cycle 25% had scanty, 21.4% had menorrhagia and 75% had dysmenorrhea (Table 1).

**Table 2: Contraceptive history of infertility cases (n=100).**

H/O contraception	Primary infertility		Secondary infertility		P value
	N	%	N	%	
No H/O contraception	48	70.6	15	46.88	>0.05
Oral pill	6	8.8	10	31.3	0.004
IUCD	0	0	3	9.4	0.03
Barrier method	14	20.6	4	12.5	>0.05

In this study, out of all patients of primary infertility, 70.6% did not practice any method of contraceptive oral pill, 8.8% took oral pill and 20.6% used barrier method. Within secondary infertility group, 46.88% did not practice any method of contraceptive oral pill, 31.3% took oral pill and 12.5% used barrier method (Table 2).

**Table 3: Obstetric history of secondary infertility history, (n=32).**

Characteristics	N	Percentage (%)
<b>Obstetric history</b>		
Live birth	9	28.12
Number of still birth	7	21.87
Abortion	6	18.72
M. R.	10	31.25

In this study 28.12% had live birth, 21.87% had history of still birth 18.72% had history of abortion and 31.25% had history of abortion (Table 3).

**Table 4: Distribution by past relevant history of infertility, (n=100).**

Past-medical/surgical history	Frequency (n=100)	Percent (%)
No past medical history	88	88
Appendicitis	6	6
Ectopic pregnancy	2	2
Salpingitis	2	2
Puerperal sepsis	1	1
Pulmonary TB	1	1

Most of the patient (88.0%) had no past medical or surgical history, 6.0% had history of appendicitis, 2.0% had ectopic pregnancy, 2.0% had salpingitis, 1.0% had puerperal sepsis and 1.0% had pulmonary TB (Table 4).

**Table 5: Distribution of patients by laparoscopic findings of the ovary, (n=100).**

Findings	Left ovary		Right ovary	
	N	%	N	%
Normal ovary	55	55	53	53
<b>Cystic changes with thick capsule (PCO)</b>	20	20	22	22
Endometriosis	7	7	7	7
Adhesion	8	8	8	8
Simple cyst	10	10	8	8
Could not be visualized	2	2	2	2

In laparoscopy 55.0% patient had normal left ovary, 20.0% had cystic change with thick capsule, 7.0% had endometriosis, 8.0% had adhesion, 10.0% had simple cyst and rest could not be visualized. In laparoscopy 55% patient had right ovary, 22% had cystic change with thick capsule, 8% had endometriosis, 7% had adhesion, 8% had simple cyst and rest could not be visualized (Table 5).

**Table 6: Distribution of the morphological changes of fallopian tube in cases of primary and secondary sub fertility, (n=100).**

Laparoscopic evaluation	Primary (%)		Secondary (%)	
	Right	Left	Right	Left
Normal looking	54 (79.4)	53 (77.9)	18 (56.3)	19 (59.4)
Not visualized	0 (0.0)	0 (0.0)	2 (6.3)	0 (0.0)
Peritoneal adhesion	12 (17.6)	14 (20.6)	8 (25)	10 (31.3)
Hydrosalpinx	2 (2.9)	1 (1.5)	4 (12.5)	3 (9.4)

Among the patient with primary infertility-fallopian tube was normal looking in 79.47% on right and 77.9% on left, peritoneal adhesion 17.6% on right and 20.6% on left and hydrosalpinx 2.9% on right and 1.5% on left. Among the patient with secondary infertility-fallopian tube was normal looking in 56.3% on right and 59.4% on left, peritoneal adhesion 25% on right and 31.3% on left and hydrosalpinx 12.5% on right and the 9.4% on left (Table 6).

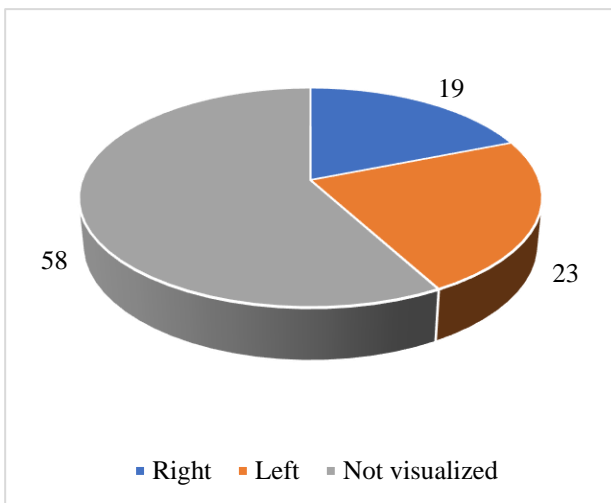
Among the patient with primary infertility-both tubes were patent in 70.65% cases, unilateral tubal block in 17.6% cases and bilateral tubal block in 11.8% cases. Among the patient with secondary infertility-both tubes were patent in 43.8% cases, unilateral tubal block in 28.1% cases and bilateral tubal block in 28.1% cases (Table 7).

**Table 7: Distribution of the patients by tubal patency test, (n=100).**

Findings	Infertility (%)		Total (%)	P value
	Primary (n=68)	Secondary (n=32)		
<b>Both tubal patent</b>	48 (70.6)	14 (43.8)	62 (62)	0.01
<b>Unilateral tubal block</b>	12 (17.6)	9 (28.1)	21 (21)	
<b>Right</b>	4 (33.3)	3 (33.3)	7 (33.3)	1
<b>Left</b>	8 (66.7)	6 (66.7)	14 (66.7)	
<b>Bilateral tubal block</b>	8 (11.8)	9 (28.1)	17 (17)	0.04

**Table 8: Distribution of the patients by laparoscopic findings of other structures (n=100).**

Laparoscopic findings	N	Percentage (%)
<b>Peritoneum</b>		
Normal	78	78
Endometriosis	8	8
Adhesion	14	14
<b>Douglas</b>		
Normal	77	77
Endometriosis deposits	7	7
Adhesion	16	16
<b>Uterus</b>		
Normal	74	74
Small in size	3	3
Bulky	23	23
<b>Mobility of uterus</b>		
Freely mobile	83	83
Restricted in mobility	17	17



**Figure 3: Distribution of the patients by the presence of corpus luteum shown by laparoscopy, (n=100).**

In this study peritoneum was normal in 78% cases, 8% cases there was endometriosis and 14% cases there was adhesion of fallopian tube with the ovary, adhesion of uterus with intestine and also with bladder. In this study, pouch of Douglas was normal in 77% cases, 7% had endometriotic deposits 16% had adhesion and obliteration of pouch of Douglas. In this study 74% of patient had normal size of uterus, 3% had uterus smaller than normal size and 23% had bulky uterus. 83% patient had freely mobile uterus and rest had restricted mobility (Table 8).

**DISCUSSION**

Investigation in many gynecological disorders, especially infertility thought to be incomplete without laparoscopy. Using the laparoscope, we can not only diagnose unsuspected pelvic pathology but also can treat them. It can allow many patients to avoid needless cycles of treatments and the related emotional stress and financial burden. In this study out of 100 infertile patients about 68 (68%) had primary and 32 (32%) had secondary sub fertility. This study was compared with that of Sinawat et al done in Thailand showed 72.03% had primary and 27.97 % had secondary sub fertility.<sup>5</sup> Now more couples are seeking advice from infertility centers and do not hesitate, as they did in former times, to reveal their problem.<sup>4</sup> This study showed out of 100 cases 55 (55%) women were above the age of 30 years and they had already passed the age of optimal fertility (25-29 years), when they were ready to have children and therefore created a problem as regard to fertility.<sup>3</sup> Introduction of laparoscopy has ability to investigate long standing infertility. Uterus, tube, ovary and other pelvic structures can be visualized directly through laparoscope and full information can be obtained about concurrent pelvic disease. Ovarian pathology that causes ovulation, causes infertility. Dysfunction of ovulation, is responsible 20-25% of infertility.<sup>1</sup> In this study normal looking right and left ovaries were 53% and 55% respectively. Cystic enlargement of one or both of normal ovaries is so common as to be regarded physiological. Simple cyst presents 8% in right and 10% in left ovaries. In polycystic ovarian syndrome, patient has slightly enlarged and polycystic ovaries which have a smooth pearly white color and thickened capsule. There is anovulation. So, patient is sub fertile.<sup>1</sup> In this study, cystic changes with thick capsule were seen 22% in right ovary and 20% in left ovary. Similar findings were observed by Nessa in 2002.<sup>6</sup> In 8% cases, ovaries of both sides were visualized, but had adhesion to adjacent structures. In 2% cases both sided ovaries could not be visualized due to adhesion. In this case, ovulation usually occur but infertility may be due to disturbed tubal function. After ovulation, Graafian follicle becomes corpus luteum. It is a vascular structure, yellowish in color. It is identical by its punctum i.e., opening through which ovum come out. Detection of corpus luteum by laparoscopy is the surest sign of ovulation. In this study 19% of cases corpus luteum was seen in right ovary, 23% in left ovary and 58% cases corpus luteum was not visualized. It may due to anovulation or adhesion or due to faulty technique. A

normal fallopian tube is needed for ovum transport, fertilization and transport of fertilized ovum to the uterus. Any abnormality of fallopian tube interfere fertility. Laparoscopy currently regarded as the most reliable tool in the diagnosis of tubal cause of sub fertility. As laparoscopy visualizes morphological abnormalities of fallopian tube directly, it is generally accepted as the reference standard for determination of accuracy of the diagnostic tool for tubal pathology. Incidence of pathology of fallopian tube vary accordingly to sexually transmitted disease, post abortal and puerperal infection. In this study in primary infertility both tubes were found to be blocked in 48%, only one tube patent in 12% and both tubes were patent in 8%. In secondary infertility both tubes were blocked in 14%. Only one tube was patent in 9% and both tubes were patent in 9% cases. In another study of Chowdhury and Chowdhury in case of primary infertility but not in secondary infertility where tube blockage was found in 15% in the former and 17.5% in later group.<sup>7</sup> This finding is much lower than series by Collet where the study was done in Eastern Gabon in the “infertility belt” where the tubal occlusion was present in 82,8% cases in Africa.<sup>8</sup> This high prevalence of tubal occlusion in Africa was probably due to pre-marital sexual intercourse and sexual promiscuity which in general play a major role in primary and secondary sub fertility. On laparoscopy, an infertility factor will be found in 30-50% women previously regarded as normal genitalia. The unexpected findings are commonly peri tubal or periovarian adhesions, and endometriosis.<sup>4</sup> In this study peri tubal adhesion was present 17.6% and 25% at right and 20.6% and 31.3% at left side in primary and secondary infertility respectively. Hydrosalpinx was found in 2.9% in the right and 1.5% in the left in primary subfertility and 12.5% and 9.9% in right and left side respectively in secondary subfertility. Here tubal pathology (peri tubal adhesion and hydrosalpinx) was seen to be more common in secondary infertility cases then the primary infertility. This increased prevalence of peri tubal adhesion and hydrosalpinx in secondary infertility. This increased prevalence of peri tubal adhesion and hydrosalpinx in secondary infertility may be related to history of abortion, MR, still birth and IUCD insertion which are 18.72%, 31.25%, 21.87%, and 9.4% respectively in this study. Similar study done by Khatun, where secondary infertility, following post abortion 59.1%, MR 16%, still birth 9.1%.<sup>9</sup> Post obstetric history is important in cases of secondary sub-fertility. But the prevalence of peri tubal adhesion and hydrosalpinx in primary infertility where there was no such history was not negligible. Here pathology may be related to gonococcal or chlamydial infection on other STD causing asymptomatic pelvic inflammatory disease. In this study, uterus was normal size in 74%, bulky in 23% smaller than normal in size in 3% cases. Normally uterus is freely mobile. Mobility become restricted in endometriosis, pelvic inflammatory disease, tuberculosis, pelvic operation etc. In this study 85% cases uterus was freely mobile, in 17% cases mobility was restricted. Similar findings were observed by Nessa in 2002.<sup>10</sup> Endometriosis is seen in at least 15% of women investigated for

infertility, if all grades are considered. Endometriosis is associated with pelvic adhesion that distort pelvic anatomy, prevent normal tubo-ovarian apposition and encase the ovary. Implants can destroy ovarian and tubal tissue, although occlusion of tube is rare. 50% case endometriosis causes dysmenorrhoea.<sup>2</sup> In this study 28% cases complained dysmenorrhea. Endometriotic deposits in pouch of Douglas and in peritoneum were found in 15% cases and flimsy adhesion in 30% cases. Milingos et al in 2006 documented abnormal findings at laparoscopy in infertile patient with pelvic pain.<sup>11</sup> At laparoscopy 76.7% of patients with pelvic pain were found with pelvic pathology, compared with only 42.6% of cases without pain. Omental abdominal wall adhesions, advanced endometriosis, endometrioma with adhesion were significantly more frequent in cases with pelvic pain. The information regarding the pelvic organs can be obtained by laparoscopy. It is now used as a principal method of assessment of pelvic organs. Though it is an expensive and invasive procedure, de laparoscopy is considered as gold standard for evaluation of subfertility.

### **Limitations**

In our study, there was small sample size and absence of control for comparison. Study population was selected from one center in Dhaka city, so may not represent wider population. The study was conducted at a short period of time. The sampling was retrospective and there was no random allocation, so there is risk of selection bias.

### **CONCLUSION**

Diagnostic laparoscopy is generally accepted as the most accurate procedure to detect anatomical and pathological abnormalities of pelvic organ. It plays an important role for management plan of infertile couple. It is a minimally invasive procedure, requires considerable expertise, its availability is limited to few centers. So, for treating infertility laparoscopy should be made available and affordable to different level of health sectors, so that infertile couple can get benefit of it and achieve their goals of fertility.

*Funding: No funding sources*

*Conflict of interest: None declared*

*Ethical approval: The study was approved by the Institutional Ethics Committee*

### **REFERENCES**

1. Edmonds Dk. Infertility. In Dewhurst's Text book of Obstetrics and Gynaecology. 7<sup>th</sup> ed. London: Black well Science Ltd. 2007;440-60.
2. De Cherney AH, Nathan L. Infertility. In Current Obstetrics and Oynaecology Diagnosis and Treatment: 10<sup>th</sup> ed. New York: McGiaw Hill. 2007;917-25.

3. Dutta DC. Infertility. In Textbook of Gynaecology. 5<sup>th</sup> ed Calcutta: New central book agency (P) Ltd. 2008;220-49.
4. Jeffcoate N. Infertility and assisted reproduction technology. In: Jeffcoate's Principles of Gynaecology. 7<sup>th</sup> ed. London: Amold. 2008;699-730.
5. Sinawat S, Pattamadilok J, Seejorn K. Tubal abnormalities in Thai infertile females. *J Med Assoc Thai.* 2005;88(6):723-7.
6. McClure EM, Goldenberg RL. Infection and stillbirth. *Semin Fetal Neonatal Med.* 2009;14:182-9.
7. Chowdhury S, Chowdhury TA. Laparoscopic assessment of tubal factors in infertility. *Bangladesh J Obstet Gynaecol.* 1992;7(1):9-16.
8. Collet M, Reniers J, Frost E, Gass R, Yvert F, Leclerc A et al. Infertility in Central Africa: infection is the cause. *Int J Gynecol Obstetrics.* 1988;26(3):423-8.
9. Khatun H. Laparoscopic evaluation of pelvic organ. Bangladesh college Physician surgeon. 2003.
10. Nessa M, Chowdhury T, Jahan SC, Begum ND, Sultana SE, Rumman UF et al. Laparoscopic evaluation of pelvic organ in case of infertility. Bangladesh college of Physician and surgeon. 2003;3(2):90-5.
11. Miligos S, Protopapas A, Kallipoltis G, Drakakis P, Makrigianna KIS, Llaki A et al. Laparoscopic evaluation infertile patients with chronic pelvic pain. *Reprod Biomed Onimc.* 2006;12(3):347-53.

**Cite this article as:** Ahmed P, Chowdhury TA, Mahmud K. Laparoscopic evaluation of pelvic organ in case of subfertility. *Int J Reprod Contracept Obstet Gynecol* 2021;10:2955-60.