

DOI: <https://dx.doi.org/10.18203/2320-1770.ijrcog20215077>

Original Research Article

## Histopathological evaluation of endometrial tissue in patients of abnormal uterine bleeding

Zothansangi<sup>1</sup>, Vanremmawii<sup>2\*</sup>, Naveen P.<sup>3</sup>

<sup>1</sup>Department of Pathology, Zoram Medical College, Falkawn, Aizawl, Mizoram, India

<sup>2</sup>Department of Obstetrics and Gynaecology, Zoram Medical College, Falkawn, Aizawl, Mizoram, India

<sup>3</sup>Department of Physiology, All India Institute of Medical Sciences, Guwahati, Assam, India

**Received:** 15 December 2021

**Revised:** 17 December 2021

**Accepted:** 30 December 2021

**\*Correspondence:**

Dr. Vanremmawii,

E-mail: [drmamawii@gmail.com](mailto:drmamawii@gmail.com)

**Copyright:** © the author(s), publisher and licensee Medip Academy. This is an open-access article distributed under the terms of the Creative Commons Attribution Non-Commercial License, which permits unrestricted non-commercial use, distribution, and reproduction in any medium, provided the original work is properly cited.

### ABSTRACT

**Background:** Abnormal uterine bleeding (AUB) is one of the commonest complaints in the gynecology OPD. It is also one of the most common reason for hysterectomy among Mizo women. Endometrial biopsy is a gold standard and first step for diagnosis of AUB in a low resource setting like the North-east states of India. The aim of the study was to evaluate the histopathology of endometrium for proper management of AUB cases.

**Methods:** This was a prospective study done to evaluate the histopathology of all the cases of AUB who attended gynaecology OPD, from the year 2018 to 2020. This study comprised of 668 AUB cases and material of the study was endometrial tissue of the cases of Abnormal uterine bleeding collected by dilatation and curettage, and sent for histopathological study to the department of pathology.

**Results:** Most of the abnormal uterine bleeding patients was in the age group of 40 to 49 years, and the most common histopathological finding was proliferative endometrium, 35.5% followed by disordered proliferation, 21%. 14 cases of carcinoma endometrium were found among the age group above 40 years.

**Conclusions:** The research evident that all the women above 40 years old need to undergo screening, keeping in mind the higher risk of carcinoma in the older age group of women.

**Keywords:** Abnormal uterine bleeding, Histopathology, Endometrial hyperplasia, Carcinoma

### INTRODUCTION

Abnormal uterine bleeding (AUB) constitutes almost 40% of gynecology OPD attendance among the Mizo women.

This menstrual disorder affects women from puberty till post-menopausal. AUB is defined as changes in the frequency of menstruation, duration of flow, amount of blood flow or intermenstrual bleeding.<sup>1</sup>

The cause of abnormal uterine bleeding differs in different age groups as well as endometrial response to hormones and their variations and other structural lesions. AUB interferes significantly with the quality of life among women.<sup>2</sup>

The FIGO working group on menstrual disorders has classified the various causes for AUB into structural and non-structural entities.<sup>3</sup> Common structural causes include fibroids, polyps, endometrial hyperplasia, endometrial carcinoma and complications of pregnancy. Endometrial sampling and subsequent histopathological examination remain the gold standard for diagnoses of the causes of AUB.<sup>4</sup>

It is estimated that 9-30% of women of reproductive age suffer from an abnormal uterine bleeding. The prevalence increases with age, peaking just prior to menopause.<sup>5</sup>

This is the first study of this kind on the women of Mizoram, a small state in the remote North East India.

**Aim**

The aim of the study were (a) to understand Histopathological examination (HPE) of endometrial tissue in abnormal uterine bleeding patients; and (b) to compare HPE findings in AUB of different age group.

**METHODS**

This was a prospective study on histopathology of endometrium in patients presenting with AUB, undertaken in the department of obstetrics and gynecology and department of pathology of Zoram Medical College, Falkawn, Mizoram after approval from the Institutional Ethical Committee. Total duration of study was 3 years from the year 2018 to 2020.

Material of the study was endometrial tissue of the 668 cases of AUB collected by dilatation and curettage, and sent for histopathological study to the department of pathology. The endometrial tissue was fixed in 10% formalin and the entire tissue was taken for routine processing. And then 3-4 µm thickness sections from paraffin blocks were stained with Hematoxylin and eosin (H and E) and studied microscopically. Microscopic examination was done by a team of pathologist and a second opinion was taken to reduce observer’s bias.

**Inclusion criteria**

Endometrial tissue from all age groups with a clinical diagnosis of AUB.

**Exclusion criteria**

Patients presenting with AUB due to genital tract infections, systemic causes and other lesions.

The data was expressed as frequency and percentages using Microsoft excel. Microsoft word was used to generate tables.

**RESULTS**

Table 1 show age wise distribution. the present study comprised of 668 cases of endometrial biopsy. Age of the patients with AUB ranges from 18 to 79 years, with a mean of 43.7 years. Highest incidence of AUB was found in the age group of 40 to 49 years.

Table 2 show histopathology findings of the endometrial biopsy, maximum case was proliferative endometrium (35.47%) was the maximum case followed by disordered proliferation (21%) Others which include pregnancy complications and squamous cell carcinoma comprises of 5.7% of the cases. The most common finding was normal cyclical pattern endometrium, showing proliferative endometrium in 35.5% and secretory endometrium in 11.07% of our cases.

In women under 40 years of age, the most common finding was proliferative endometrium followed by disordered proliferative endometrium and secretory endometrium. A total of 140 cases (21%) showed disordered proliferation pattern which was most common between the age group 40 to 49 years and 30 to 39 years of age.

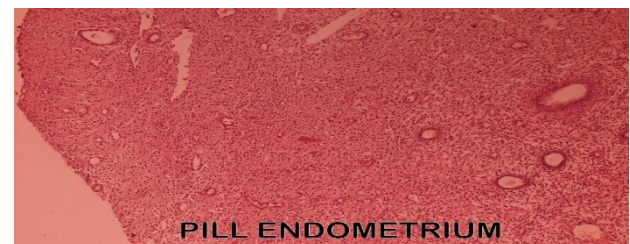
Atrophic endometrium was seen in 58 patients mostly of post-menopausal age group, but some women in the age group of 40 to 49 show atrophic endometrium. Carcinoma endometrium was seen in 14 cases out of which 71% are above the age group of 50. But carcinoma endometrium was found in one patient of 35 years, who had a history of ovulation and diabetes mellitus type 2. Incidence of endometrial hyperplasia in our study was 8.68% and endometrial carcinoma was 2.09%. The incidence of endometrial hyperplasia and endometrial carcinoma was highest after the 4th decade of life suggesting that the incidence of endometrial hyperplasia and endometrial carcinoma increases with age.

**Table 1: Age wise distribution of cases.**

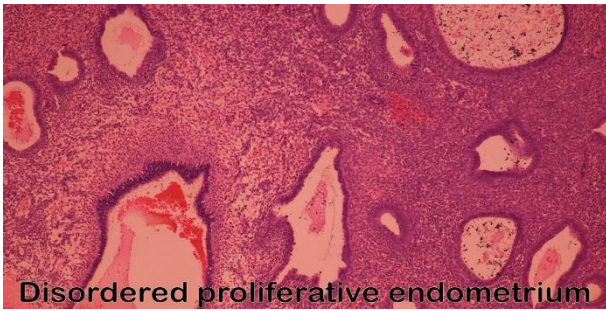
Age groups (years)	N	%
Less than 20	2	0.30
20-29	39	5.83
30-39	150	22.45
40-49	289	43.26
50-59	171	25.59
60-69	13	1.96
70-79	04	0.59

**Table 2: Histopathological picture of the endometrium.**

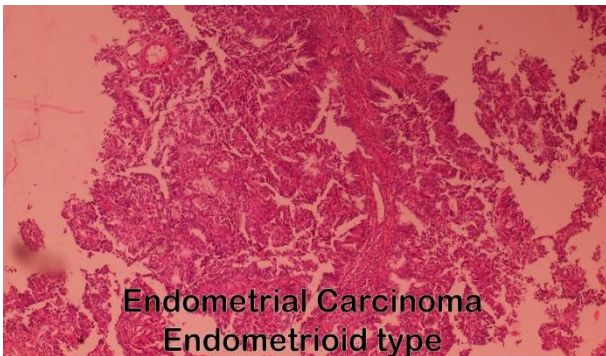
Endometrium pattern	N	%
Proliferative endometrium	237	35.47
Secretory endometrium	74	11.09
Pill endometrium	31	4.64
Atrophic endometrium	58	8.68
Endometritis	5	0.75
Endometrial polyp	9	1.35
Simple cystic hyperplasia	43	6.45
Adenomatous hyperplasia	6	0.90
Disordered proliferation	140	21
Complex hyperplasia without atypia	4	0.60
Complex hyperplasia with atypia	9	1.35
Endometrial carcinoma	14	2.01
Others	38	5.70



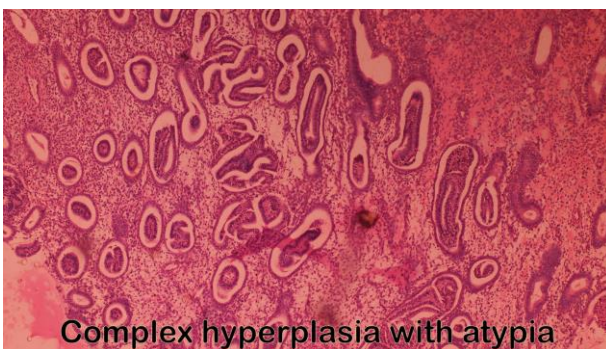
**Figure 1: Pill endometrium.**



**Figure 2: Disordered proliferative endometrium.**



**Figure 3: Endometrial carcinoma endometrial type.**



**Figure 4: Complex hyperplasia with atypia.**

## DISCUSSION

AUB is due to varied causes, physiological, pathological or pharmacological and it leads to considerable social and physical morbidities. The evaluation of AUB requires adequate history physical examination and laboratory investigations including imaging and endometrial sampling.<sup>1,6</sup>

The routine noninvasive investigations for abnormal uterine bleeding include complete blood count, platelet count, Prothrombin time (PT), Activated partial thromboplastin time (APTT) and Liver function test. In women of reproductive age, pregnancy has to be ruled out and endocrine disorder has to be ruled out by Thyroid function test, Luteinizing hormone (LH), Follicle stimulating hormone (FSH) and prolactin estimation. After ruling out these causes, Trans vaginal sonography

and tissue samplings is done. Dilatation and curettage can be both diagnostic and therapeutic procedure.<sup>1</sup>

The most likely etiology of AUB is closely related to the patient's age group whether the patient is pre-menopausal, peri-menopausal or postmenopausal.<sup>7</sup> The youngest patient in our study was 18 years of age and the oldest was 79 years.

Newborn girl may also have spotting per vagina within a few days of life because of withdrawal of high level of maternal estrogen, which had stimulated the endometrium.

The adolescent age group (<20) accounted for 0.3% of our cases and the endometrial HPE showed proliferative endometrium in all the cases, similar to Doraiswami et al who found normal cyclical menstrual pattern in adolescent group which comprised of 1.5% of their cases.<sup>9</sup>

The mean age of the patients with AUB in this study was 43.7 years and most of the patients belong to reproductive age (72%) followed by perimenopausal age group and then post-menopausal age group, out of which 2.5% of the cases were above 60 years of age.

In this study normal cyclical menstrual pattern was seen in 46.6% cases out of which 35.5% was of proliferative type endometrium and the rest 11.07% was secretory endometrium.

Disordered proliferation was seen in 21 % of our study and 54% of the disordered proliferative cases were in the age group of 40-49 years. Disordered proliferation is common in perimenopausal age because of anovulatory cycle.<sup>6,8</sup>

Endometrial hyperplasia was seen in 9.3% of the cases, majority of them in the age group of 30-50 years. Endometrial hyperplasia is important because it is known to be a precursor to endometrial carcinoma.<sup>9</sup>

Endometrial polyp was seen in 9 cases (1.35%), atrophic endometrium in seen in 58 (8.7%) cases, all in the age group of 40 and above, pill endometrium in 31 (4.6%) cases, endometrial carcinoma in 14 (2.1 %) cases.

The bleeding in proliferative endometrium maybe due to anovulatory cycle and bleeding in secretory endometrium is due to ovulatory dysfunctional uterine bleeding.<sup>9</sup> Endometrial study helps to differentiate ovulatory and anovulatory DUB. Anovulatory DUB is caused by a disturbed function of hypothalamo-pituitary-ovarian axis most commonly seen in polycystic ovarian disease, and at peri menarchal and peri menopausal years. During these periods, menstrual cycle is intermittently ovulatory and anovulatory resulting in variable blood loss.<sup>10,11</sup> It is observed that unopposed estrogen causes increased blood loss by various mechanism.<sup>10</sup> Without sufficient progesterone to stabilize the endometrium, the mucous membrane become fragile and sloughs irregularly.

In ovulatory abnormal bleeding, the main defect seems to be in the control of process regulating the volume of menstrual blood loss, primarily decreased endometrial vasoconstriction and vascular hemostatic plug formation.<sup>10</sup>

Vaydia et al in their study reported 40.94% cases of normal endometrium, 13.40% cases of disordered proliferative endometrium, 10.92% cases endometrial hyperplasia and 2.88% cases of endometrial cancer.<sup>12</sup> Dwivedi et al also found in their study normal menstrual pattern in 48.15% of cases, hormonal and pill effects in 22.22% of cases, endometrial hyperplasia in 3.70% of cases, endometrial cancer in 1.85%.<sup>13</sup>

Another study done in Pakistan by Mirza et al examined endometrial tissue of 1000 cases of AUB and reported normal cyclical pattern in 35.06%, disordered proliferation in 22.80%, 30% endometrial hyperplasia and 2% endometrial carcinoma and 7% atrophic endometrium.<sup>14</sup>

Doraiswami et al in a study of 409 cases of AUB noted normal cyclical endometrium in 28.36%, disordered proliferation in 20.54%, most commonly in the age group of 41-50 years of age, pregnancy complication in 22.74% cases and endometrial hyperplasia in 6.11%.<sup>9</sup>

Sreedar et al studied 150 cases of AUB, and reported the mean age of the patients to be 49.5 years. The commonest incidence was in the age group of 40-49 years. The commonest pathology was proliferative endometrium (29.3%), followed by secretory endometrium (14%). The rest were endometrial polyp (9.3%), atrophic endometrium (4%), endometrial carcinoma (6%), pill endometrium (5.3%), and endometrial hyperplasia (17.4%).<sup>5</sup> Vani et al did a study of 231 endometrial biopsy, and found proliferative endometrium in 30.3%, secretory endometrium in 25.97%, disordered proliferation in 5.62%, endometrial polyp in 2.16%, endometrial hyperplasia in 20.09%, pill endometrium in 2.0%, and endometrial cancer in 0.86%.<sup>15</sup>

### Limitations

The limitation of this study was the inability to compare the specific clinical presentation of AUB (menorrhagia, polymenorrhea, metrorrhagia, post-menopausal bleeding, etc.) with a particular histopathological finding.

### CONCLUSION

AUB at any age can be alarming, and the causes of abnormal uterine bleeding has specified age predilection. Endometrial biopsy and histopathological evaluation are valuable in early detection of precancerous endometrial lesion as well as malignancy. This study showed a high percentage of endometrial cancer in postmenopausal age group with AUB and endometrial hyperplasia in the perimenopausal age group. Therefore, it is essential to accurately interpret endometrial patterns in

any age group for correct diagnoses and management of AUB in all the age group of women.

*Funding: No funding sources*

*Conflict of interest: None declared*

*Ethical approval: The study was approved by the Institutional Ethics Committee*

### REFERENCES

1. Albers JR, Hull SK, Wesley RM. Abnormal uterine bleeding. *Am Fam Physician.* 2004;69(8):1915-26.
2. ESHRE Capri Workshop Group, Collins J, Crosignani PG. Endometrial bleeding. *Hum Reprod Update.* 2007;13(5):421-31.
3. Munro MG, Critchley HO, Broder MS, Fraser IS, FIGO Working Group on Menstrual Disorders. FIGO classification system (PALM-COEIN) for causes of abnormal uterine bleeding in nongravid women of reproductive age. *Int J Gynaecol Obstet.* 2011;113(1):3-13.
4. Khan R, Sherwani RK, Rana S, Hakim S, Jairajpuri Z. Clinico-Pathological Patterns in Women with Dysfunctional Uterine Bleeding. *Iran J Pathol.* 2016;11(1):20-6.
5. Sreedhar VV, Jyothi Ch, Rao MN, Saijala V, Charan Paul MNP, Lakshmi GV. Study of Histopathological Pattern of Endometrium in abnormal uterine Bleeding-A study of 150 cases-A study of 150 cases. *Saudi J Pathol Microbiol.* 2017;2(4):137-42.
6. McCluggage WG. My approach to the interpretation of endometrial biopsies and curettings. *J Clin Pathol.* 2006;59(8):801-12.
7. Dahlenbug-Hellweg G. *Histopathology of endometrium.* New York, NY: Springer-verlag; 1993.
8. Sajitha K, Padma SK, Shetty KJ, Kishan HL, Perni HS, Hedge P. Study of histological patterns of endometrium in abnormal uterine bleeding. *CHRISMEDL Health Res.* 2014;1(2):76-81.
9. Doraiswami S, Johnson T, Rao S, Rajkumar A, Vijayaraghavan J, Panicker VK. Study of endometrial pathology in abnormal uterine bleeding. *J Obstet Gynaecol India.* 2011;61(4):426-30.
10. Livingstone M, Fraser IS. Mechanisms of abnormal uterine bleeding. *Hum Reprod Update.* 2002;8(1):60-7.
11. Devi LS. Singh MR, Singh LR, Debnath K. The histological and histochemical study of endometrium in Dysfunctional uterine bleeding. *J Med Soc.* 2012;26(3):167-70.
12. Vaidya S, Lakhey M, Vaidya S, Sharma PK, Hirachand S, Lama S. Histopathological pattern of abnormal uterine bleeding in endometrial biopsies. *Nepal Med Coll J.* 2013;15(1):74-7.
13. Smriti S, Dwivedi, Bajpai M, Bushan I, Satkiri A. Spectrum of endometrial lesion observed on HPE of endometrial samples in women with abnormal uterine bleeding. *Int J Res Med Sci.* 2019;7(11):4124-8.

14. Mirza T, Akram S, Mirza A, Aziz S, Mirza T, Mustansar T. Histopathological pattern of abnormal bleeding in endometrial biopsies. *J Basic applied Sci.* 2012;8(1):114-7.
15. Vani BS, Vani R, Jijiya BP. Histopathological evaluation of endometrial biopsies and curetting's in

abnormal uterine bleeding. *Tropical J Pathol Microbiol.* 2019;5(4):190-7.

**Cite this article as:** Zothansangi, Vanremmawii, Naveen P. Histopathological evaluation of endometrial tissue in patients of abnormal uterine bleeding. *Int J Reprod Contracept Obstet Gynecol* 2022;11:69-73.