

DOI: 10.5455/2320-1770.ijrcog20140951

Case Report

An interesting case of pseudoaneurysm of internal iliac artery: rare case report with review of literature

Rajshree D. Katke^{1*}, Ashish N. Zarariya¹, Avinash A. Gutte²

¹Department of Obstetrics & Gynaecology, Cama & Albless Hospital, Grant Govt. Medical College, Mumbai, Maharashtra, India

²Department of Radiology, Grant Govt. Medical College, Mumbai, Maharashtra, India

Received: 10 July 2014

Accepted: 20 July 2014

***Correspondence:**

Dr. Rajshree D. Katke,

E-mail: drrajshreekatke@yahoo.com

© 2014 Katke RD et al. This is an open-access article distributed under the terms of the Creative Commons Attribution Non-Commercial License, which permits unrestricted non-commercial use, distribution, and reproduction in any medium, provided the original work is properly cited.

ABSTRACT

Pseudoaneurysm is known to be a rare cause of secondary postpartum haemorrhage. A pseudoaneurysm is a haematoma that communicates with the lumen of a damaged parent artery via a small neck leading to turbulent flow. Herein we report a case of 32 year old multiparous patient who developed heavy vaginal bleeding 3 months post uterine curettage and was suspected to have AV malformation. Further evaluation on MRI & angiography showed small sized vaginal wall AV malformation with large pseudoaneurysm arising from within it. Its location near retropubic space in vagina, a very difficult site to approach makes this case interesting. She was treated with total abdominal hysterectomy with bilateral internal artery looping with excision of the pseudoaneurysm with successful outcome.

Keywords: Iliac artery pseudoaneurysm, AV malformation

INTRODUCTION

The development of an arterial pseudoaneurysm is a rare reported complication of uterine curettage, pelvic surgery, and vascular injury during caesarean section. The differential diagnosis of pseudoaneurysm includes acquired arteriovenous malformations (AVMs), true aneurysms, arteriovenous fistulas, and direct vessel rupture. The absence of a 3-layer arterial wall lining differentiates the pseudoaneurysm from a true aneurysm.¹ Pseudoaneurysm presents as haemorrhage, rupture, thrombosis, distal painful emboli's or may be asymptomatic.^{2,3} Diagnosis is usually confirmed by angiography.⁴

CASE REPORT

A 32 year old gravida 3, para 2, abortion 1 admitted on 30/4/14 with acute episode of heavy vaginal bleeding. 3

months back, [4/2/14]. Patient underwent check curettage with two units of pre-operative blood transfusions for spontaneous 8 weeks incomplete abortion, after admission, beta-HCG and USG were suggestive of retained products of conception with multiple cystic spaces in anterior wall of uterus showing increased vascularity. Patient managed conservatively with antibiotics, inj. tranexamic acid and 3 units of blood transfusions. After 15 days B-HCG levels comes down to <5 miu/ml from 1115 miu/ml (on admission). Pt had intermittent mild bleeding during its course in the hospital.

On further evaluation, magnetic resonance imaging pelvis done. It showed two well defined lesions one in the anterior wall and fundus of uterus and another in anterior vaginal wall with multiple dilated tortuous vascular channels within filling in arterial phase and early opacification of bilateral internal iliac veins. Findings

suggestive of vascular malformation like arteriovenous malformation rather than gestational trophoblastic disease or retained products of conception.

Bilateral internal iliac angiogram done, showed E/O very slow flow. Small AVM in region of pubic symphysis i.e. in vaginal wall with large pseudoaneurysm within it. In correlation with MRI and angiography, diagnosis made as small sized vaginal wall AV malformation with large pseudoaneurysm arising from within it.

Pt was operated and total abdominal hysterectomy with B/L internal iliac artery looping with excision of pseudoaneurysm. Pt required 5 units blood transfusions (2-intra-op, 3-post-op). Post-op patient was uneventful.

HPR report was S/O endometrium-proliferative type with blood clot, myometrium-unremarkable, cervix-chronic papillary endocervicitis with squamous metaplasia. No evidence of dysplasia/malignancy. Cyst wall with fibromuscular stroma suggestive of thin and thick walled vessels with areas of haemorrhage, possibility of pseudoaneurysm.

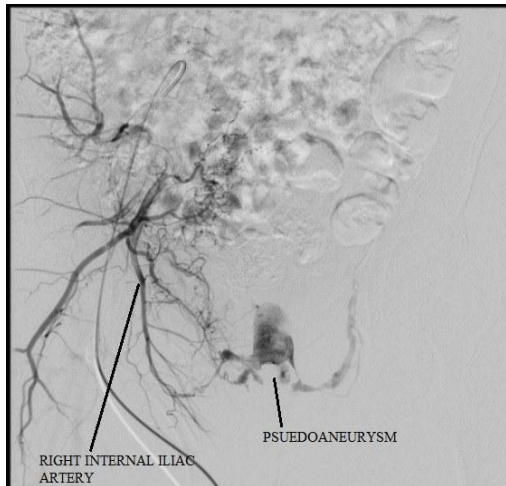


Figure 1: Digital subtraction angiography image of right internal iliac artery showing pseudoaneurysm.

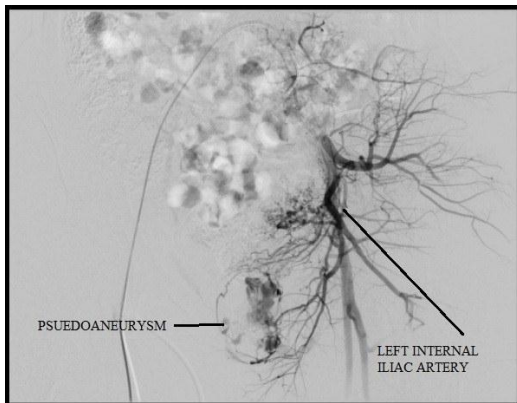


Figure 2: Digital subtraction angiography image of left internal iliac artery showing pseudoaneurysm.

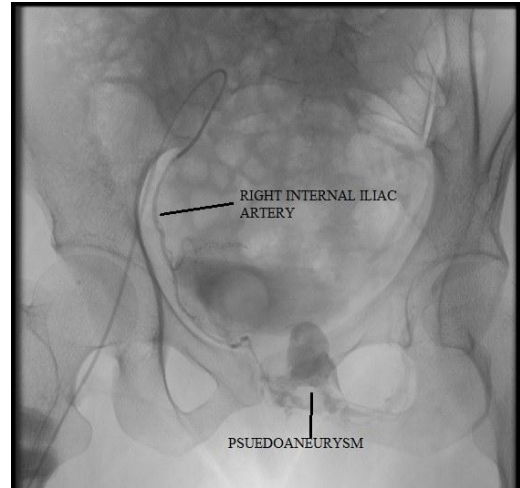


Figure 3: Digital subtraction angiography image of right internal iliac artery showing pseudoaneurysm.

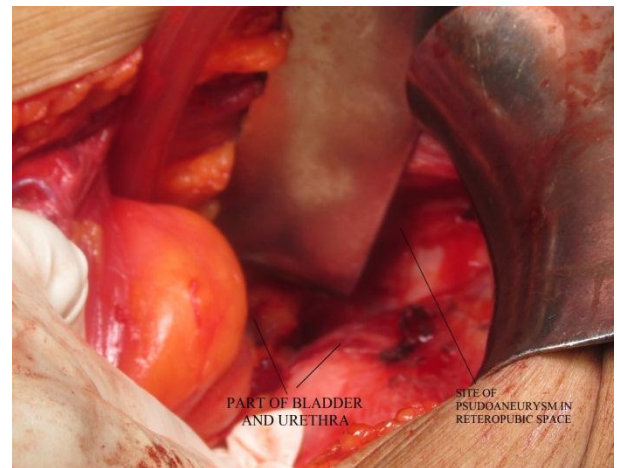


Figure 4: Intraoperative image showing location of pseudoaneurysm.

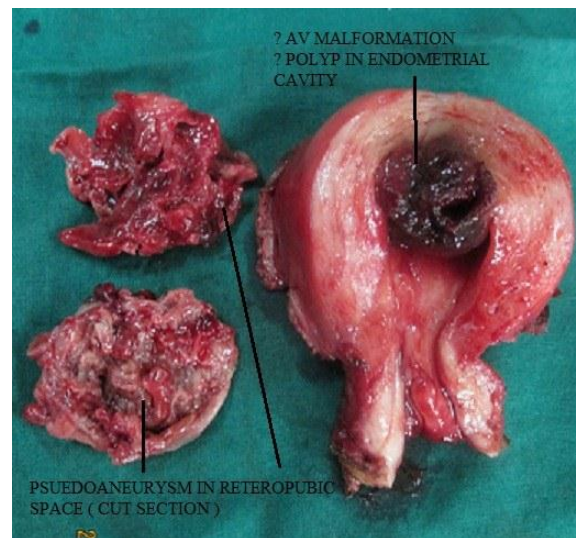


Figure 5: Cut section of hysterectomy specimen showing AV malformation inside uterus with cut section of pseudoaneurysm.

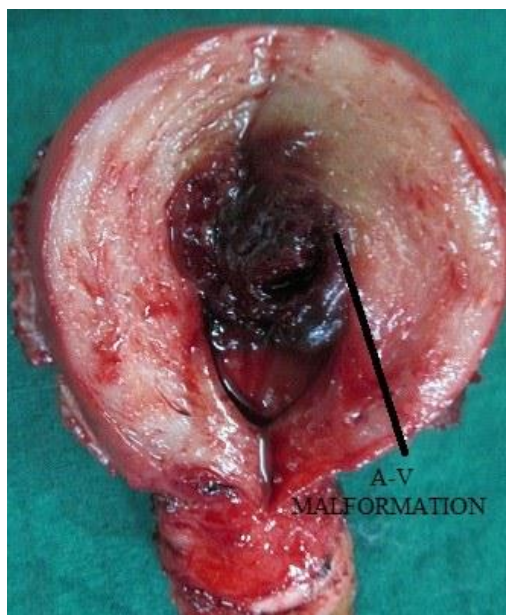


Figure 6: Cut section of hysterectomy specimen showing AV malformation.

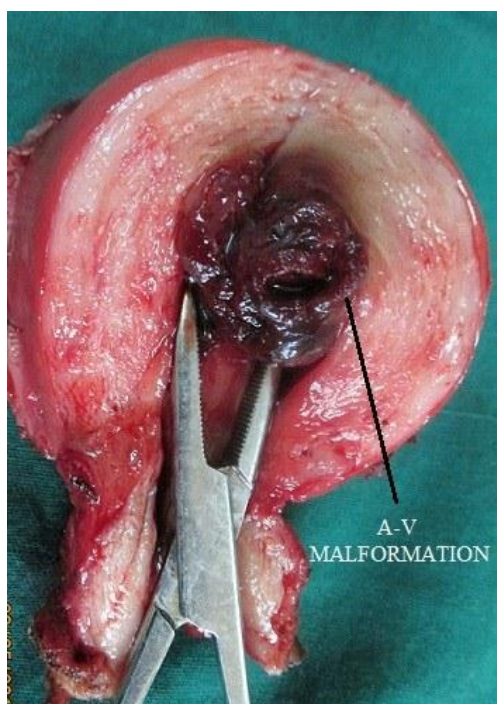


Figure 7: Cut section of hysterectomy specimen showing AV malformation.

DISCUSSION

Our patient had an acquired AV malformation with pseudoaneurysm within it. It was located in the retroperic space more on the left side displacing the urethra to the right. It was approximately 6 x 4 cm size and non-pulsatile, protruding through anterior wall of vagina. It can be easily mistaken as vaginal wall cyst on examination. Traditionally, AV malformation with

pseudoaneurysm is treated with Coil embolization.⁵ So in our case option of embolization versus open surgery discussed with interventional radiologist, vascular surgeon and of course patient and her relatives. Because of heavy bleeding requiring 5 blood transfusions, patient completing her family, and most importantly, location of pseudoaneurysm had made us decide to take decision of hysterectomy with bilateral internal iliac looping followed by excision of the pseudoaneurysm.

CONCLUSION

Pseudoaneurysm in internal iliac artery is very rare.⁶ Few cases of pseudoaneurysm of uterine artery are reported.^{5,7,8} MRI helps in accurately delineating the borders and Angiography is gold standard in diagnosis. If not diagnosed timely, consequences are catastrophic. Uterine artery embolization is effective alternative to surgical therapy but in our case the size of pseudoaneurysm was bigger and the patient was bleeding continuously, so after consulting the interventional radiologist, we have opted the way of surgical therapy after explaining the all options and consequences to her. In a young age, in a case of pseudoaneurysm AV malformation, first choice is of conservative management.

Funding: No funding sources

Conflict of interest: None declared

Ethical approval: Not required

REFERENCES

1. Kwon JH, Kim GS. Obstetric iatrogenic arterial injuries of the uterus: diagnosis with US and treatment with transcatheter arterial embolization. *Radiographics*. 2002;221:35-46.
2. Langer JE, Cope C. Ultrasonographic diagnosis of uterine artery pseudoaneurysm after hysterectomy. *J Ultrasound Med*. 1999;18:711-4.
3. Rajshree D, Katke, Shilpa Domkundwar, Sunil C. Rathod. Uterine AV malformation with haemoperitoneum: case report. *J Case Rep*. 2014;4(1):60-3.
4. Hidar S, Bibi M, Atallah R, Essakly K, Bouzakoura C, Hidar M. Pseudoaneurysm of the uterine artery: apropos of 1 case. *J Gynaecol Obstet Biol Reprod (Paris)*. 2000;29:621-4.
5. Pramy Nanjundan, M. Rohilla. Pseudoaneurysm of uterine artery: a rare cause of secondary postpartum hemorrhage, managed with uterine artery embolization: case report. *J Clin Imaging Sci*. 2011;1:14.
6. Arthur TI, Gillespie CJ, Butcher W, Lu CT. Pseudoaneurysm of internal iliac artery resulting in massive per rectal bleeding. *J Surg Case Rep*. 2013 Oct 4;2013(10). pii: rjt069.
7. Ankur M. Sharma, Brent E. Burbridge. Uterine artery pseudoaneurysm in the setting of delayed postpartum hemorrhage: successful treatment with

emergency arterial embolization. *Case Rep Radiol.* 2011;2011:373482.

8. Brian C. Cooper, Michelle Hocking-Brown. Pseudoaneurysm of the uterine artery requiring

bilateral uterine artery embolization. *J Perinatol.* 2004;24:560-2.

DOI: 10.5455/2320-1770.ijrcog20140951

Cite this article as: Katke RD, Zarariya AN, Gutte AA. An interesting case of pseudoaneurysm of internal iliac artery: rare case report with review of literature. *Int J Reprod Contracept Obstet Gynecol* 2014;3:820-3.