

DOI: <https://dx.doi.org/10.18203/2320-1770.ijrcog20231244>

Case Report

Case of peritoneal tuberculosis in third trimester of pregnancy

Shaifali Patil, Soumya Jhawar*

Department of Obstetrics and Gynecology, MGM Medical College, Navi Mumbai, Maharashtra, India

Received: 16 January 2023

Revised: 18 February 2023

Accepted: 20 February 2023

*Correspondence:

Dr. Soumya Jhawar,

E-mail: soumyamj95@gmail.com

Copyright: © the author(s), publisher and licensee Medip Academy. This is an open-access article distributed under the terms of the Creative Commons Attribution Non-Commercial License, which permits unrestricted non-commercial use, distribution, and reproduction in any medium, provided the original work is properly cited.

ABSTRACT

Tuberculous peritonitis is one of the least common forms of extrapulmonary tuberculosis. Tuberculous peritonitis in pregnancy is a diagnostic challenge, especially in the absence of lung involvement. We report a case of peritoneal tuberculosis in a 32-Year-old female, a G2A1 with 30 weeks' gestation came with chief complaint of profuse clear discharge from the umbilicus. USG abdomen and pelvis was suggestive of 1 cm sized wide hypoechoic track in the umbilical region likely communicating with anterior uterine wall, while MRI Fistulogram was suggestive of Oedematous sinus tract in the cutaneous and subcutaneous plane of the periumbilical anterior abdominal wall with no obvious extension beyond the rectus sheath. Anti-tubercular treatment was started for the patient immediately upon diagnosis. The flow of clear discharge ceased within 2 days and the symptoms resolved in 2 weeks. This case is being presented for the rarity of its occurrence specifically in pregnancy.

Keywords: Peritoneal tuberculosis, Pregnancy, Third trimester

INTRODUCTION

Tuberculous peritonitis is one of the least common forms of extrapulmonary tuberculosis. Tuberculous peritonitis in pregnancy is a diagnostic challenge, especially in the absence of lung involvement.¹ The clinical presentations of tuberculous peritonitis are usually non-specific and mimic those of other diseases, such as ovarian malignancy or chronic liver disease, and physiological presentation of pregnancy, this non-specificity can cause diagnostic delays and complications.² It is estimated that the incidence of peritoneal tuberculosis among all forms of tuberculosis varies from 0.1% to 0.7% worldwide.³ Peritoneal tuberculosis (PT) in pregnancy is uncommon because infertility is the commonest sign if tuberculosis involves the genitals and/or peritoneum. The presence of adenosine deaminase activity in ascitic tapping is a discriminating test in the diagnosis of Peritoneal TB with levels above 39 U/L set as cut off.⁴ All 4 first line drugs [isoniazid, rifampicin (rifampin), ethambutol and

pyrazinamide] have an excellent safety record in pregnancy and are not associated with human foetal malformations.¹⁵

CASE REPORT

32-year-old female, Mrs. XYZ, a G2A1 with 30 weeks gestation came with chief complaint of profuse clear discharge from the umbilicus since 1 day (Figure 1). The discharge was profuse, clear coloured, non-foul smelling, not associated with any itching or rash. Patient gave history of loss of appetite and weight loss since the past few 2 weeks with no history of pain in abdomen, fever, cough or Tb contact

On examination, patient was conscious, cooperative and well oriented. She was tachycardiac with a pulse of 120/min and on per abdominal inspection, abdomen was distended due to gravid uterus, umbilicus inverted with clear serous fluid seen flowing from umbilicus which was

non foul smelling in nature, striae gravidarum and linea nigra noted, no scars or dilated veins were present, fundal height of the uterus was corresponding to 32 weeks of gestation.

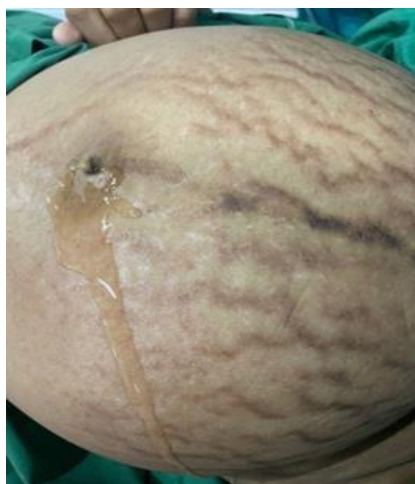


Figure 1: Clear fluid discharge from umbilicus.

Ascitic fluid cytology was suggestive of tubercular aetiology with protein: 4.54 mg/dl (raised) adenosine deaminase: 41 U/l (raised), BACTEC culture: sterile, Mantoux Test: positive

USG OBS was within normal limits with single live intrauterine pregnancy of 30.4 weeks gestation with normal liquor (AFI: 12 cm).

Urgent USG abdomen and pelvis was done suggestive of 1 cm sized wide hypoechoic track in the umbilical region possibly communicating with anterior uterine wall, hypoechoic fluid with echoes seen within the track. Focal wall oedema in anterior uterine wall at site of communication.

MRI fistulogram was suggestive of oedematous sinus tract in the cutaneous and subcutaneous plane of the periumbilical anterior abdominal wall with no obvious extension beyond the rectus sheath into serosal margin of uterus. Moderate ascites with congestive and inflammatory changes in peritoneal cavity (peritonitis) and necrotic retroperitoneal lymph nodes suggestive of infective aetiology (? tuberculous).

Anti-tubercular treatment (1st line drugs) was started for the patient immediately upon diagnosis. The flow of clear discharge ceased within 2 days and the symptoms resolved in 2 weeks. Patient's pregnancy progressed to term gestation and she delivered a healthy male baby of 3.2 kg via caesarean section done in view of non-progression of labour. Intraoperatively, no gross signs of genital tuberculosis noted. The patient was discharged and continued on anti-tubercular treatment.

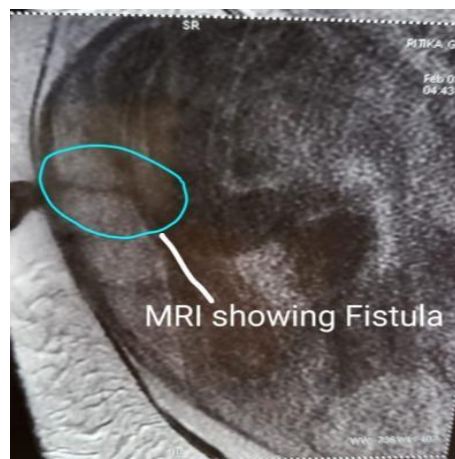


Figure 2: MRI s/o Fistula.

DISCUSSION

Untreated tuberculosis (TB) represents a greater hazard to a pregnant woman and her foetus than does its treatment. Treatment of pregnant women should be initiated whenever the probability of TB is moderate to high. Peritoneal tuberculosis should be suspected in ascites during pregnancy. Infants born to women with untreated TB tend to have lower birth weight, fetal growth restriction.⁶ Although the drugs used in the initial treatment regimen for TB cross the placenta, they do not appear to have harmful effects on the foetus. Early detection and timely intervention can prevent adverse sequelae of TB.

CONCLUSION

To conclude, the benefits that come with the treatment of tuberculosis in pregnancy far outweigh the risks associated with the anti-tuberculous drugs. Early diagnosis and treatment in pregnancy will leave to an improved maternal and neonatal morbidity and mortality.

Funding: No funding sources

Conflict of interest: None declared

Ethical approval: Not required

REFERENCES

1. Lahbabi M, Brini J, Massaoudi K. Tuberculous peritonitis in pregnancy: a case report. J Med Case Rep. 2014;8:3.
2. Jung S, Yun NR, Kim JO, Lee JH, Kim HY, Song E, et al. Tuberculous peritonitis in the first trimester of pregnancy. Obstet Gynecol Sci. 2017;60(2):218-22.
3. Lahbabi M, Brini J, Massaoudi K. Tuberculous peritonitis in pregnancy: a case report. J Med Case Rep. 2014;8:3.
4. Arnoldo R, Mario C, Felipe S, Sebastián V, Alejandro P, Marco A, et al. Value of Adenosine Deaminase (ADA) in Ascitic Fluid for the Diagnosis of

Tuberculous Peritonitis: A Meta-analysis. *J Clin Gastroenterol.* 2006;40(8):705-10.

5. Bothamley G. Drug treatment for tuberculosis during pregnancy: safety considerations. *Drug Saf.* 2001;24(7):553-65.
6. Mittal H, Das S, Faridi MM. Management of newborn infant born to mother suffering from tuberculosis:

current recommendations & gaps in knowledge. *Indian J Med Res.* 2014;140(1):32-9.

Cite this article as: Patil S, Jhavar S. Case of peritoneal tuberculosis in third trimester of pregnancy. *Int J Reprod Contracept Obstet Gynecol* 2023;12:1479-81.