

Vaginal delivery in a patient with asymptomatic severe aortic stenosis: a case report

Kanagavarshani M.*, Amanjot Kaur, Pooja Sikka, Neelam Aggarwal, Seema Chopra

Department of Obstetrics and Gynecology, PGIMER Chandigarh, India

Received: 21 June 2023

Accepted: 07 July 2023

***Correspondence:**

Dr. Kanagavarshani M.,

E-mail: mvarsharan@gmail.com

Copyright: © the author(s), publisher and licensee Medip Academy. This is an open-access article distributed under the terms of the Creative Commons Attribution Non-Commercial License, which permits unrestricted non-commercial use, distribution, and reproduction in any medium, provided the original work is properly cited.

ABSTRACT

Heart disease complicates about 1-4% of all pregnancies of which valvular heart disease is the commonest cause. In developing countries, congenital heart diseases are commonly first detected during pregnancy. Most women do well during pregnancy but severe mitral stenosis or severe aortic stenosis are high-risk conditions that can cause significant morbidity and mortality. Unlike asymptomatic severe mitral stenosis, asymptomatic severe aortic stenosis is mWHO category 3. There is no consensus on the mode of delivery in patients with asymptomatic severe aortic stenosis. Here we describe a case of successful vaginal delivery in a woman with severe aortic stenosis. As the patient was asymptomatic and ejection fraction was preserved, a joint decision for vaginal delivery was taken along with the cardiology team. The patient was induced and delivered with operative vaginal delivery. This case shows that vaginal delivery could be a viable option in patients with asymptomatic severe aortic stenosis given continuous haemodynamic monitoring can be provided.

Keywords: Valvular heart diseases, Ejection fraction, Severe asymptomatic aortic stenosis, Pregnancy, Vaginal delivery, Aortic stenosis

INTRODUCTION

Heart disease complicates about 1-4% of pregnancies of which valvular lesions are most common followed by congenital heart disease.¹ In developing countries, congenital heart diseases are first detected during pregnancy. Aortic stenosis in reproductive-age women is usually secondary to bicuspid aortic valve. Severe aortic stenosis in pregnancy is associated with maternal morbidity and mortality. Asymptomatic aortic stenosis is classified under mWHO class 3 and currently there are no consensus on the mode of delivery in women with asymptomatic severe aortic stenosis.² Case presentation A twenty-six-year-old primigravida was referred to our institute at thirty-six weeks period of gestation in view of changes in electrocardiogram (ECG) as shown in Figure 1.

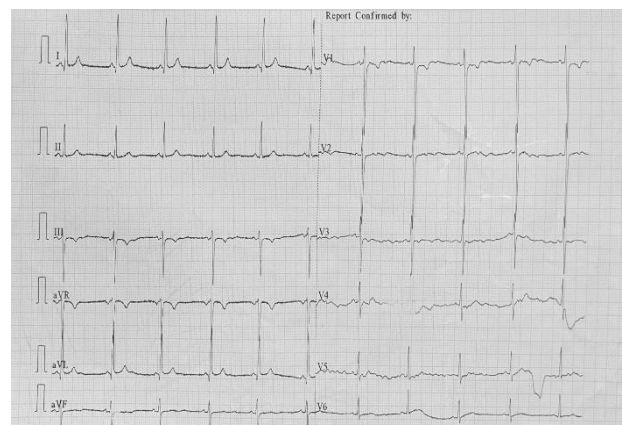


Figure 1: ECG showing left ventricular hypertrophy.

CASE REPORT

The patient never had any complaints of shortness of breath, palpitations or syncopal attacks. She had attended her routine antenatal check-up, when on auscultation a murmur was found as well as an electrocardiogram was advised. On the examination, she was afebrile and blood pressure was 100/70 mmHg. Pulse rate was eighty two per minute as well as regular. jugular venous pressure was not raised. Cardiovascular examination showed a heaving apical impulse at the 5th intercostal space in the midclavicular line, a systolic thrill in the aortic area and on auscultation, a grade four ejection systolic murmur in the aortic area was heard with the radiation to the carotid area. On respiratory examination, bilateral normal vesicular breath sounds were heard. On abdomen examination, the uterus was thirty-two weeks in size, foetal presentation was cephalic and foetal heart sounds were present and were around one hundred and forty per minute. Investigations like complete hemogram, electrocardiogram, chest X-ray as well as the echocardiogram were performed for the patient. The foetal ultrasound was also performed.

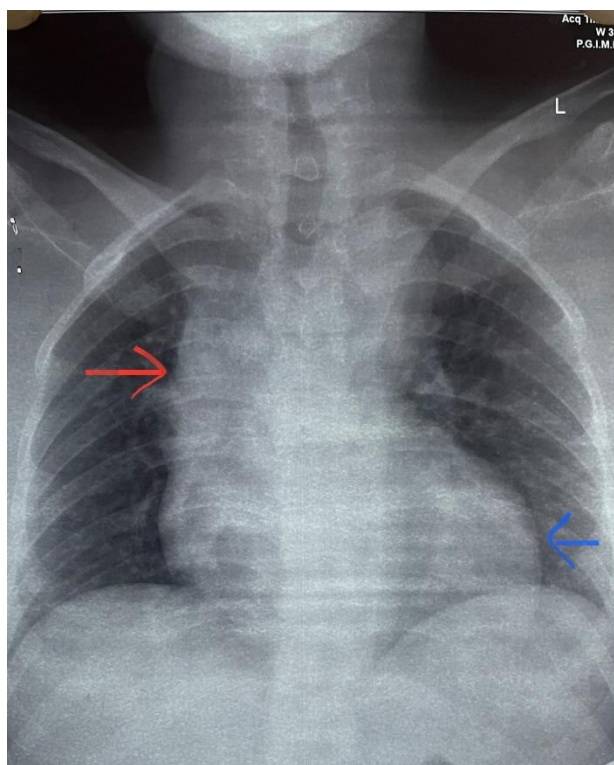


Figure 2: Chest X-ray of the patient showing a dilated ascending aorta (as indicated by red arrow) and enlarged left ventricle (as indicated by blue arrow) which are suggestive of aortic stenosis.

Hemogram was normal. ECG showed normal sinus rhythm with large R waves in V4, V5 and V6 suggestive of left ventricular hypertrophy. Echocardiogram showed severe aortic stenosis and mild aortic regurgitation secondary to the bicuspid aortic valve. The mean pressure

gradient was 39 mm Hg and aortic forward velocity was 4.5 m/s. Aortic annulus area measured 2.2 cm² with an ejection fraction of 60%. Chest X-ray of the patient showed dilated ascending aorta and enlarged left ventricle as shown below in Figure 2. In foetal ultrasound, estimated foetal weight was 1.8 kilogram which is less than the third centile of the expected foetal weight for 36 weeks period of gestation suggesting foetal growth restriction. However, the umbilical artery dopplers were normal and amniotic fluid was adequate.

Since the patient was asymptomatic and had preserved ejection fraction of 60% a decision for vaginal delivery was taken along with the cardiology team. Labour was induced with dinoprostone gel in view of fetal growth restriction at 38 weeks period of gestation and continuous haemodynamic monitoring was done. Adequate intravenous analgesics were administered during active stage of labour. An outlet forceps delivery was conducted to shorten the second stage of labor. A healthy baby boy of 2.4 kilogram was delivered. There were no complications during the postpartum period. Both the baby and mother were discharged on day 3 post-partum. The patient was also counselled for aortic valve replacement during the post-partum period.

DISCUSSION

Valvular heart disease in pregnancy is a significant cause of maternal morbidity in the developing world. The most common cause of valvular lesions in India is rheumatic heart disease (87.3%).³ Though we initially suspected a rheumatic origin due to its high prevalence rate, non-involvement of mitral valve with aortic valve involvement is less likely in rheumatic heart disease. Of the non-rheumatic lesions, a bicuspid aortic valve is the most common cause. Aortic stenosis due to the bicuspid aortic valve occurs in 1-2% of the population.⁴ Bicuspid aortic valves have only two cusps instead of three and are prone to functional abnormality resulting in fibrosis and aortic stenosis. Before symptoms develop most patients with AS (aortic stenosis) are diagnosed when cardiac auscultation reveals a murmur as in our patient or when echocardiography is done for other indications. The American heart association has staged AS from stage A (at risk for AS) to stage B (with progressive haemodynamic obstruction) to stage C (severe asymptomatic) and finally stage D (severe symptomatic).² Women with stage D or symptomatic aortic stenosis should delay pregnancy until after surgical correction. Even the absence of symptoms does not assure that the pregnancy will be uneventful. Severe outflow obstruction limits the ability to increase cardiac output and can cause heart failure and the hypertrophied left ventricle cannot tolerate when there is a fall in preload.⁵ Severe aortic stenosis with reduced ejection fraction is a contra-indication to pregnancy. On the other hand, pregnancy is well tolerated in asymptomatic severe aortic stenosis as long as the patient tolerates exercise testing. Cardiac deterioration is indicated by worsening symptoms, reduction in ejection

fraction or failure to increase transvalvular gradient during pregnancy. Women with significant aortic stenosis need strict antenatal monitoring, for symptoms such as exertional chest pain, light-headedness or syncope that indicate decompensation. Echocardiography and ECG should be performed every 4-6 weeks to ensure that left ventricular function is maintained, that pulmonary arterial hypertension is not developing and that there are no new ischaemic changes. The rise in velocity and Doppler-derived gradient across the stenotic valve as pregnancy progresses is due to the increased stroke volume and is not an abnormal finding. Indeed, a failure of the aortic valve velocity to increase or a fall in velocity indicates that cardiac output is unable to rise and suggests heart failure and imminent decompensation.⁶ During labour, an extra amount of blood returns to the circulation and can cause increased preload and cardiac output. Labour pain can cause tachycardia and decreased duration of diastole leading to reduced coronary perfusion. These changes are poorly tolerated in patients with aortic stenosis. Hence, Caesarean delivery is recommended in patients with symptomatic severe aortic stenosis and those with reduced ejection fraction. In asymptomatic severe aortic stenosis, mode of delivery should be individualized.⁴ In a case report by Drui et al vaginal delivery with epidural analgesia was conducted in a woman with severe aortic stenosis with a valve area of 0.9 cm².⁷ The woman had a history of congenital aortic stenosis for which a bio-prosthetic valve replacement had been done. She was asymptomatic during pregnancy. Cesarean delivery in women with heart disease has not been shown to improve maternal outcomes. In fact, in a study conducted by Ruys et al planned caesarean delivery had higher rates of maternal death, postpartum heart failure and pulmonary thromboembolism.⁸ Foetal outcome was better in the patients who had a planned vaginal delivery. Since our patient was also stage C (asymptomatic severe) with preserved ejection fraction we decided on vaginal delivery. Hence in patients with preserved ejection fraction vaginal delivery is an option in tertiary care centres if continuous haemodynamic monitoring and epidural analgesia are available.

CONCLUSION

Asymptomatic severe aortic stenosis is usually well tolerated in pregnancy. The mode of delivery in these patients should be decided based on the cervical status, foetal status and other risk factors. This case highlights that vaginal delivery could be done in patients with asymptomatic severe aortic stenosis if ejection fraction is preserved and provided continuous haemodynamic monitoring could be done. In this way, the morbidity associated with caesarean delivery could also be avoided.

Funding: No funding sources

Conflict of interest: None declared

Ethical approval: Not required

REFERENCES

1. Reimold SC, Rutherford JD. Valvular Heart Disease in Pregnancy. N England J Med. 2003;2.
2. Nishimura RA, Otto CM, Bonow RO. 2014 AHA/ACC Guideline for the Management of Patients with Valvular Heart Disease. J Am College Cardiol. 2014;63:57-185.
3. Kumari A, Kumar K, Sinha A. The Pattern of Valvular Heart Diseases in India During Pregnancy and Its Outcomes. Cureus. 2021;1.
4. Fedak PW, Verma S, David TE. Clinical and Pathophysiological Implications of a Bicuspid Aortic Valve. Circulation. 2000;106:900-4.
5. Siu SC, Colman JM. Congenital heart disease: Heart disease and pregnancy. Heart. 2001;85:710-15.
6. Thorne S. Pregnancy and native heart valve disease. Heart. 2016;102:1410-17.
7. Driul L, Merioi F, Sala A. Vaginal delivery in a patient with severe aortic stenosis under epidural analgesia, a case report. Cardiovascular Ultrasound. 2018;18.
8. Ruys TP, Roos-Hesselink JW, Pijuan-Domenech A. Is a planned caesarean section in women with cardiac disease beneficial? Heart. 2006;101:530-6.

Cite this article as: Kanagavarshani M, Kaur A, Sikka P, Aggarwal N, Chopra S. Vaginal delivery in a patient with asymptomatic severe aortic stenosis: a case report. Int J Reprod Contracept Obstet Gynecol 2023;12:2547-9.