

DOI: <https://dx.doi.org/10.18203/2320-1770.ijrcog20261465>

Case Report

Ethanol sclerotherapy twice and one laparoscopic surgery for stage IV pelvic endometriosis and bilateral ovarian endometrioma over two decades: a case report

Pratibha Devabhaktuni^{1*}, Mahjabeen Singh²

¹Department of Obstetrics and Gynaecology, Modern Government Maternity Hospital, Osmania Medical College, Hyderabad, Telangana, India

²Department of Imageology, Swapna Health Care, Begumpet, Hyderabad, Telangana, India

Received: 20 April 2026

Revised: 03 May 2026

Accepted: 04 May 2026

***Correspondence:**

Dr. Pratibha Devabhaktuni,
E-mail: dpdnk@yahoo.com

Copyright: © the author(s), publisher and licensee Medip Academy. This is an open-access article distributed under the terms of the Creative Commons Attribution Non-Commercial License, which permits unrestricted non-commercial use, distribution, and reproduction in any medium, provided the original work is properly cited.

ABSTRACT

In January 2008, Mrs. BP, at the age of 28 years, a para one, live child one, previous lower segment caesarean section (LSCS), and an ovarian cyst, left endometrioma, underwent laparotomy and ovarian cystectomy under spinal anaesthesia. On 12 July 2008, a scan revealed well defined cystic lesions in the right adnexa, 5.0×4.8 cm, and 2.3×2.1 cm and left ovary two cysts measuring 1.8×1.2, and 2.6×1.6 cm. In December 2008, operative laparoscopy was performed. Adhesiolysis, fulguration with dessication of all the visible endometriotic lesions, right ovarian chocolate cystectomy, 10×8 cm. was done. Left ovary had a 1.5 cm endometriotic cyst, that was drained and cyst wall cauterized. Pouch of Douglas, the bowel was pulled up. Methylene blue chromotubation for the patency of the fallopian tubes was positive on both the sides. Diagnosis, stage IV endometriosis. She was treated with ovulogens for two or three cycles. This resulted in ovarian cyst formation, hence stopped. On 17 April 2010, ultrasonography (USG) evidence of a large recurrent right ovarian endometrioma of 10×9 cm one and a half years after the laparoscopic management of stage IV endometriosis in 2008. The first ethanol sclerotherapy (EST) was done in this case on 27 November 2010, under USG guidance. She conceived spontaneously in 2018. Second delivery by LSCS in USA, a boy 4.125 kg on 05 December 2018. Left ovarian chocolate cyst noted in February 2020, EST was done a second time. Aspirated 120 ml of chocolate thick material. On 24 February 2020, injected 7 ml of absolute alcohol into the left ovarian chocolate cyst under ultrasound guidance. She had a second child, she could avoid a repeat major surgery, both the objectives could be achieved and were facilitated by EST done on two occasions. EST serves to ameliorate endometriosis and serves as an additional modality of treatment in select cases.

Keywords: Endometriosis, Endometrioma, Ethanol sclerotherapy, Endometriotic cystectomy, Secondary infertility

INTRODUCTION

Regarding endometriosis and infertility, there is a strong correlation, since about 30 to 50% of women with endometriosis have infertility, while 25 to 50% of infertile women have endometriosis.¹ The prominent symptom is pain in about half of the patients, while it is infertility in the other half.² There are multiple mechanisms that cause infertility including anatomical changes in the pelvic

cavity, uterus, and ovaries, which may cause impaired oocyte, sperm, and embryo transport, impaired folliculogenesis, granulosa cell dysfunction, impaired immune functions in follicular and peritoneal fluid, impaired sperm function, and fertilization and implantation defects.

About 17-44% of women diagnosed with endometriosis will develop endometriomas.³ Signs and symptoms of the

disease are related to its location and include chronic pelvic pain, pain associated with menstruation (dysmenorrhoea), pain during intercourse (dyspareunia), periodic or menstrual-related gastrointestinal and urinary symptoms, as well as infertility.⁴ In deep endometriosis, it is deep endometriosis resection with adhesion stripping laparoscopically, and with respect to endometriomas, it is ovarian cystectomy performed by laparoscopy.⁵ In these cases, as endometriomas are surrounded by a pseudocapsule, healthy ovarian tissue is inevitably removed during cystectomy. In addition, the use of energy in order to achieve haemostasis leads to further reduction in the ovarian reserve.⁶

During sclerotherapy, the effect on ovarian tissue is different. More specifically, the endometriotic fluid is removed by suction, its cavity is washed out and a solution of ethanol is injected to destroy the pseudocapsule.⁷ In this way, iatrogenic damage is possibly minimized, ovarian parenchymal preservation optimized, and sclerotherapy standardized as a safe and less invasive technique.⁸

The surgical resection of endometriomas significantly decreases ovarian reserve and may further diminish the cumulative live birth rate.⁹ In the circumstances, ethanol sclerotherapy (EST) has the potential to eliminate endometriomas while also preserving ovarian reserve.

Endometrioma surgery has a significantly negative impact on ovarian reserve. According to the analysis, 9–12 months after surgery, serum AMH levels decrease by 39.5% in unilateral cystectomy and 57% in bilateral cystectomy.⁹

The rationale for sclerotherapy is to destroy the pseudocapsule of the endometrioma by instilling alcoholic substances inside it.¹⁰ Sclerotherapy has been considered a cost effective and safe option to preserve healthy ovarian tissue with a low incidence of Clavien-Dindo complications.¹¹⁻¹⁵

Data in the systematic review show that sclerotherapy in endometriomas has a varied recurrence rate [RR], ranging from 0.0% to 61.9%., most literature data report recurrence rates <30%, over an average FU period of 1 year.¹⁶ Pregnancy rates [PR] for ethanol sclerotherapy and endometriotic cystectomy appeared comparable; however, sclerotherapy resulted in larger number of eggs retrieved and no loss of ovarian reserve. Evidence suggests that endometrioma cystectomy can significantly reduce ovarian reserve. EST is a promising, minimally invasive alternative.¹⁷

Mechanism of action

The sclerosing agent seems to be relevant since sclerotherapy with tetracyclines or methotrexate had higher RR and lower PR. Tetracyclines and methotrexate act in the cell-cycle functions through molecular pathways, whereas ethanol injures endometrioma's pseudocapsule

with a mechanism including cytotoxicity, thrombosis, and cells hypertonic dehydration.¹⁸⁻²⁰ Apparently, long ethanol retention times and small dilutions may be associated with the complete degradation of the pseudocapsule's cytoarchitecture. In most cases, the ethanol is preferred to sclerosing substances because it has shown better outcomes in the management of renal and hepatic cysts.¹⁰ Sclerotherapy can be practiced through the use of both general or local anesthetics, and it is well-tolerated by the patients. The feasibility in programming, cost-effectiveness, and rapid recovery after the technique suggest that it can be considered the standard of care for minimally invasive interventions, like EST of ovarian endometrioma.¹⁰

History

EST for an endometrioma was first described by Akamatsu et al in 1988, with six procedures performed on five patients.²¹ The initial approach involved aspiration followed by 30 min of alcohol exposure.²¹ Sclerotherapy was suggested as a promising approach in 1997 as part of an ART program for recurrent endometriomas after medical and surgical treatment.²² EST continues to be a popular option, particularly due to its potential protective effect on ovarian reserve compared to cystectomy.

CASE REPORT

On January 2008, at the age of 28 years, with an obstetric history, para one, live child one, previous LSCS, and an ovarian cyst, suspected endometriotic cyst, she underwent laparotomy and ovarian cystectomy under spinal anaesthesia. Left ovarian chocolate cyst was adherent to the uterus and intestine.

On 12 July 2008, a scan was done at KIMS, Hyderabad, which revealed well defined cystic lesions in the right adnexa, 5.0×4.8 cm, and 2.3×2.1 cm. Left ovary two cysts measuring 1.8×1.2, and 2.6×1.6 cm.

In December 2008, operative laparoscopy was performed. Adhesiolysis, fulguration with dessication of all the visible endometriotic lesions, right ovarian chocolate cystectomy, 10×8 cm was done. Left ovary had multiple small follicular cysts and 1.5 cm endometriotic cyst, that was drained and cyst wall cauterized. Pouch of Douglas, the bowel was pulled up. Methylene blue chromotubation for the patency of the fallopian tubes was positive on both the sides. Diagnosis, stage IV endometriosis. She was not on any postoperative hormonal therapy as she wanted a second child. She was living in the USA, and would consult when she could come to Hyderabad.

The typed operation notes from 2008 revealed operative laparoscopy, three portals, adhesiolysis, drainage of bilateral chocolate cysts, and right ovary had an endometrioma 10×8 cm. Partial cystectomy and fulguration of the cyst wall was done. Left ovary was the seat of multiple small follicular cysts and 1.5 cm chocolate

cyst, close to the left ovarian ligament, the cyst wall was cauterized. Multiple endometriotic lesions on the uterine surface, near the uterosacral ligaments, near the round ligaments, some excised and cauterized. Pouch of Douglas, obliterated, bowel pulled up. Uterus was normal in size. Left fallopian tube had moderate hydrosalpinx. Methylene blue dye test positive both sides. Stage IV endometriosis was recorded.

She was treated with ovulogens for two or three cycles. This resulted in ovarian cyst formation, hence stopped.

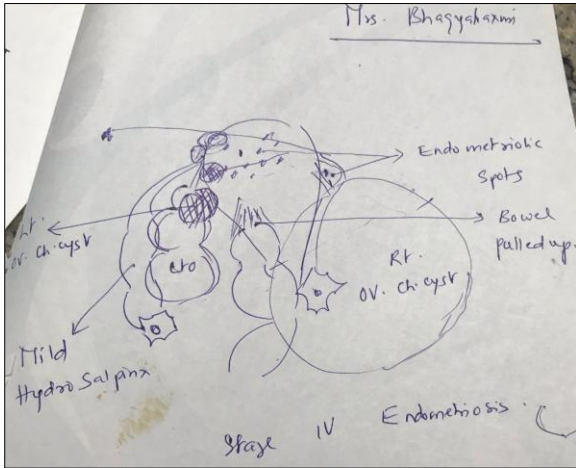


Figure 1: Diagrammatic representation of the laparoscopy operative findings, recorded by the author Dr. D. Pratibha in 2008.

On 17 April 2010, within two years of laparoscopic surgery, she had recurrent right ovarian endometrioma. USG report revealed right ovary 10×9×8.8 cm, totally occupied by cysts. dense pelvic adhesions. Small cysts in the left ovary.

In 1996, the author managed a case of pelvic endometrioma by sclerotherapy in a case of recurrent pelvic endometrioma by transvaginal aspiration of the chocolate material and injection of ethanol into the pseudocyst at the vaginal vault, in a woman post hysterectomy and bilateral salpingo oophorectomy.

Three times the pseudocyst was aspirated and 5 ml ethanol was injected each time into the cyst, over one year. Later the woman was asymptomatic during a follow up period of two to three years.

With the previous experience, this woman was also advised EST. She had EST in November 2010 for the right ovarian endometrioma.

In the year 2011, the lady consulted an ART specialist for second conception. Ovarian endometrioma was aspirated, but EST was not given, then she was enrolled for an IVF cycle, as there was no follicular growth, the cycle was

cancelled. TVS report on 26 October 2011. No obvious pathology noted.

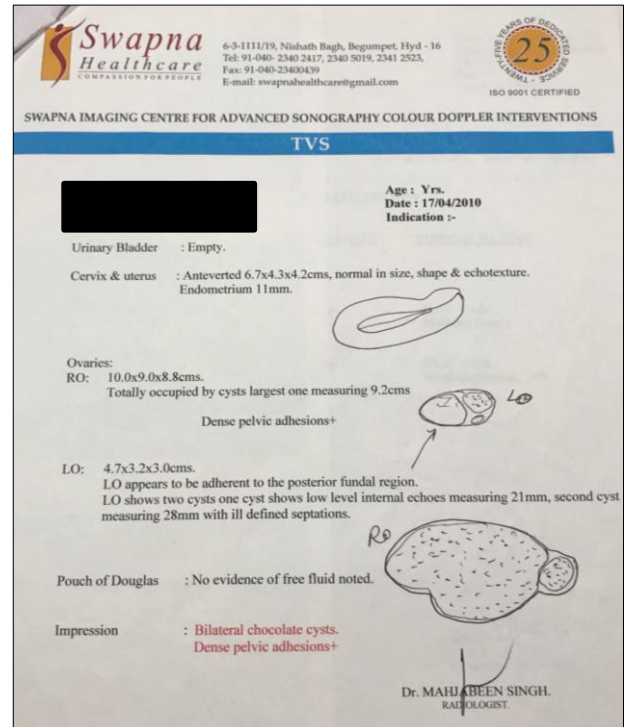


Figure 2: USG evidence of a large recurrent rt. ovarian endometrioma one and a half years after the laparoscopic management of stage IV endometriosis in 2008, by Dr. Pratibha D. The first EST was done in this case on 27 November 2010, under USG guidance.

Second conception, she wanted to consult in an ART centre in the US, but the economic expenses were not within reach, so she did not approach them. She conceived spontaneously in 2018. Second delivery by LSCS in USA, baby boy 4.125 kg on 05 December 2018.

USG revealed left ovarian chocolate cyst February 2020. Right ovary adherent to the uterine wall. Cyst 1.8 cm with ill-defined walls in the right ovary. Left ovary had a chocolate cyst, 7.5×5.1 cm. She had cholelithiasis.

Aspiration of the left ovarian endometriotic cyst and sclerotherapy with ethanol 95%, absolute alcohol (EST) was advised by Dr. Pratibha and the lady was referred to sonologist Dr. Mahjabeen Singh, at Swapna Health Care after discussion.

Notes by Dr. Mahjabeen Singh after performing the EST, the second time in February 2020. On 22 February 2020, aspirated 120 ml of chocolate thick material from the left ovarian cyst. Procedure uneventful. On 24 February 2020, injected 7 ml of absolute alcohol into the left ovarian chocolate cyst under ultrasound guidance.

Present status March 2026, currently menses once in two to three months, just spotting for two three days. When

enquired about dysmenorrhoea, some heavy sensation in the lower abdomen and backache right side.

Advised her to get FSH, AMH, CA125, USG whole abdomen and TVS pelvis, she plans to come to India shortly and said she would get them done.

DISCUSSION

Endometrioma recurrence was noted in 38 out of 225 patients that underwent U/S sclerotherapy, with a total recurrence rate of 16.88%.^{23,28} In the group of patients who underwent laparoscopic sclerotherapy, 11 had recurrence of endometriomas, having a total recurrence rate of 9.01%.^{27,28} This is in contrast with the patients in the laparoscopic cystectomy group, for whom the recurrence rate went up to 15.57%.²³⁻²⁶

Among 225 patients who underwent U/S sclerotherapy, 32 achieved a clinical pregnancy (14.22%).^{23,29,25} 34 out of 122 patients that underwent laparoscopic sclerotherapy achieved clinical pregnancy (27.87%).^{27,28} Finally, from a total of 199 patients who had a laparoscopic cystectomy, 24 achieved clinical pregnancy, with a total clinical pregnancy rate of 12.06%.^{23,25} A live birth rate of 11.11% was achieved after ART in women who had U/S sclerotherapy.^{23,29} Furthermore, 22 of the 199 patients who underwent laparoscopic cystectomy gave birth with a live birth after ART, a rate of 11.05%.²³

U/S sclerotherapy caused 2.18% reduction in AMH levels, while laparoscopic sclerotherapy and laparoscopic cystectomy caused 41.14% and 42.30% reduction, respectively. These findings are consistent with a study by Raffi et al, which reported 38% decline in AMH levels after cystectomy, as well with the meta-analysis by Kim et al where there was no significant difference in AMH level before and after U/S sclerotherapy.^{30,31} When clinical pregnancy rate was assessed, data indicated 14.22% and 12.06%, respectively, for U/S sclerotherapy and laparoscopic cystectomy, while laparoscopic sclerotherapy group noted a clinical pregnancy rate of 27.87%. This is quite impressive that indicates possible the superiority of laparoscopic sclerotherapy. In that case, ovarian tissue is preserved better and also at the same time any other area of endometriosis can be excised. As a result, the inflammatory background is limited, fact that potentially contributes to the increase of clinical pregnancy.³² A systematic review and meta-analysis by Cohen et al. showed that abdominal pain is the most common complication found in 1.8-15.3% of the patients, and postoperative fever is present in 5.5%. Alcohol intoxication is found in 3.8%, while intracystic abscess appears in 2%.⁷

EST is a viable alternative to endometriotic cystectomy for treating endometrioma in reproductive-age women. It has the advantage of being safe and effective for pain relief and potentially superior to cystectomy in preserving ovarian reserve.¹⁷

The analysis demonstrates comparable incidence of recurrence and pregnancy rate between surgery and sclerotherapy. Sclerotherapy could be a safe and valid alternative in patients contraindicated for more complex surgery.¹⁶

The study compares the two available options of EST, ultrasound-guided (U/S) and laparoscopic sclerotherapy, with laparoscopic cystectomy, which is the gold standard treatment.³³ The comparison took into account the effect on the ovarian reserve, monitored by anti-Müllerian hormone (AMH), the effect on cancer antigen 125 (CA-125), recurrence rate, symptom relief, clinical pregnancy rate, and finally the live birth rate after assisted reproductive technology (ART).³³ The review examines the safety, efficacy, and impact of EST on ovarian reserve, IVF outcomes, and recurrence rates.³⁴ Comparative studies suggest that pregnancy rates following EST are similar to or better than those after cystectomy, with the added benefit of more oocytes retrieved, which may lead to higher cumulative live birth rates.³⁴ EST shows promise as a treatment for ovarian endometriomas in IVF patients. It effectively reduces the size of endometriomas and alleviates associated symptoms without significantly compromising the ovarian reserve.³⁴

CONCLUSION

She had a second child, she could avoid a repeat major surgery, both the objectives could be achieved and were facilitated by EST done on two occasions. EST serves to ameliorate endometriosis and serves as an additional modality of treatment in select cases.

ACKNOWLEDGEMENTS

Authors would like to thank the hospital administration, Swapna Health Care, for providing the state of the art equipment to do the procedures.

Funding: No funding sources

Conflict of interest: None declared

Ethical approval: Not required

REFERENCES

1. Bulletti C, Coccia ME, Battistoni S, Borini A. Endometriosis and infertility. J Assist Reprod Genet. 2010;27:441-7.
2. Eskenazi B, Warner ML. Epidemiology of endometriosis. Obstet Gynecol Clin N Am. 1997;24:235-58.
3. Exacoustos C, De Felice G, Pizzo A, Morosetti G, Lazzeri L, Centini G, et al. Isolated Ovarian Endometrioma: A History Between Myth and Reality. J Minim Invasive Gynecol. 2018;25(5):884-91.
4. Parasar P, Ozcan P, Terry KL. Endometriosis: epidemiology, diagnosis and clinical management. Curr Obstet Gynecol Rep. 2017;6:34-41.

5. Baraki D, Richards EG, Falcone T. Treatment of endometriomas: surgical approaches and the impact on ovarian reserve, recurrence, and spontaneous pregnancy. *Best Pract Res Clin Obstet Gynaecol.* 2024;92:102449.
6. Sanchez AM, Viganò P, Somigliana E, Panina-Bordignon P, Vercellini P, Candiani M. The distinguishing cellular and molecular features of the endometriotic ovarian cyst: from pathophysiology to the potential endometrioma-mediated damage to the ovary. *Hum Reprod Update.* 2014;20:217-30.
7. Cohen A, Almog B, Tulandi T. Sclerotherapy in the management of ovarian endometrioma: systematic review and meta-analysis. *Fertil Steril.* 2017;108:117-24.e5.
8. Ronsini C, Iavarone I, Braca E, Vastarella MG, De Franciscis P, Torella M. The efficiency of sclerotherapy for the management of endometrioma: a systematic review and meta-analysis of clinical and fertility outcomes. *Medicina (Kaunas).* 2023;59:1643.
9. Younis JS, Shapso N, Fleming R, Ben-Shlomo I, Izhaki I. Impact of unilateral versus bilateral ovarian endometriotic cystectomy on ovarian reserve: a systematic review and meta-analysis. *Hum Reprod Update.* 2019;25:375-91.
10. Castellarnau Visus M, Ponce Sebastia J, Carreras Collado R, Cayuela Font E, Garcia Tejedor A. Preliminary results: ethanol sclerotherapy after ultrasound-guided fine needle aspiration without anesthesia in the management of simple ovarian cysts. *J Minim Invasive Gynecol.* 2015;22:475-82.
11. Ruiz-Flores FJ, Garcia-Velasco JA. Is there a benefit for surgery in endometrioma-associated infertility? *Curr Opin Obstet Gynecol.* 2012;24:136-40.
12. Dunselman GAJ, Vermeulen N, Becker C, Calhaz-Jorge C, D'Hooghe T, De Bie B, et al. ESHRE guideline: management of women with endometriosis. *Hum Reprod.* 2014;29:400-12.
13. Okagaki R, Osuga Y, Momoeda M, Tsutsumi O, Taketani Y. Laparoscopic findings after ultrasound-guided transvaginal ethanol sclerotherapy for ovarian endometrial cyst. *Hum Reprod.* 1999;14:270.
14. Radosa MP, Meyberg-Solomayer G, Radosa J, Vorwerck J, Oettler K, Mothes A, et al. Standardised registration of surgical complications in laparoscopic-gynaecological therapeutic procedures using the Clavien-Dindo classification. *Geburtshilfe Frauenheilkd.* 2014;74:752-8.
15. Cohen A, Almog B, Tulandi T. Sclerotherapy in the management of ovarian endometrioma: systematic review and meta-analysis. *Fertil Steril.* 2017;108:117-24.e5.
16. Ronsini C, Iavarone I, Braca E, Vastarella MG, De Franciscis P, Torella M. The efficiency of sclerotherapy for the management of endometrioma: a systematic review and meta-analysis of clinical and fertility outcomes. *Medicina (Kaunas).* 2023;59:1643.
17. Younis JS, Shapso N, Izhaki I, Taylor HS. Ethanol sclerotherapy for management of endometriomas: an overview of systematic reviews. *Front Endocrinol (Lausanne).* 2025;16:1612899.
18. Agostini A, De Lapparent T, Collette E, Capelle M, Cravello L, Blanc B. In situ methotrexate injection for treatment of recurrent endometriotic cysts. *Eur J Obstet Gynecol Reprod Biol.* 2007;130:129-31.
19. Gonçalves FC, Andres MP, Passman LJ, Gonçalves MO, Podgac S. A systematic review of ultrasonography-guided transvaginal aspiration of recurrent ovarian endometrioma. *Int J Gynaecol Obstet.* 2016;134:3-7.
20. Albanese G, Kondo KL. Pharmacology of sclerotherapy. *Semin Intervent Radiol.* 2010;27:391-9.
21. Akamatsu N, Hirai T, Masaoka H, Sekiba K, Fujita T. Ultrasonically guided puncture of endometrial cysts—aspiration of contents and infusion of ethanol. *Nihon Sanka Fujinka Gakkai Zasshi.* 1988;40:187-91.
22. Chang CC, Lee HF, Tsai HD, Lo HY. Sclerotherapy—an adjuvant therapy to endometriosis. *Int J Gynaecol Obstet.* 1997;59:31-4.
23. Alborzi S, Askary E, Keramati P, Moradi Alamdarloo S, Poordast T, Ashraf MA, et al. Assisted reproductive technique outcomes in patients with endometrioma undergoing sclerotherapy vs laparoscopic cystectomy: prospective cross-sectional study. *Reprod Med Biol.* 2021;20(3):313-20.
24. Koo JH, Lee I, Han K, Seo SK, Kim MD, Lee JK, et al. Comparison of the therapeutic efficacy and ovarian reserve between catheter-directed sclerotherapy and surgical excision for ovarian endometrioma. *Eur Radiol.* 2021;31:543-8.
25. Garcia-Tejedor A, Martinez-Garcia JM, Candas B, Suarez E, Mañalich L, Gomez M, et al. Ethanol sclerotherapy versus laparoscopic surgery for endometrioma treatment: a prospective, multicenter, cohort pilot study. *J Minim Invasive Gynecol.* 2020;27(5):1133-40.
26. Ghasemi Tehrani H, Tavakoli R, Hashemi M, Haghighat S. Ethanol sclerotherapy versus laparoscopic surgery in management of ovarian endometrioma: a randomized clinical trial. *Arch Acad Emerg Med.* 2022;10:e55.
27. Vaduva CC, Dira L, Carp-Veliscu A, Goganau AM, Ofiteru AM, Siminel MA. Ovarian reserve after treatment of ovarian endometriomas by ethanolic sclerotherapy compared to surgical treatment. *Eur Rev Med Pharmacol Sci.* 2023;27:5575-82.
28. Lee JK, Ahn SH, Kim HI, Lee YJ, Kim S, Han K, et al. Therapeutic efficacy of catheter-directed ethanol sclerotherapy and its impact on ovarian reserve in patients with ovarian endometrioma at risk of decreased ovarian reserve: a preliminary study. *J Minim Invasive Gynecol.* 2022;29(2):317-23.
29. Miquel L, Preaubert L, Gnisci A, Resseguier N, Pivano A, Perrin J, et al. Endometrioma ethanol sclerotherapy could increase IVF live birth rate in women with moderate-severe endometriosis. *PLoS One.* 2020;15:e0239846.

30. Raffi F, Metwally M, Amer S. The impact of excision of ovarian endometrioma on ovarian reserve: a systematic review and meta-analysis. *J Clin Endocrinol Metab.* 2012;97:3146-54.
31. Kim GH, Kim PH, Shin JH, Nam IC, Chu HH, Ko HK. Ultrasound-guided sclerotherapy for the treatment of ovarian endometrioma: an updated systematic review and meta-analysis. *Eur Radiol.* 2022;32:1726-37.
32. Tanbo T, Fedorcsak P. Endometriosis-associated infertility: aspects of pathophysiological mechanisms and treatment options. *Acta Obstet Gynecol Scand.* 2017;96:659-67.
33. Lentzaris D, Gkrozou F, Skentou C, Koutalia N, Bais V, Vatopoulou A, et al. Future of sclerotherapy in the treatment of endometriosis: a narrative literature review. *Cureus.* 2025;17(3):e81215.
34. Sükür YE, Aslan B, Varlı B, Özcan P, Daniilidis A, Kalaitzopoulos DR. Ethanol sclerotherapy for endometriomas in infertile women: a narrative review. *J Clin Med.* 2024;13:7548.

Cite this article as: Devabhaktuni P, Singh M. Ethanol sclerotherapy twice and one laparoscopic surgery for stage IV pelvic endometriosis and bilateral ovarian endometrioma over two decades: a case report. *Int J Reprod Contracept Obstet Gynecol* 2026;15:2211-6.