

DOI: <https://dx.doi.org/10.18203/2320-1770.ijrcog20243215>

Case Report

Utero cutaneous fistula after caesarean section: a case report

Kalpesh Kucha, Himunshu Vaishnav, Pradeep Damor, Ami Yagnik,
Gayatri Desai, Nandita Maitra*

Sewa Rural Jaghadia, Bharuch, Gujarat, India

Received: 03 September 2024

Accepted: 08 October 2024

***Correspondence:**

Dr. Nandita Maitra,

E-mail: n.maitra03@gmail.com

Copyright: © the author(s), publisher and licensee Medip Academy. This is an open-access article distributed under the terms of the Creative Commons Attribution Non-Commercial License, which permits unrestricted non-commercial use, distribution, and reproduction in any medium, provided the original work is properly cited.

ABSTRACT

Uterocutaneous fistula is a rare pathology which occurs most commonly after a caesarean section. This is the case report of a 26-year-old patient who presented soon after her second caesarean section, with an abdominal nodule and cyclical pain and discharge from it. A pelvic MRI confirmed the diagnosis. Surgical management was successful.

Keywords: Utero cutaneous, Fistula, Post caesarean

INTRODUCTION

A utero cutaneous fistula (UCF) is a rare condition in which there is an abnormal communication between the abdominal wall and the uterine cavity.¹ It is usually seen following a caesarean section. It may also be seen following other procedures such as a uterine curettage, after multiple abdominal surgeries or surgery for endometriosis.² We present here a case of post-caesarean uterocutaneous fistula that was successfully treated with excision of the fistulous tract and repair of the fistulous opening in the uterus.

CASE REPORT

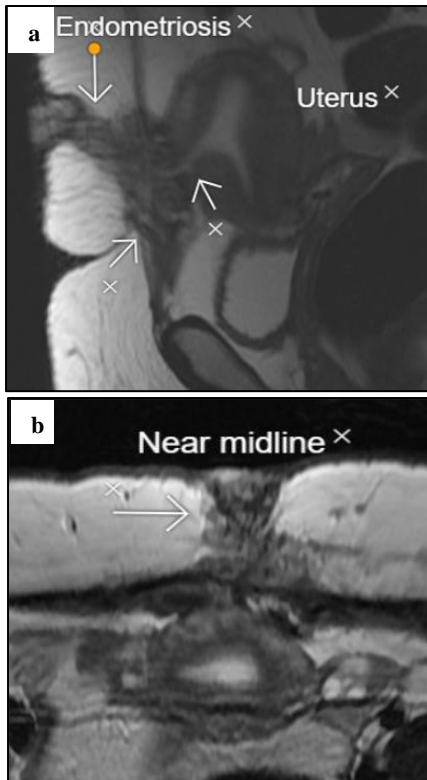
A 26 years old patient, was admitted with the complaint of pain in left lower abdomen with cyclical bleeding from a nodule in the sub umbilical region since, three years. Her complaints started soon after a caesarean section which she had in another hospital in 2021. She complained of severe dysmenorrhea. The pain appeared two days prior to menstruation, and continued until day 2 or 3 of menstruation. The pain was burning in nature, non-radiating and confined to the site of the palpable lump. There were no relieving or aggravating factors. The cyclical bleeding was mild in amount, bright red in colour and non- foul smelling. Her menstrual cycles were regular.

She had two previous caesarean sections. Her complaint started soon after the second caesarean section. Her second pregnancy resulted in a preterm caesarean section done at 8th month of pregnancy in a private hospital elsewhere, in view of intra uterine fetal death. One-week post-partum she developed a coin sized opening between the umbilicus and caesarean scar incision She complained of bleeding from this opening. She was given reassurance by the treating doctor that this would heal on it's own. The coin sized opening gradually turned into a nodule from which there was cyclical bleeding.

On examination a Pfannenstiel incision scar was present in lower abdomen. One nodule-like structure, fleshy red, 1 by 1 cm in size was seen on anterior abdominal wall, approximately 5 cm above the previous caesarean scar. On palpation, the nodule was fixed and non-compressible with mild tenderness. On bimanual examination uterus was retroverted with restricted mobility. Ultrasonography revealed normal size (7.5×4.6) acutely retroflexed and retroverted uterus. A 4.6×2.5 cm area of mixed echogenicity was seen underlying the skin and reaching up to the mid uterus. Magnetic Resonance Imaging (MRI) (Figures 1a and 1b) showed a fairly large, ill-defined altered signal intensity lesion detected in the lower anterior abdominal wall, which was heterogeneously hypointense on T2Wt images and revealed multiple T2 hyperintense

cystic areas within it. It was involving the subcutaneous fat near midline and left paramedian region and all the muscles in the anterior abdominal wall. There was a well-defined defect in the anterior wall of uterus measuring around 1.2 cm antero-posteriorly. The abdominal wall lesion measured 7.0×4.7 cm in the midline, 3.5×2.3 cm in paramedian region and around 11.3 cm in maximum transverse dimension.

A provisional diagnosis of utero cutaneous fistula (UCF) was made and patient was posted for surgery after proper counseling and pre-operative work-up.



Figures 1 (a and b): MRI images showing a large defect in anterior abdominal wall in communication with the uterus in longitudinal and transverse planes.

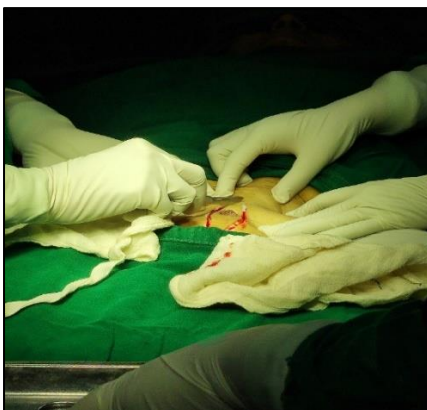

Figure 2: Elliptical incision on abdomen around the fistulous opening.

An elliptical incision was placed over abdomen and extended on either side of the cylindrical stump with an adequate 1 cm margin (Figure 3). Wide excision of the fistulous tract involving the skin, subcutaneous tissue, rectus sheath and muscle was performed (figure 4). The fistulous tract was seen attached with anterior uterine wall. A defect of 1.5 cms was seen in the region of lower segment in uterus (Figure 5). This was closed in two layers and covered with an omental interposition patch. Due to the wide abdominal wall defect, full length fascial closure was not feasible so, a non-absorbable polypropylene macroporous mesh was placed. Standard subcutaneous suction drainage was used to minimize post operative wound complications and skin was closed with single non absorbable suture in vertical mattress manner. The specimen was sent for histopathological examination. Macroscopically the specimen measured 7×5×5 cms. Cut surface showed a sinus tract 4.5 cms long. On histopathology, the sections showed endometrial glands lined by benign endometrial cells surrounded by stromal cells and hemosiderin laden macrophages. The report confirmed the suspicion of endometriosis in a utero cutaneous fistula. Patient was discharged after an uneventful post operative period.

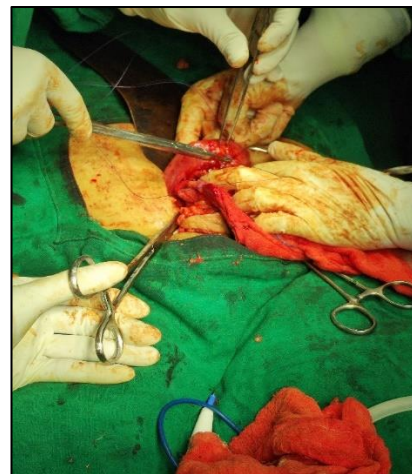


Figure 3: The excised fistulous tract.

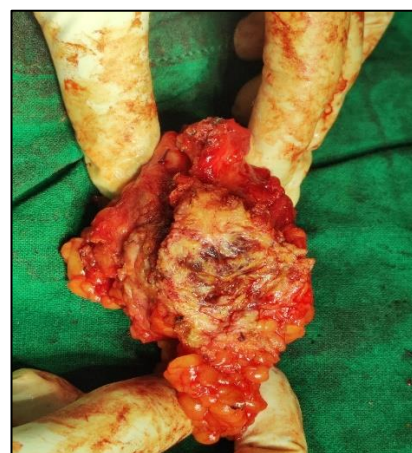


Figure 4: Uterine defect.

DISCUSSION

Utero cutaneous fistula is a rare abnormal communication between the epithelial lining of the skin and uterus.¹ Not much is known about this condition in existing literature, except what is available as case reports published on the topic. In most case reports published so far, it was noted that the fistulous opening was along the previous caesarean scar site, whereas in this patient the opening on the abdominal wall was about 5 cm above the previous pfannensteil scar in the sub umbilical region. The previous scar did not show any abnormality.

UCF is most commonly seen after caesarean section, although other uterine procedures (curettage, myomectomy, post-partum sepsis, pelvic tuberculosis, endometriosis surgery, migrated intrauterine device and pelvic actinomycosis) may also be associated with this condition.²⁻⁴ Utero cutaneous fistula can be diagnosed based on high clinical suspicion and confirmed by the use of imaging techniques such as ultrasound, CT scan or MRI with contrast. Fistulography may also be used. Hysterosalpingography with injection of methylene blue dye into cervix has also been described by Min et al in 2018 in a uterocutaneous fistula that developed after pelviscopic resection of a myoma.⁵ Hysteroscopy may be used prior to surgery to visualize the internal opening in the uterine cavity. Ilyas et al, in a case report published in 2019 have studied the role of MRI in the evaluation of a post caesarean UCF. MRI provides good soft tissue resolution, avoids radiation (as all other investigations involve significant radiation doses), and helps in proper delineation of the fistulous tract and its relation to the surrounding viscera. Intravenous contrast administration shows the enhancement of the granulation tissue along the fistulous tract, which gives a clue about the active status of the fistula. Hence, MRI forms the best investigative modality in the assessment of UCF.⁶

Lim et al reported a UCF secondary to red degeneration of an intramural fibroid.⁷ Jadib et al have reported the case of a UCF in a 27-year-old lady, with systemic lupus erythematosus.⁸ A pelvic CT scan with the injection of the contrast material through the cutaneous fistulous opening confirmed the diagnosis of utero-cutaneous fistula. Chattot et al have described a utero abdominal wall fistula after a caesarean section in a woman with prior colorectal resection for endometriosis. The authors also conducted a systematic review in which 18 case reports were found from 1939 to 2016.⁹

The primary treatment of UCF is surgical excision of the fistulous tract without or with a subtotal or total hysterectomy.^{2,3} Carles et al have described successful medical treatment with gonadotrophin releasing hormone analogues. They recommend that a trial of gonadotrophin releasing hormone analogues for at least 6 months particularly in cases of uterocutaneous fistula of 5 mm or less in diameter be tried, as this conservative treatment is likely to obviate the need for more hazardous surgical

intervention.¹⁰ Han et al, studied the role of hormone receptors in a post myomectomy utero cutaneous fistula. They stated that GnRHa (gonadotropin-releasing hormone agonist) treatment as an option for conservative hormone therapy for UCF. The true status of hormone receptors in UCF lesions and its relationship with the therapeutic effect of GnRHa treatment have not yet been studied.¹¹

CONCLUSION

This case report highlights this rare condition of a uterocutaneous fistula occurring after a caesarean section. A high index of suspicion is required for diagnosis. MRI proved to be a reliable diagnostic tool. The UCF was treated successfully with wide surgical excision.

Funding: No funding sources

Conflict of interest: None declared

Ethical approval: Not required

REFERENCES

- Maddah G. Uterocutaneous fistula following cesarean section: successful management of a case. *Iran. J Med Sci.* 2016;41(2):157.
- Akkurt MÖ. Utero-cutaneous fistula after multiple abdominal myomectomies: a case report. *Balk. Med J.* 2015;32(4):426.
- Arif SH, Mohammed AA. Migrated intrauterine device presented as anterior abdominal wall abscess. *J. Surg. Case Rep.* 2019;2019(6):174.
- Wang Y. Uterocutaneous fistula after abdominal myomectomy: a case report. *J. Obstet. Gynaecol. Res.* 2021;47(9):3392-5.
- Min KJ, Lee J, Lee S, Lee S, Hong JH, Song JY, et al. Uterocutaneous fistula after pelviscopic myomectomy-successful diagnosis with hysterosalpingo contrast sonography and complete tract resection and medical treatment for fertility preservation in young woman: a case report. *Obstet Gynecol Sci.* 2018;61(5):641-4.
- Ilyas M, Khan I, Gojwari T, Dar MA, Shafi F, Shah OA. Post-LSCS uterocutaneous fistula-utility of magnetic resonance imaging in its diagnosis. *Turk J Obstet Gynecol.* 2019;16:133-5.
- PS Lim, MN Shafiee, S Ahmad, M Hashim Omar. Utero-cutaneous fistula after caesarean section secondary to red degeneration of intramural fibroid. *Sex Reprod Healthc.* 2012;3:95-6.
- Jadib A, Tabakh H, El Quazzani LC, Kardi O, Siwane A, Touil N et al. Utero-cutaneous fistula following caesarean section: A case report. *Radiology case reports.* 2022;17(1):77-9.
- Chattot C. Uteroabdominal Wall fistula after caesarean section in a patient with prior colorectal resection for endometriosis: a case report and systematic review. *J. Minim. Invasive Gynecol.* 2017;24(7):1234-8.
- Carles RS, Sharif S, Arias JR, Berg L, Nakhosteen A, Yoong W. Medical management of small uterocutaneous fistulae with gonadotrophin releasing

hormone analogs: Case report and literature review. *J Obstet Gynaecol Res.* 2023;49(2):759-62.

11. Han C, Zhang W, Li X, Sun B, Chung L. Postmyomectomy uterocutaneous fistula: a case

report and literature review. *Archives Gynecol Obstet* 2022;305:1099-103.

Cite this article as: Kucha K, Vaishnav H, Damor P, Yagnik A, Desai G, Maitra N. Utero cutaneous fistula after caesarean section: a case report. *Int J Reprod Contracept Obstet Gynecol* 2024;13:3391-4.