

DOI: <https://dx.doi.org/10.18203/2320-1770.ijrcog20260906>

## Case Report

# Periurethral abscess in pregnancy: a rare incidence

Adarsha Kalapala<sup>1\*</sup>, Vijaya Bharathi Byyarapu<sup>1</sup>, Amulya Ramadugu<sup>2</sup>,  
Vishnuvardhan Reddy V.<sup>3</sup>

<sup>1</sup>Department of Gynaecology, Fernandez Hospital, Hyderabad, Telangana, India

<sup>2</sup>Consultant Radiology, Fernandez Hospital, Hyderabad, Telangana, India

<sup>3</sup>Consultant Urologist, Fernandez Hospital, Hyderabad, Telangana, India

**Received:** 13 January 2026

**Revised:** 09 March 2026

**Accepted:** 10 March 2026

### \*Correspondence:

Dr. Adarsha Kalapala,

E-mail: [dradarsha.kalapala@fernandez.foundation](mailto:dradarsha.kalapala@fernandez.foundation)

**Copyright:** © the author(s), publisher and licensee Medip Academy. This is an open-access article distributed under the terms of the Creative Commons Attribution Non-Commercial License, which permits unrestricted non-commercial use, distribution, and reproduction in any medium, provided the original work is properly cited.

### ABSTRACT

Periurethral abscess in pregnancy has a rare incidence. The article showcases 2 case report of periurethral abscess in 3<sup>rd</sup> trimester of pregnancy, presenting symptoms, clinical features, imaging modalities for confirmation of the abscess and prompt management of the abscess with description of various modes of approach in dealing with such abscess.

**Keywords:** Peri urethral abscess, Pregnancy, Vaginal mass, Swelling at introitus

### INTRODUCTION

Periurethral abscess is a pus pocket in anatomical relation to the urethra. Its incidence in female population is less than 0.1 percent and the percentage of women being pregnant with concurrent periurethral abscess is even more rare.<sup>1</sup> In this article we report 2 cases of periurethral abscess in 3<sup>rd</sup> trimester of pregnancy showcasing their clinical course and management. As this is a rare occurrence utmost care and caution in management is required as morbidity in pregnant women might have long term implications.<sup>2</sup>

### CASE REPORT

#### Case 1

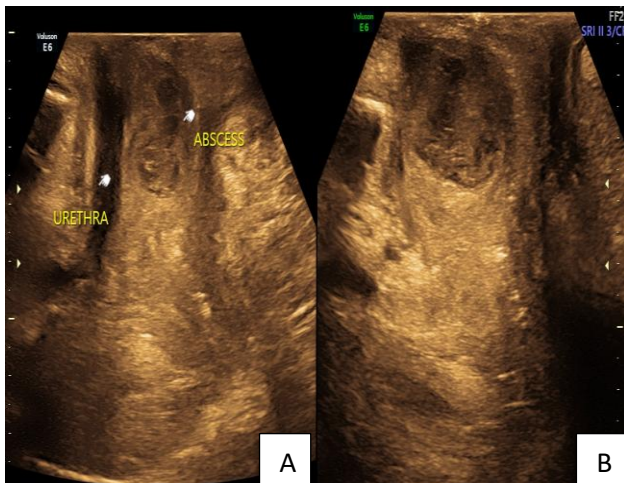
A second gravida with previous term caesarean presented at 31 weeks of gestational age with severe pain in the perineum for one day. On examination no definitive swelling noted on the perineum. Vaginal examination ruled out Bartholin's cyst or Abscess. Tenderness noted in the lower 1/3 of the anterior vaginal wall. On ultrasound examination with a transvaginal probe a well-defined thick

wall cyst with predominantly hypoechoic collection measuring 3 cm with a of volume 12 CC with perilesional vascularity seen posterior to the urethra with 4mm distance from urethral wall, hence the impression of a periurethral abscess was made. In view of her symptoms, an ultrasound findings plan was made for examination under anesthesia followed incision and drainage of abscess. Under spinal anesthesia, women was kept in lithotomy position, on cystoscopy bladder, upper 1/3, middle 1/3 of urethra were normal, a pus point noted in lower 1/3<sup>rd</sup> of urethra for which trans urethral drainage of 8 to 9 ml of pus done and sent for culture and sensitivity. Foley's catheterization of bladder was done for 1 week. She received sulbactam and cefparazone for antibiotic coverage. 1 week post-surgery ultrasound revealed an organized collection of 1 CC with clear contents, probably a sequel to drainage. She had an uneventful follow-up and had a cesarean section at 38 weeks not keen on TOLAC.

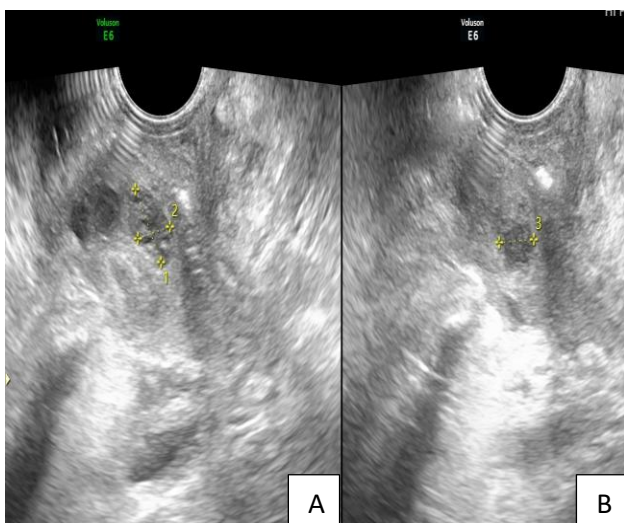
#### Case 2

A primi with 34+5 weeks of gestation was admitted in view of threatened preterm labour. On examination 4×3 centimeters cystic swelling on anterior lower 1/3<sup>rd</sup> vaginal wall noted, which was nontender, an impression of

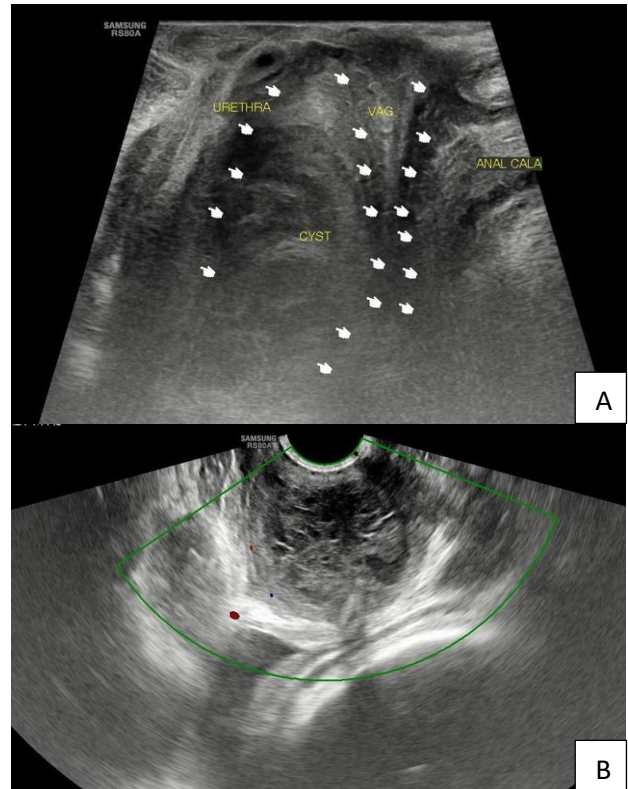
Gartners cyst/ vaginal wall cyst was made. She was discharged after 24 hours as she did not set into labour. At 36 weeks she presented with complaints of urinary retention. On examination, the previous noted vaginal swelling was of same size and had severe tenderness on touch. Suspicion of an infected cyst was made. Foley's catheterization was done. Ultrasound showed a 3.5 cm para urethral cyst at proximal and mid urethra with cyst contents showing reticular pattern suggestive of haemorrhage or infected material. In view of the location of the cyst plan for MRI before further intervention was made, but the patient had a spontaneous rupture of the abscess. On examination, it appeared that all the contents have spontaneously drained. She was covered with 3rd generation cephalosporins and foleys was removed after 48 hours. She was followed for one week and examination showed no palpable mass. At term she was induced for vaginal delivery and had an assisted vaginal birth.



**Figure 1 (A and B): Case report 1: pre operative scan image.**



**Figure 2 (A and B): Case report 1: post operative scan image.**



**Figure 3 (A and B): Case report 2: preoperative scan images.**

## DISCUSSION

Peri-urethral abscess is a rare painful collection of pus in the tissues surrounding the urethra. The risk factors include sexually transmitted infection, urinary tract infection, urethral diverticulum, immunocompromised state, urethral stricture and urethral instrumentation.

Symptoms include pelvic pain, fever, dysuria, pyuria, urinary retention and vaginal pain.<sup>3</sup>

In the 1<sup>st</sup> case report, the most probable cause for abscess is urethral diverticulum, as during cystoscopy a pus point was noted in the lower third of the urethra, while for the 2<sup>nd</sup> case most probably a preexisting cyst vaginal/ para urethral with super imposed pregnancy status might have led to infection, thus forming an abscess.

Imaging modalities to confirm the diagnosis of the abscess include ultrasound, CT, MRI, cystourethrography. Trans vaginal ultrasound has 100% specificity and sensitivity in diagnosis of the periurethral abscess along with CT and MRI, while cystourethrography has 93% in detection of the abscess. Noninvasive nature and easy availability makes ultrasound the 1<sup>st</sup> line of imaging, advanced imaging like MRI can be used when in doubt regarding the origin or the extent of the abscess.<sup>4</sup>

The treatment can be broadly classified into medical management and surgical management. As the data is

limited there are no clear guidelines as which mode to be selected for treating, it mostly dependent on the clinical scenario.

The medical management includes using antibiotics (as per culture and sensitivity report, if unavailable to use 3<sup>rd</sup> generation cephalosporins) along with analgesics.

Surgical management includes needle aspiration of the cyst contents, incision and drainage of the abscess with concurrent foleys catheterization. Endoscopic transurethral drainage of the abscess can be done depending on the expertise of the operating surgeon, rare cases require debridement if there is a picture of necrotising fasciitis. Precise and prompt treatment of the abscess is required as delay in the treatment can lead to fistula or stricture formation. Nowadays there is a wider application of ultrasound guided needle aspiration of the abscess. There is no difference in the clinical outcome on any of the above surgical methods used as there is limited data to draw an inference.<sup>5,6</sup>

## CONCLUSION

A periurethral abscess in pregnancy due to its close relation to the genital structures poses a challenge when comes to surgical management. On presentation high index of suspicion by the clinician is the mainstay in focused imaging for the abscess localization. There is no contradiction to have a vaginal birth post treatment of the abscess or during its course of treatment. In cases of recurrence of abscess, the possibility of urethral strictures or diverticulum with or without concurrent diabetes needs

to be considered. Imaging followed by surgical evacuation of the abscess is the primary method of management.

*Funding: No funding sources*

*Conflict of interest: None declared*

*Ethical approval: Not required*

## REFERENCES

1. Furniss HD. Sub-Urethral Abscesses and Diverticula in the Female Urethra. *J Urol.* 1935;33(5):498-503.
2. None DPP. Complex And Complicated Urethral Diverticulum in Female Patient. *Int J Med Pharmaceut Res.* 2025;6(5):1741-3.
3. Tariq A, Stewart AG, Desai DJ, Britton S, Dungalison N, Esler R, et al. Periurethral abscess etiology, risk factors, treatment options, and outcomes: A systematic review. *Curr Urol.* 2023;17(2):100-8.
4. Hahn WY, Israel GM, Lee VS. MRI for female urethral and periurethral disorders. *Am J Roentgenol.* 2004;182(3):677-82.
5. Ingrassia I, Silvestri G, Melani A, Scognamiglio P, Pinzi N. Skene's cyst in pregnancy. A clinical case. *Minerva Ginecol.* 1997;49(5):225-8.
6. Pushkar D, Anisimov AV. Paraurethral cyst and/or urethral diverticulum differential diagnosis. *Urologia.* 2007;(4):49-54.

**Cite this article as:** Kalapala A, Byyarapu VB, Ramadugu A, Reddy VV. Periurethral abscess in pregnancy: a rare incidence. *Int J Reprod Contracept Obstet Gynecol* 2026;15:1395-7.