

DOI: <https://dx.doi.org/10.18203/2320-1770.ijrcog20261299>

Case Report

Successful conservative management of a live asymptomatic cervical ectopic pregnancy: a case report

Jaydeb Mandal*, Sangamitra Moktan, Haragouri Murmu, Juhi Kumari

Department of Obstetrics and Gynaecology, Medical College Kolkata, West Bengal, India

Received: 26 February 2026

Accepted: 01 April 2026

***Correspondence:**

Dr. Jaydeb Mandal,

E-mail: jaydebm376@gmail.com

Copyright: © the author(s), publisher and licensee Medip Academy. This is an open-access article distributed under the terms of the Creative Commons Attribution Non-Commercial License, which permits unrestricted non-commercial use, distribution, and reproduction in any medium, provided the original work is properly cited.

ABSTRACT

Cervical ectopic pregnancy (CEP) is a rare and potentially life-threatening condition, accounting for less than 1% of all ectopic pregnancies, with a high risk of severe haemorrhage and fertility loss. A 24-year-old woman presented with 7 weeks of amenorrhoea and a positive serum β -human chorionic gonadotropin test. Transvaginal ultrasonography revealed a well-defined gestational sac in endo-cervical region, having fetal pole, crown-rump length measuring 8.4mm corresponding to 6 weeks 5 days cervical ectopic gestation with cardiac activity. Internal os was closed, Colour Doppler showed significant peritrophoblastic vascularity. Initial management with intramuscular methotrexate was followed by ultrasound-guided intra-gestational sac methotrexate and potassium chloride injection caused gradual decrease of serum β HCG levels and almost disappearance of products of conception within 2 weeks, without the need for additional interventional treatment. Conservative treatment including intramuscular methotrexate followed by intra-gestational sac methotrexate and potassium chloride administration may be effective in treating cervical ectopic pregnancy that even curettage may not be compulsory.

Keywords: Ectopic pregnancy, Amenorrhoea, Methotrexate, Gestational sac

INTRODUCTION

Ectopic pregnancy remains a leading cause of maternal morbidity and mortality in the first trimester of pregnancy. Cervical ectopic pregnancy (CEP) is an exceptionally rare form of non-tubal ectopic gestation, accounting for less than 1% of all ectopic pregnancies. The incidence of cervical ectopic pregnancy is reported between 1:8600 to 1: 12400 pregnancies¹. Implantation of the gestational sac within the endocervical tissue predisposes to catastrophic hemorrhage due to the rich cervical vascular supply and absence of contractile myometrial tissue, often necessitating emergency hysterectomy in the past. However due to improved ultrasound resolution it is possible for early detection of these pregnancies and lead to conservative treatment with an attempt to limit morbidity and preserve future fertility². The exact

etiopathogenesis of cervical pregnancy remains unclear; however, proposed mechanisms include accelerated migration of the fertilized ovum, altered endometrial receptivity, and prior cervico-uterine instrumentation. Classical diagnostic criteria described by Rubin and later modified by Palman include implantation of products of conception confined to the cervix with a closed internal os and an empty uterine cavity. Clinical diagnosis of cervical ectopic pregnancy is difficult. Ultrasound criteria for diagnosing cervical pregnancy are presented in Table 1.^{3,4} With the advent of high-resolution transvaginal ultrasonography and Colour Doppler imaging, early and accurate diagnosis of CEP has become feasible.

However, the prevalence of ectopic pregnancy has increased with assisted reproductive technologies.⁵ It should be noted that cervical pregnancy is very dangerous

if not considered correctly. If left untreated, it can eventually lead to a hysterectomy. However, in most women, the risk factor is unknown.⁶

Table 1: Ultrasound criteria of cervical pregnancy.

1	Observation of pregnancy sac in the cervix
2	Heart movements should be detected below the surface of the internal OS
3	Absence of intrauterine pregnancy
4	Observing the uterus in the form of an hourglass with an enlarged cervix
5	No movements of the pregnancy sac due to the pressure of the vaginal probe (i.e., no sliding sign, which is usually seen in incomplete abortion)

CASE REPORT

This case report documents the diagnostic evaluation, clinical decision-making, conservative treatment strategy and outcome of a live cervical ectopic pregnancy. Clinical findings, laboratory parameters, imaging results, and procedural details were recorded prospectively during hospitalization. Diagnosis was established based on transvaginal ultrasonography and Colour Doppler imaging, supported by serum β -hCG measurements. Treatment included systemic methotrexate, ultrasound-guided intra-gestational sac methotrexate and potassium chloride injection, with meticulous follow up. The patient was counselled regarding treatment options, risk of hemorrhage, need for escalation to surgical management, and future fertility considerations. Informed consent was obtained.

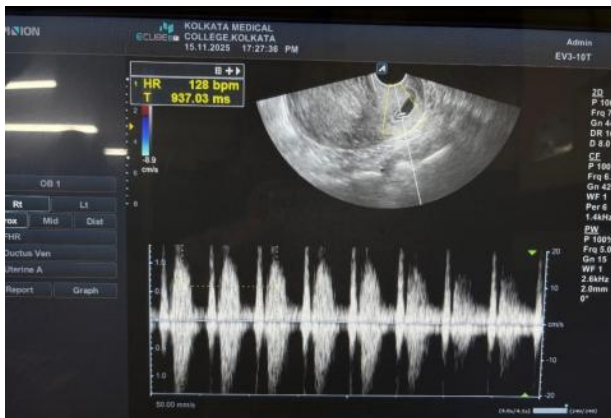


Figure 1: Cervical ectopic pregnancy.

A 24-year-old woman presented on with 7 weeks of amenorrhea and a positive serum β -hCG test. Conception was spontaneous, and there was no history of cervicouterine instrumentation or assisted reproductive techniques. On admission, the patient was hemodynamically stable. On admission Baseline laboratory investigation revealed haemoglobin of 11.3 g/dl, total leukocyte count of 8,890/mm³, platelet count of 2.7 lakh/mm³, and Serum β -hCG level was 5,801 mIU/ml.

Transvaginal ultrasonography demonstrated an empty uterine cavity with a well-defined gestational sac eccentrically located within the endocervical canal. A yolk sac and fetal pole with cardiac activity were visualized, and in Colour Doppler, prominent peri trophoblastic vascularity.

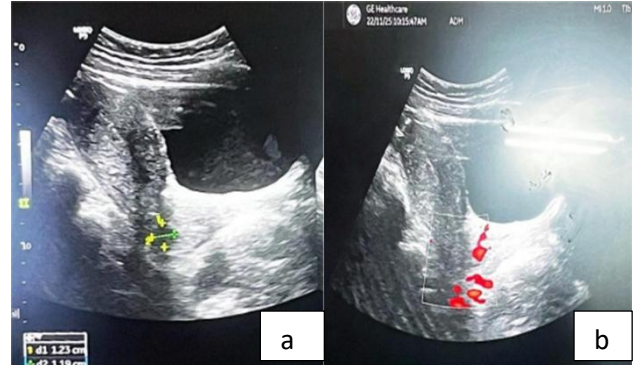


Figure 2 (a and b): TVS examination.

The internal os was closed. Crown-rump length measured 8.4 mm, confirming a diagnosis of 6 weeks 5 days live cervical ectopic pregnancy (Figure 1). Given the patient's stable condition and desire for fertility preservation, conservative management was planned. Intramuscular methotrexate 50 mg was administered. After 3days serum β -hCG increased to 7,004 mIU/ml. On that day, a 20-cm Chiba needle was introduced transvaginal (ultrasound guided), and approximately 1.3 cc of amniotic fluid was aspirated and 2 cc of a solution containing 15% potassium chloride and 25 mg methotrexate was injected into the gestational sac. After 6 days of intrasac injection, slight self-controlled painless vaginal bleeding noted for a short period of time, on TVS examination a residual 1.5 cc collection within the endocervical canal with reduced chorionic tissue volume and minimum perichorionic vascularity (Figure 2), serum β -hCG declined to 887 mIU/ml. No further interventions done. Patient was planned for discharge on next 7days, having with 1.2cm x1cm residual product of conception, and 59 mIU/ml serum β HCG level without any vaginal discharge.

DISCUSSION

Ultrasound has been described as helpful in differentiating a true cervical pregnancy from developing spontaneous abortion. Ultrasound criteria for diagnosing cervical pregnancy are presented in Table 1.^{3,4} Treatment for cervical ectopic pregnancies includes medical treatment with methotrexate and surgical treatment. The best treatment regimen for medical treatment has not yet been determined, but evidence suggests that single dose or multidose regimens of methotrexate have been successful in some cases. In more advanced gestational age with embryonal cardiac activity, may require a combination of multidose methotrexate and intra amniotic/intrafetal injection of potassium chloride.^{7,8} Recently, the

recommended protocol for the treatment of cervical ectopic pregnancy is fertility preservation rather than invasive surgery and hysterectomy.⁴ One recent case report described a case of cervical pregnancy that was managed with the intramuscular administration of methotrexate and intra amniotic sac injection of KCL without need for additional interventional treatment.⁹ In the current study we had applied same principles and success achieved without any surgical procedure. This case highlights the importance of individualized, multimodal management of live cervical ectopic pregnancy. Early diagnosis, close monitoring of β -hCG trends, judicious use of local and systemic medical therapy, and timely surgical intervention when indicated can result in successful outcomes while preserving future fertility.

CONCLUSION

Cervical ectopic pregnancy is a rare but potentially life-threatening condition that requires a high index of suspicion for early diagnosis. Advances in transvaginal ultrasonography and Colour Doppler imaging enable timely identification, allowing for conservative, fertility-preserving management in hemodynamically stable patients. This case demonstrates that a stepwise, combining systemic methotrexate followed by ultrasound-guided intra-gestational sac methotrexate with potassium chloride can be effective in managing live cervical ectopic pregnancy while minimizing the risk of catastrophic hemorrhage and avoiding hysterectomy. Close monitoring of serum β -hCG trends and imaging findings is key for successful conservative management. However individualized treatment planning and meticulous watchful expectancy remain critical to achieving optimal outcomes.

ACKNOWLEDGEMENTS

Authors would like to express their gratitude to their junior doctors for their valuable contributions throughout the procedure. Appreciation is also extended to all other members who were involved in this work.

Funding: No funding sources

Conflict of interest: None declared

Ethical approval: Not required

REFERENCES

1. Hoffman BL, Schorge JO, Schaffer JI, Haivorson LM, Bradshaw KD, Cunningham Williams, et al. *Gynaecology.* USA: Mc-Graw Hill Medical. 2012;198-213.
2. Ushakov FB, Elchalal U, Aceman PJ, Scheneker JG. Cervical pregnancy : past and future. *Obstet Gynecol Surv.* 1997;52(1):45-9.
3. Samal SK, Rathod S. Cervical ectopic pregnancy. *J Nat Sci Biol Med.* 2015;6(1):257.
4. Chrestiana D, Chfng AB, Panebianco NL, Dean AJ. Pitfalls in cervical ectopic pregnancy diagnosis by emergency physicians using bedside ultrasonography. *Am J Emerg Med.* 2014;32(4):397.
5. Binachi P, Salvatori MM, Torcia F, Cozza G, Mossa B. Cervical pregnancy. *Fertil Steril.* 2011;95(6):2123.
6. Surampudi K. A case of cervical ectopic pregnancy: successful therapy with methotrexate. *J Obstet Gynecol India.* 2012;62(1):1-3.
7. Leeman LM, Wendland CL. Cervical ectopic pregnancy: diagnosis with endovaginal ultrasound examination and successful treatment with methotrexate. *Arch Fam Med.* 2000;9:72-7.
8. Sijanovic S, Vidosavljevic D, Topolovec, Milostic-Srb A, Mrcela M. Management of cervical ectopic pregnancy after unsuccessful methotrexate treatment. *Iran J Reprod Med.* 2014;12(4):285-8.
9. Javedani Masroor M, Zarei A, Sheibani H. Conservative management of cervical pregnancy with the administration of methotrexate and potassium chloride: A case report. *Gynecol.* 2022;2022:1352868.

Cite this article as: Mandal J, Muktan S, Murmu H, Kumari J. Successful conservative management of a live asymptomatic cervical ectopic pregnancy: a case report. *Int J Reprod Contracept Obstet Gynecol* 2026;15:1840-2.