

DOI: <https://dx.doi.org/10.18203/2320-1770.ijrcog20261650>

Case Report

A silent breach, a collapsing bowel: deadly convergence of uterine perforation and gut ischemia

Rucha Bendale*, Pranita Bankar, Kausha Shah

Department of Obstetrics and Gynecology, BDBA Hospital, Mumbai, Maharashtra, India

Received: 24 April 2026

Accepted: 18 May 2026

*Correspondence:

Dr. Rucha Bendale,

E-mail: ruchadbendale@gmail.com

Copyright: © the author(s), publisher and licensee Medip Academy. This is an open-access article distributed under the terms of the Creative Commons Attribution Non-Commercial License, which permits unrestricted non-commercial use, distribution, and reproduction in any medium, provided the original work is properly cited.

ABSTRACT

An unusual presentation of postmenopausal women presenting as acute abdominal case with obstipation for 1 day with picture of sepsis. On further evaluation X Ray abdomen indicated air under diaphragm and provisional diagnosis of intestinal perforation was made. Patient underwent exploratory laparotomy for the same and intraoperatively it turned out to be relatively uncommon a case of non-traumatic spontaneous uterine perforation in a non-gravid uterus along with small bowel gangrene. This report highlights the diagnostic challenges and management considerations.

Keywords: Perforation, Uterus, Exploratory laparotomy, Emergency, Rheumatoid arthritis, Vasculitis

INTRODUCTION

Pregnancy, labor, and iatrogenic factors like dilatation and curettage are frequently linked to uterine perforation. It is exceptionally rare for a non-gravid uterus to perforate spontaneously in the absence of trauma or recent instrumentation. The majority of documented occurrences involve postmenopausal women and are frequently linked to underlying uterine pathology, such as cancer, infection, or degenerative alterations. Diagnosis is sometimes delayed due to vague clinical characteristics, which increases morbidity. We describe a rare instance of an intraoperatively identified non-traumatic spontaneous uterine perforation in a non-gravid uterus with bowel ischemia.

CASE REPORT

A postmenopausal woman of 64 years age presented to the emergency department with acute onset lower abdominal pain in the last 1 day and history of fever. The pain was severe, progressive and associated with multiple episodes of bilious vomiting. The patient had not passed stools and

flatus for 2 days. Her obstetric history was one abortion followed by dilation and curettage 12 years back, uneventful with no live child till date. Patient was known case of diabetes mellitus, not compliant to treatment with latest RBS being 280 mg/dl and HbA1c- 10.7. She also had long standing Rheumatoid arthritis and was on medications for the same-Tofacitinib 5 mg BD, Hydrocortisone 5 mg OD, methotrexate twice on saturday and once on sunday.

Clinical findings

On admission, vitals were as follows 116 bpm pulse low volume, BP 90/60 mm Hg, SpO2 95% on RA. HGT was done 246 mg/dl. Abdominal examination revealed distension with generalized tenderness with guarding and rigidity, suggestive of peritonitis.

Laboratory investigations revealed leukocytosis with deranged blood sugar levels. The complete blood count (CBC) showed hemoglobin of 9 g/dl, total leukocyte count (TLC) of 21,000/mm³, and platelet count of 145,000/mm³. The prothrombin time/international normalized ratio

(PT/INR) was 14.2 seconds/1.2, and random blood sugar (RBS) was 260 mg/dl. Liver and renal function tests showed total bilirubin of 0.9 mg/dl and serum creatinine of 1.4 mg/dl. Serum electrolytes revealed sodium of 135.9 mmol/l, potassium of 4.4 mmol/l, and chloride of 83.7 mmol/l. An X-ray of the abdomen in the erect position showed air under the diaphragm, suggestive of pneumoperitoneum. Based on these findings, a diagnosis of gastrointestinal perforation with peritonitis was made, and the patient was admitted under the surgical department for further management.

Therapeutic intervention

Given the clinical presentation of acute abdomen with sepsis, the patient was taken for emergency exploratory laparotomy under general anesthesia. Intraoperatively, purulent foul-smelling fluid about 1000 ml was noted in the peritoneal cavity.

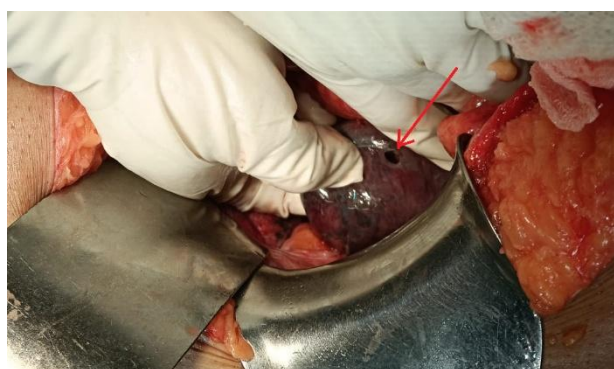


Figure 1: Intraoperative picture showing uterine perforation at fundus (red arrow).

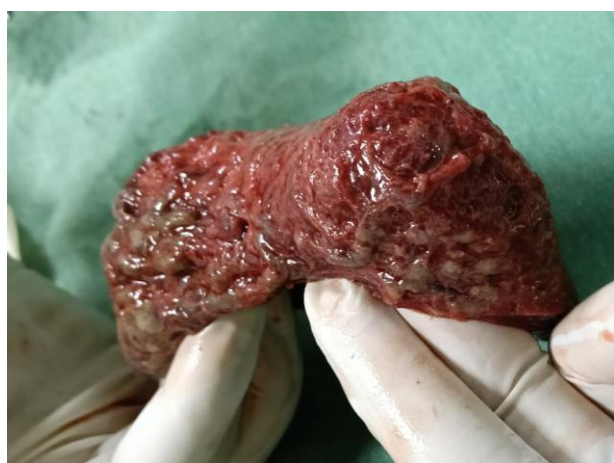

Figure 2: Uterine cavity opened uterus specimen.

Bowel gangrene of 20 cm noted, 100 cm from ileocecal junction. No bowel or other visceral perforation was found. A perforation was identified at the uterine fundus of about 5 mm, with surrounding necrotic and friable tissue. The uterus was non-gravid and atrophic. No foreign body was noted. Considering the patient's postmenopausal

status and extensive infection, a total abdominal hysterectomy was performed along with bowel resection of gangrenous area and stoma was created. Broad-spectrum intravenous antibiotics were administered perioperatively.

Follow-up and outcomes

The postoperative course: Unfortunately, the patient went into multi-organ dysfunction and could not recover from shock, and died on the 1st postoperative day. Pus culture shows the growth of *Escherichia Coli*. Histopathological examination confirmed suppurative inflammation and transmural necrosis affecting the endometrium, myometrium, serosa with no evidence of malignancy. perforation site of 5 mm seen on gross examination at fundus. On bowel examination, bowel gangrene was noted.

DISCUSSION

Pneumoperitoneum due to perforation of gangrenous uterus is rare and usual causes include hollow viscus perforation, trauma, infection, bowel cancer, necrotizing enterococci, post-surgical complications. Pyometra is the collection of purulent material in the uterus.¹ Diffuse peritonitis, a rare consequence (0.01-0.05%), can result from spontaneous uterine perforation caused by pyometra with associated uterine wall necrosis. In postmenopausal women, its frequency reaches 13.6%.^{1,2} The classical triad includes suprapubic pain, postmenopausal bleeding, and vaginal pus discharge.³ However, more than 50% of all cases are asymptomatic.³⁻⁵ Causes of pyometra are neoplasm, cervical stenosis (secondary to radiation fibrosis, surgery, malignancy, age related atrophy), gross congenital anatomic abnormalities, age related endometritis, infective endometritis and retained intrauterine device or foreign body.⁶ Comorbidities that have been associated with rupture include uncontrolled diabetes mellitus, underlying faecal or urinary incontinence, obesity, malnutrition, immunocompromised state, sexual activity, genital atrophy. The most common organisms in pyometra are flora from genitourinary tract like *Escherichia coli*, *Bacteroides*, *Streptococcus*, and other anaerobes.⁷

Rheumatoid arthritis (RA) is a chronic autoimmune inflammatory disease characterized by inflammation of the synovial joints, primarily the small joints of the hands and feet. As a systemic disease, it has the potential to affect almost all organs and systems of the body, giving rise to numerous extra-articular manifestations. These manifestations have been found to be associated with high titers of anti-cyclic citrullinated peptide (anti-CCP) and rheumatoid factor (RF).^{8,9} Rheumatoid vasculitis (RV) is a rare and one of the most threatening extra-articular manifestations of RA, leading to several cutaneous and systemic features. Its incidence is found to be below 1% per year.¹⁰ The mean duration between RA diagnosis and vasculitis development is 10-14 years. Very rarely it

develops during the first five years of RA diagnosis.¹¹ It is characterized by tissue damage or ischemia and is pathologically correlated with mononuclear or neutrophilic infiltration of the vessel wall, leading to vasculitis and primarily afflicting small- to medium-sized vessels.¹² It has been found that the mortality rate within five years of the development of RV can be as high as 40%.¹³

However, its incidence has considerably decreased in recent times, probably owing to the introduction of biological disease-modifying anti-rheumatic drugs (DMARDs).¹⁰ Small bowel findings in patients with RA may manifest as inflammatory changes which could result in blood and protein loss, ulcerations, strictures, ischemia and perforation.

The cecum and the right colon are the common sites of colon ulcerations which may complicate with a bleeding or perforations.¹⁴ RV is an uncommon complication of RA and can happen in 1% of the patients. Among RA patients with associated vasculitis, 20% of them may develop intestinal involvement. Patients at risk of RA vasculitis are those with long-standing erosive arthritis, positive rheumatoid factor with a high titre, and the presence of subcutaneous nodules.¹⁵

Surprisingly, RA vasculitis may occur in patients with inactive joint disease. Furthermore, it can complicate with GI bleeding, ulcerations, bowel perforations, and small and large intestine infarctions.¹⁴

The prognosis in such patients is commonly poor, and the consequences may be fatal. In our case patient was obese and did have history with uncontrolled diabetes with immunocompromised status with recent history of sexual intercourse. Preoperative diagnosis remains challenging due to nonspecific symptoms and overlapping features with gastrointestinal emergencies. In many reported cases, the diagnosis is made intraoperatively due to nonspecific clinical and radiological findings, as in the present case. Early surgical intervention is essential to prevent fatal complications such as generalized peritonitis and septic shock.

CONCLUSION

Surgeons have to be aware of many aetiologies of peritonitis and cautious before labelling pneumoperitoneum on imaging as only due to hollow viscus perforation especially, in a female patient with acute generalized peritonitis. Detailed history goes a long way in helping diagnose the condition even with the availability of modern diagnostic radiological investigations which may mislead clinicians as evident in our case. Although rare, spontaneous uterine perforation should be considered in the differential diagnosis of acute abdomen in postmenopausal women. A high index of suspicion, prompt imaging, and early surgical management are crucial for favorable outcomes.

Funding: No funding sources

Conflict of interest: None declared

Ethical approval: Not required

REFERENCES

1. Browne IL. Spontaneous perforation of pyometra—is hysterectomy required in the emergent setting? A case report and literature review. *J Surg Case Rep.* 2022;2022:rjac388.
2. Yildizhan B, Uyar E, Şişmanoğlu A, Güllüoğlu G, Kavak ZN. Spontaneous perforation of pyometra. *Infect Dis Obstet Gynecol.* 2006;2006:26786.
3. İşlek Seçen E, Ağış H, Altunkaya C, Avşar AF. Postmenopausal spontaneous uterine perforation: a case report. *Turk J Obstet Gynecol.* 2015;12(2):122-4.
4. Nuamah NM, Hamaloglu E, Konan A. Spontaneous uterine perforation due to pyometra presenting as acute abdomen. *Int J Gynecol Obstet.* 2006;92(2):145-7.
5. Kitai T, Okuno K, Ugaki H, Komoto Y, Fujimi S, Takemura M. Spontaneous uterine perforation of pyometra presenting as acute abdomen. *Case Rep Obstet Gynecol.* 2014;2014:738568.
6. Yousefi Z, Sharifi N, Morshedy M. Spontaneous uterine perforation caused by pyometra: a case report. *Iran Red Crescent Med J.* 2014;16(11):e14491.
7. Gupta N, Rawat S, Verma N, Parineeta, Kumar R. Spontaneous uterine perforation presenting as acute abdomen: a diagnostic challenge. *Int Surg J.* 2023;10(4):1099-102.
8. McInnes IB, Schett G. The pathogenesis of rheumatoid arthritis. *N Engl J Med.* 2011;365:2205-19.
9. Mongan ES, Cass RM, Jacox RF, Vaughen JH. A study of the relation of seronegative and seropositive rheumatoid arthritis to each other and to necrotizing vasculitis. *Am J Med.* 1969;47:23-35.
10. Sayah A, English JC. Rheumatoid arthritis: a review of the cutaneous manifestations. *J Am Acad Dermatol.* 2005;53:191-209.
11. Genta MS, Genta RM, Gabay C. Systemic rheumatoid vasculitis: a review. *Semin Arthritis Rheum.* 2006;36:88-98.
12. Taha ZI, Abdalla YA, Hamza SB, Eltagalawi MF, Abubakr ME, William J, et al. Rheumatoid vasculitis, an uncommon complication of non-deforming rheumatoid arthritis: a case report. *Open Access Rheumatol.* 2022;14:141-6.
13. Radic M, Martinovic Kaliterna D, Radic J. Overview of vasculitis and vasculopathy in rheumatoid arthritis—something to think about. *Clin Rheumatol.* 2013;32:937-42.
14. Schneider A, Merikhi A, Frank BB. Autoimmune disorders: gastrointestinal manifestations and endoscopic findings. *Gastrointest Endosc Clin N Am.* 2006;16(1):133-51.

15. Halabi H, AlDabbagh A, Alamoudi A. Gastrointestinal manifestations of rheumatic diseases. *Skills in Rheumatology*. Singapore: Springer. 2021.

Cite this article as: Bendale R, Bankar P, Shah K. A silent breach, a collapsing bowel: deadly convergence of uterine perforation and gut ischemia. *Int J Reprod Contracept Obstet Gynecol* 2026;15:2282-5.