

DOI: <http://dx.doi.org/10.18203/2320-1770.ijrcog20170401>

Original Research Article

A study to correlate histopathological findings in patients with abnormal uterine bleeding

Mansi Shukla*, Michelle N Fonseca, Deepali Kharat, Pallavi Tekale

Department of Obstetrics and Gynecology, Lokmanya Tilak Municipal Medical College, Mumbai, Maharashtra, India

Received: 07 December 2016

Revised: 09 December 2016

Accepted: 31 December 2016

***Correspondence:**

Dr. Mansi Shukla,

E-mail: mansi31in@gmail.com

Copyright: © the author(s), publisher and licensee Medip Academy. This is an open-access article distributed under the terms of the Creative Commons Attribution Non-Commercial License, which permits unrestricted non-commercial use, distribution, and reproduction in any medium, provided the original work is properly cited.

ABSTRACT

Background: Abnormal uterine bleeding (AUB) is a common gynecological problem associated with considerable morbidity and significantly affects the patients. The aim of the study was to analyze the histopathological patterns of endometrium in patients presenting with AUB and also to determine the incidence of AUB in various age groups.

Methods: This is a retrospective study, conducted in the Department of Obstetrics and Gynaecology, in a tertiary care teaching hospital, Mumbai, India from March 2016 till date. All cases of AUB were included in the study. Data was entered in microsoft excel and managed in statistical package for the social sciences (SPSS) version 16. Analysis was done in the form of percentages and proportions and represented as tables where necessary.

Results: A total of 120 cases were analyzed. Patients' age ranged from 22-79 years. AUB was most common among the perimenopausal females (41-50years). The most common presenting symptom was heavy menstrual bleeding (53%). Dilatation and curettage (D&C) was performed in all cases and 96 underwent hysterectomy as final resort. Endometrial proliferative pattern was the most common histopathological finding and was seen in 27% patients, followed by endometrial hyperplasia in 13.5% patients, secretory endometrium (12.7%) and disordered proliferative endometrium were seen in 10.9% patients each. Malignancy was detected in 1.7% of cases and endometrial carcinoma was the most common lesion.

Conclusions: Endometrial sampling is especially indicated in women above the age of 35 years to rule out malignancy and preneoplasia. Among the females with no organic pathology, normal physiological patterns with proliferative, secretory, and menstrual changes were observed. The most common endometrial pathology in this study was endometrial proliferation.

Keywords: Abnormal uterine bleeding, Endometrial hyperplasia, Histopathology, Menorrhagia

INTRODUCTION

Abnormal uterine bleeding (AUB) is defined as any change in the frequency of menstruation, duration of flow or amount of blood loss.¹ AUB is a common problem encountered by women of all age groups, responsible for around 20-30% visits to out-patient department in reproductive age group and 69% in peri or postmenopausal age group.² The International Federation of Gynaecology and Obstetrics working group on menstrual disorders has developed a classification

system-PALM COEIN for causes of AUB in non-pregnant women of reproductive age.³ The classification system is divided into nine categories that are arranged according to the acronym PALM-COEIN: Polyp, Adenomyosis, Leiomyoma, Malignancy and hyperplasia, Coagulopathy, Ovulatory disorders, Endometrial, Iatrogenic, and Not Classified.

The most common clinical manifestations are menorrhagia, polymenorrhoea, metrorrhagia, and intermenstrual bleeding. The new terminologies approved by

FIGO are: a) Heavy menstrual bleeding (HMB) should replace menorrhagia to describe excess of bleeding, b) Inter menstrual bleeding (IMB) that occurs between clearly defined cyclic and predictable menses should replace the term metrorrhagia, c) Heavy and prolonged bleeding (HPB) should replace menometrorrhagia and d) frequent menstrual bleeding should replace polymenorrhoea.⁴

Dilatation and curettage (D&C) is the mainstay of endometrial sampling since long.⁵ Nowadays, it is performed under hysteroscopic guidance, which allows for therapeutic intervention. D&C also allows for a fractional curettage with separate sampling of endometrial and endocervical tissue. Transvaginal/transabdominal ultrasound is another useful technique for examining the endometrium and evaluating AUB.⁶

Abnormal uterine bleeding is initially managed medically. A number of minimally invasive surgical alternatives for hysterectomy do exist now, such as endometrial ablation, thermal balloon therapy and uterine artery embolization.⁷ These are promising techniques but restricted availability and cost limit them from being used widely. Therefore, hysterectomy still remains the widely accepted and practiced treatment.^{8,9}

METHODS

Study Setting

Obstetrics and Gynecology Department, Tertiary Care Hospital, Mumbai, India.

Population

Females suffering from abnormal uterine bleeding.

Study Period

From March 2016 till date.

A total of 120 cases were analysed. Patients' age ranged from 22-79 years. The study included all women with abnormal uterine bleeding. Data was recorded on proforma, including demographic characteristics and clinical features. The histopathologic findings were analysed so as to find out the proportion of various causes of AUB in accordance to the classification system PALM-COEIN proposed by FIGO. Data was entered in microsoft excel 2010 for graphical representation and managed in statistical package for the social sciences (SPSS) version 17. Analysis was done in the form of percentages and proportions and represented as tables where necessary.

RESULTS

This was a study of a random selection of women from the gynaecological OPD in Lokmanya Tilak Municipal

Medical College and Hospital who came with the complaints of abnormal uterine bleeding. A total of 120 AUB patients were studied from March 2016 till date. Patients' age ranged from 22-79 years.

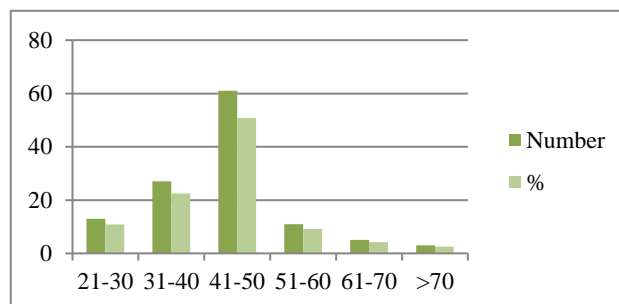


Figure 1: Age-wise distribution of patients with abnormal uterine bleeding (n=120).

The patients underwent ultrasonography and endometrial biopsy with all necessary investigations and after evaluation, it was found that the most common clinical presentation was heavy menstrual bleeding (53%) followed by intermittent menstrual bleeding. AUB was most common among the perimenopausal females. The maximum incidence of AUB seen in patients in perimenopausal age group i.e. 41-50 years of age and those who were multiparous.

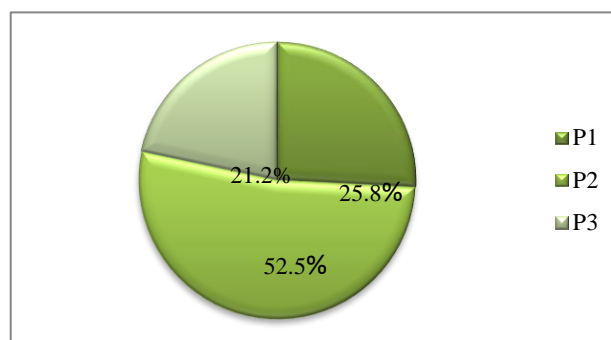


Figure 2: Parity of patients with AUB (n=120).

Dilatation and curettage (D&C) was performed in all cases and 96 underwent hysterectomy as final resort. Histopathological examination of endometrial biopsies in patients of abnormal uterine bleeding shows a wide spectrum of changes ranging from normal endometrium in various hormonal cycles to malignancy. In present study, the most frequent finding seen in patients with AUB in the reproductive age group was proliferative phase. In peri and post-menopausal women simple hyperplasia without atypia was most frequently noted. Endometrial proliferative pattern was the most common histopathological finding and was seen in 27% patients, followed by endometrial hyperplasia in 13.5% patients, secretory endometrium (12.7%) and disordered proliferative endometrium were seen in 10.9% patients each. Further on post-operative histopathology of specimens, it was found that the prevalence of chronic

cervicitis was 44.2%, leiomyoma was 19.2%, adenomyosis 15% whereas endometrial/endocervical polyp account for 10.8% of AUB. Malignancy was detected in 1.7% of cases and endometrial carcinoma was the most common lesion.

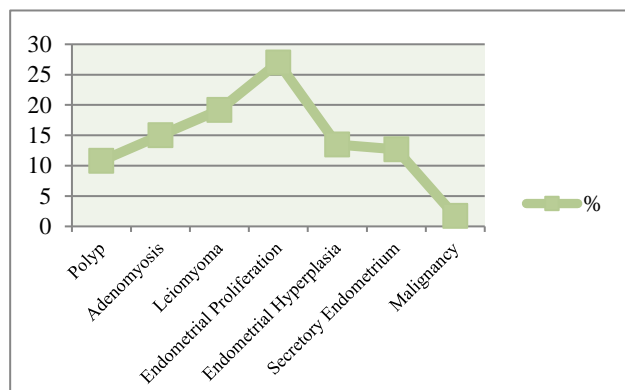


Figure 3: Spectrum of histopathological diagnosis.

DISCUSSION

A study of 120 patients with abnormal uterine bleeding was carried out from March 2016 till date in Lokmanya Tilak Medical College & Hospital, Mumbai, India. Outcome of the clinical and histopathological findings are as follows:

1. Patients belonging to various age groups were taken up for the study. The maximum incidence of AUB was in the 41-50 years' age group. The minimum incidence of AUB was in 21-30 years.
2. With respect to parity of subjects, maximum incidence of abnormal uterine bleeding was seen in the parity of 1-3 and minimum incidence in nulliparous women.
3. The most common type of bleeding pattern observed was Heavy menstrual bleeding followed by intermenstrual bleeding in patients.
4. The role for pelvic ultrasound in the diagnosis of structural abnormalities is very important. However, in present study, it was found that there were no pathognomonic sonographic features that correlate completely with histology, so comprehensive tissue examination remains the gold standard.
5. The most common finding in the reproductive age group was proliferative endometrium whereas simple hyperplasia without atypia was predominant finding in perimenopausal age group. Atrophic endometrium was mostly found in postmenopausal women.
6. In the present study, the two important observations were made regarding endometrial hyperplasia in AUB and they are: a) Endometrial hyperplasia was highest in

the age group of 41-50 years, b) it was highest in patients with history of heavy menstrual bleeding.

AUB can be assessed by duration and timing of flow, haemoglobin or hematocrit, serum progesterone levels, evaluation of the uterus on ultrasound testing, screening transvaginal ultrasound test of the endometrial cavity and evaluation for coagulopathies with the use of structured history as screening.^{10,11} In LTMGH, patients with abnormal uterine bleeding were examined clinically and underwent ultrasonography and endometrial biopsy. Majority of patients have multiple pathology such as leiomyoma, adenomyosis and ovulatory disorders with predominating proliferative phase in histopathology. In India, low cost investigations and treatment should be considered for the benefit of the patients. Hence, ultrasound and endometrial biopsy still remains as gold standard.

CONCLUSION

Endometrium is the mirror of hormonal status in women. Histological variations can be seen in the endometrium according to age of women and phase of her menstrual cycle and any other specific pathology. With regards to diagnosis of AUB, pelvic ultrasound is the least invasive procedure used for visualization of the structure of the uterus and for visualization of the thickness of endometrium. In certain cases, it provides additional information that may assist both diagnosis and treatment choices.

Whereas endometrial sampling could be effectively used as the first diagnostic step in abnormal uterine bleeding although, at times its interpretation could be quite challenging to the practicing pathologist. It is a simple, cost-effective and appropriate method that provides accurate diagnostic yield. The present study highlights the importance of endometrial biopsy and its interpretation which plays a pivotal role in the management of AUB. So, the ultrasonography and endometrial biopsy still remain the gold standard for diagnosis of AUB.

Funding: No funding sources

Conflict of interest: None declared

Ethical approval: The study was approved by the Institutional Ethics Committee

REFERENCES

1. Practice bulletin number 128: diagnosis of abnormal uterine bleeding in reproductive-aged women. *Obstet Gynecol.* 2012;120(1):197-206.
2. American College of Obstetricians and Gynecologists. Management of anovulatory bleeding. ACOG Practice Bulletin No. 14. Washington, DC: ACOG: 2000.
3. Munro MG, Critchley HO, Broder MS, Fraser IS, for the FIGO Working Group on Menstrual Disorders.

- FIGO classification system (PALM-COEIN) for causes of abnormal uterine bleeding in nongravid women of reproductive age. *Int J Gynecol Obstet.* 2011;113(1):3-13.
4. Munro MG, Critchley HO, Fraser IS. The FIGO systems for nomenclature and classification of causes of abnormal uterine bleeding in the reproductive years: who needs them? *Am J Obstet Gynecol.* 2012;207(4):259-65.
 5. Kelekci S, Kaya E, Alan M, Alan Y, Bilge U, Mollamahmutoglu L. Comparison of transvaginal sonography, saline infusion sonography, and office hysteroscopy in reproductive-aged women with or without abnormal uterine bleeding. *Fertil Steril.* 2005;84(3):682-6.
 6. Guido RS, Shakir AK, Rulin MC, Christopherson WA. Pipelle endometrial sampling. Sensitivity in the detection of endometrial cancer. *J Reprod Med.* 1995;40(8):553-5.
 7. National Collaborating Centre for Women's and Children's Health, National Institute of Clinical Excellence. Heavy menstrual bleeding. Clinical guideline. London: RCOG Press; 2007.
 8. DeVore GR, Owens O, Kase N. Use of intravenous Premarin in the treatment of dysfunctional uterine bleeding-a double-blind randomized control study. *Obstet Gynecol.* 1982;59:285-91.
 9. Munro MG, Mainor N, Basu R, Brisinger M, Barreda L. Oral medroxyprogesterone acetate and combination oral contraceptives for acute uterine bleeding: a randomized controlled trial. *Obstet Gynecol.* 2006;108:924-9.
 10. James AH, Kouides PA, Abdul-Kadir R, Dietrich JE, Edlund M, Federici AB, et al. Evaluation and management of acute menorrhagia in women with and without underlying bleeding disorders: consensus from an international expert panel. *Eur J Obstet Gynecol Reprod Biol.* 2011;158(2):124-34.

Cite this article as: Shukla M, Fonseca MN, Kharat D, Tekale P. A study to correlate histopathological findings in patients with abnormal uterine bleeding. *Int J Reprod Contracept Obstet Gynecol* 2017;6:654-7.