International Journal of Reproduction, Contraception, Obstetrics and Gynecology
*Sharma A et al. Int J Reprod Contracept Obstet Gynecol. 2026 Dec;15(12):4900-4906*
www.ijrcog.org
pISSN 2320-1770 | eISSN 2320-1789

DOI: https://dx.doi.org/10.18203/2320-1770.ijrcog20264405

**Original Research Article**

# Correlation of optic nerve sheath diameter in raised intracranial pressure in pre-eclampsia: a prospective observational study in preeclampsia in a low resource setting

**Aashima Sharma[1], Nidhi Jindal[1]*, Rama Thakur[1], Rohit Bhoil[2]**

[1]Department of Obstetrics and Gynecology, Indira Gandhi Medical College, Shimla, Himachal Pradesh, India
[2]Department of Radiodiagnosis, Indira Gandhi Medical College, Shimla, Himachal Pradesh, India

**Received:** 27 September 2026
**Accepted:** 02 November 2026

***Correspondence:**
Dr. Nidhi Jindal,
E-mail: docnidhi20@gmail.com

**Copyright:** © the author(s), publisher and licensee Medip Academy. This is an open-access article distributed under the terms of the Creative Commons Attribution Non-Commercial License, which permits unrestricted non-commercial use, distribution, and reproduction in any medium, provided the original work is properly cited.

## ABSTRACT

**Background:** The study aimed to measure and compare optic nerve sheath diameter (ONSD) among women diagnosed with pre-eclampsia and normotensive pregnant controls.
**Methods:** A total of 120 patients were enrolled in this prospective study and assigned to two groups. There were 61 patients in the group A (Pre-eclampsia group) and 59 in group B (normotensive). Outcome was evaluated using Optic nerve sheath diameter measurements and to see whether there was statistically significant difference in both the groups. Sensitivity for the diagnostic test was measured in comparison to standard method of fundoscopy.
**Results:** The baseline demographics in the two groups were comparable. Mean Optic nerve sheath diameter was significantly higher in Group A indicating high intracranial pressure in women with pre-eclampsia. There was significant reduction in mean Optic nerve sheath diameter post treatment in Group A($p<0.001$). Similarly, the sensitivity of fundoscopy as compared to ONSD measurement to detect raised intracranial pressure was found to be just 10%.
**Conclusion:** The results of the study suggest that measurement of ONSD is a bedside, minimally invasive procedure and avoids radiation exposure. It is particularly suitable in pregnancy, where imaging modalities such as CT or MRI may be limited due to logistical constraints or delayed access. Additionally, optic nerve ultrasonography can be repeated frequently for monitoring changes in intracranial pressure over time, making it valuable in dynamic clinical decision-making.

**Keywords:** Fundus examination, Optic nerve sheath diameter, Pre-eclampsia, Raised intracranial pressure, Optic ultrasonography

## INTRODUCTION

Preeclampsia is a hypertensive disorder unique to human pregnancy, characterized by the new onset of elevated blood pressure and proteinuria or other signs of maternal organ dysfunction after 20 weeks of gestation. It remains one of the leading causes of maternal and perinatal morbidity and mortality worldwide, particularly in low and middle-income countries.[1,2]

In preeclampsia, because of endothelial dysfunction and increased capillary permeability, fluid tends to accumulate in tissues, including the brain. Vasogenic edema and the resultant increase in intracranial pressure may occur even before the development of overt neurological symptoms. Because cerebral edema and raised intracranial pressure are central to severe manifestations of preeclampsia, assessing intracranial pressure becomes clinically meaningful for early diagnosis, monitoring, and management. However, direct measurement of intracranial pressure is invasive and requires neurosurgical expertise.

Therefore, non-invasive, reliable, and easily available bedside methods are highly desirable in obstetric practice. Ultrasonographic measurement of the optic nerve sheath diameter has emerged as a promising indirect screening tool for detecting elevated intracranial pressure.[3,4]

Detecting raised intracranial pressure at an early stage is crucial for preventing progression to eclampsia and avoiding catastrophic events such as stroke or cerebral herniation.[5]

The optic nerve is anatomically an extension of the central nervous system, covered by meninges similar to the brain, including the dura mater, arachnoid mater, and pia mater. The subarachnoid space surrounding the optic nerve is continuous with that of the brain. Thus, any increase in intracranial pressure is transmitted along the subarachnoid space, leading to distension of the optic nerve sheath. This makes optic nerve sheath diameter a dynamic marker that correlates with intracranial pressure changes. Normally, the optic nerve sheath has a standard diameter that varies slightly among individuals, but when intracranial pressure rises, the sheath expands measurably.

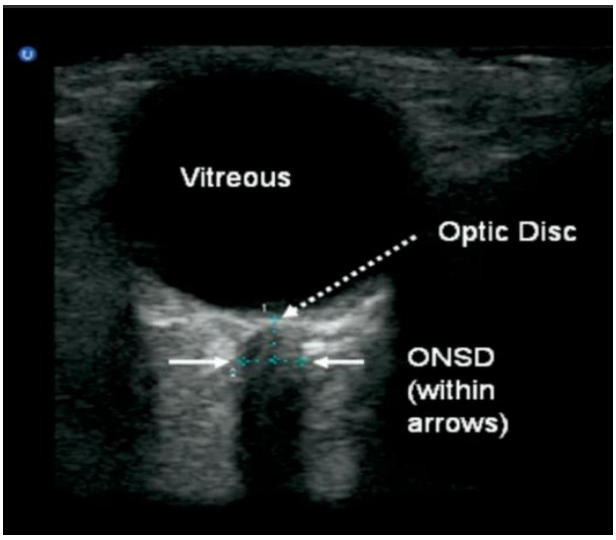


**Figure 1: Ultrasonic image showing optic nerve sheath diameter.**

Ultrasonography allows rapid, non-invasive visualization of the optic nerve sheath approximately 3 mm posterior to the globe, where diameter measurement is most sensitive to pressure changes.[4,5]The aim of this study was to evaluate preeclampsia and its relation with optic nerve sheath diameter.

### *Objectives*

The objective of this study was to measure and compare ONSD among women diagnosed with pre-eclampsia and normotensive pregnant controls, thereby determining if there is a statistically significant difference in ONSD between the two groups, to measure ONSD in pre-eclampsia group after treatment completion and to determine whether there was significant reduction in ONSD post treatment and also to compare detection rate by ONSD method vs traditional fundoscopy

## METHODS

This research was conducted in the department of Obstetrics & Gynecology in a leading tertiary care institute of North India. It was a prospective, observational, case-control study done over a duration of one year from January 2025 to January 2026.

### *Study design*

A consecutive sampling methodology was employed for participant recruitment. All eligible women who presented to the study setting and met the inclusion criteria for the pre-eclamptic group during the active nine-month recruitment phase were invited to participate in the study. This approach minimized selection bias and ensured that the study sample was representative of the pre-eclamptic population accessing this tertiary care facility. For every pre-eclamptic woman enrolled, one normotensive control participant was recruited and matched primarily based on gestational age to control for any potential physiological changes in ONSD across different stages of pregnancy.

The sample size calculation was performed a priori using data from a pilot study and referenced similar published studies, such as the work by Dubost et al, which reported a mean ONSD of 5.4 mm in pre-eclamptic women and 4.5 mm in controls.[6] Using these values to anticipate an effect size, and setting the statistical power at 80% with a two-sided alpha error of 0.05, a sample size calculation was performed using G*Power software. The calculation indicated that a minimum of 45 participants were required in each group to detect a statistically significant difference. To account for potential attrition, incomplete data, and to enhance the power for subgroup analyses (e.g., mild vs. severe pre-eclampsia), the sample size was inflated by approximately 10%. Therefore, the final target sample size was set at 120 participants, with 61 women allocated to the pre-eclamptic group (Group A) and 59 to the normotensive control group (Group B).

For the purpose of comparative analysis, the enrolled participants were divided into two distinct groups. Group A (Pre-Eclamptic Group) consisted of 61 pregnant women with a confirmed diagnosis of pre-eclampsia, as per the defined inclusion criteria. Group B (Control Group) consisted of 59 healthy, normotensive pregnant women with uncomplicated pregnancies, matched for gestational age with the participants in Group A.

### *Inclusion criteria for the pre-eclamptic group (Group A):*

The inclusion criteria included pregnant women aged 18 years or older, having a gestational age of 20 weeks or more and those having a confirmed diagnosis of pre-eclampsia, defined as a SBP of ≥140 mm Hg or DBP of

≥90 mm Hg on two occasions at least 4 hours apart, occurring after 20 weeks of gestation in a woman with previously normal blood pressure, accompanied by either proteinuria (≥300 mg in a 24-hour urine collection, or a protein/creatinine ratio of ≥0.3, or a dipstick reading of 1+) or, in the absence of proteinuria, new-onset hypertension with the involvement of other maternal organ systems such as thrombocytopenia, renal insufficiency, impaired liver function, pulmonary edema, or cerebral or visual symptoms.

***Inclusion criteria for the normotensive control group (Group B)***

This group included pregnant women aged 18 years or older, having gestational age matched to within two weeks of a recruited pre-eclamptic participant and those who were normotensive throughout the current pregnancy, with no history of hypertensive disorders or proteinuria.

***Exclusion criteria***

Exclusion criteria applied to both groups included patients with known pre-existing neurological disorders that could independently affect ICP or optic nerve anatomy, such as idiopathic intracranial hypertension, hydrocephalus, cerebral tumors, or a history of significant traumatic brain injury.

Significant pre-existing ophthalmic pathologies that could interfere with ultrasound acquisition or alter optic nerve sheath anatomy, including severe retinopathy (diabetic or hypertensive), glaucoma, optic neuritis, or a history of major ocular surgery.

Those who were unwillingness or inability to provide written informed consent**,** those having Multiple gestations as these pregnancies are associated with unique hemodynamic changes that could confound the relationship between pre-eclampsia and ONSD. Additionally, patients with significant facial trauma or orbital pathology that prevented the safe application of the ultrasound probe and those with known chronic hypertension predating the pregnancy were also excluded.

A comprehensive baseline assessment was performed, which included recording the participant's demographic details and obstetric history. Blood pressure was measured using a calibrated sphygmomanometer with the patient in a semi-recumbent position. A focused neurological assessment was conducted to document the presence or absence of headache, visual disturbances, hyperreflexia, or any other neurological signs.

After recruitment of patient, Ocular ultrasound was performed by a trained sonologist using a high-frequency linear array transducer of frequency 7-12 MHz (LogicQ, Siemens, Samsung V6). The sonologist was blinded to the participants to avoid observer bias. The participant was placed in a supine position with the head in a neutral position. The probe was placed gently on the gel-covered eyelid. The optic nerve was identified as a hypoechoic linear structure posterior to the globe. The sheath surrounding the nerve appeared as two hyperechoic lines. The measurement was taken in the transverse (axial) plane, 3 mm behind the posterior aspect of the globe, where the sheath is most compliant. The inner-to-inner edge distance between the two vertical hyperechoic lines (inner edge of the dura mater) was measured (Figure 1). Three separate measurements were taken for each eye, which were averaged to obtain a single mean ONSD value for each eye which was used for all subsequent analyses.

For pre-eclamptic participants who required ongoing inpatient management, a follow-up ONSD measurement was attempted 24 hours after the initiation of a significant therapeutic intervention, such as after a full course of magnesium sulfate for seizure prophylaxis or after blood pressure was stabilized with antihypertensive medications. This allowed for the observation of ONSD trends in response to treatment.

***Data analysis***

Data analysis was performed using the Statistical Package for the Social Sciences (SPSS) version 26.0. Descriptive statistics were first computed to summarize the characteristics of the study population. Continuous variables that were normally distributed were presented as mean and standard deviation (SD), while non-normally distributed data were presented as median and interquartile range (IQR). The primary comparative analysis involved testing the difference in mean ONSD between Group A (pre-eclamptic) and Group B (control) using an independent samples t-test, provided the data met assumptions of normality and homogeneity of variance; otherwise, the non-parametric Mann-Whitney U test was used. The Chi-square test or Fisher's exact test was used to compare categorical variables between the groups. To control for potential confounding factors such as maternal age, BMI, and gestational age, multiple linear regression analysis was performed with ONSD as the dependent variable. For the analysis of ONSD changes following intervention, a paired t-test (or Wilcoxon signed-rank test) was used to compare pre- and post-intervention values within the pre-eclamptic subgroup. A p-value of less than 0.05 was considered statistically significant for all tests.

## RESULTS

The baseline demographics and the clinical parameters of study population and comparison between the two groups have been depicted in Table1. The mean age of the study participants was 27.62±4.43 years, with an age range of 18 to 41 years. The difference in mean age between the two groups was not significant (p=0.46), indicating that the groups were comparable with respect to age. More than half of the participants were from rural areas (61.7%), while 38.3% were from urban areas. More than half of the participants were primiparous (54.2%), while 45.8% were

multiparous. The proportion of primiparous women was almost identical in both the pre-eclamptic (54.1%) and normotensive groups (54.2%). The mean body mass index (BMI) of the study participants was 27.11±4.41 kg/m². Women with pre-eclampsia had a significantly higher mean BMI (28.25±4.70 kg/m²) compared to normotensive women (25.92±3.76 kg/m²) (p<0.001).

**Table 1: Known chronic hypertension predating the pregnancy.**

| Parameter | Group A (n=61) | Group B (n=59) | Total(n=120) | P value* |
|---|---|---|---|---|
| **Age(years), mean (SD)** | 27.91(4.39) | 27.32(4.48) | 27.62(4.43) | 0.46 |
| **Parity, N** | | | | |
| Primiparous | 33 | 32 | 65 | 0.99 |
| multiparous | 28 | 27 | 55 | |
| **Residence (N)** | | | | |
| Urban | 27 | 19 | 46 | 0.17 |
| Rural | 34 | 40 | 74 | |
| BMI, mean (SD) | 28.25(4.70) | 25.92(3.76) | 27.11 | <0.001 |
| **Mode of delivery** | | | | |
| Vaginal delivery | 26 | 39 | 65 | 0.03 |
| Caesarean delivery | 35 | 20 | 55 | |

*Statistically significant.

Caesarean delivery was more common among pre-eclamptic women (57.4%) compared to normotensive women (33.9%) indicating increased induction rates and failure of induction in pre-eclampsia group.

Both the groups underwent ultrasonic guided optic nerve sheath diameter measurement at the time of admission. Cut off for ONSD in cases of raised ICP was kept 5.4 mm extrapolated from the pilot study done by Dubost et al.[6] The mean diameter in right and left eye in Group A was 5.80±0.43 and 5.76±0.39 which was statistically higher than the respective diameters in Group B (Table 2). All the women in Group A were given Magnesium sulfate therapy along with antihypertensives because of severe pre-eclampsia. The optic nerve sheath diameter measurement was repeated again in this group after completion of magnesium sulfate therapy or post-delivery whichever was earlier. Overall, a statistically significant reduction in optic nerve sheath diameter was observed following MgSO4 and labetalol therapy, suggesting improvement in neurological status among pre-eclamptic women with control of BP and seizure prophylaxis (Table 3).

**Table 2: Optic Nerve sheath diameter measurements in both groups.**

| Parameters | Group A(n=61) | Group B(n=59) | Total (n=120) | P value# |
|---|---|---|---|---|
| **Right eye ONSD (mm), Mean (SD)** | 5.80(0.43) | 4.85(0.27) | 5.33(0.60) | <0.001 |
| **Left eye ONSD (mm), Mean SD** | 5.76(0.39) | 4.88(0.30) | 5.33(0.56) | <0.001 |

# independent paired t-test

**Table 3: Comparison of pre- and post-therapy optic nerve sheath diameter among pre- eclamptic women (n=61).**

| Right Eye ONSD (mm) | Mean (SD) | Minimum | Maximum | P value* |
|---|---|---|---|---|
| Pre-Therapy Right Eye ONSD (mm) | 5.80 (0.43) | 3.8 | 6.3 | <0.001 |
| Post-Therapy Right Eye ONSD (mm) | 5.64 (0.45) | 3.8 | 6.2 | |
| **Left Eye ONSD (mm)** | | | | |
| Pre-Therapy Left Eye ONSD (mm) | 5.76 (0.39) | 4.0 | 6.6 | <0.001 |
| Post-Therapy Left Eye ONSD (mm) | 5.56 (0.36) | 4.6 | 6.1 | |

*Paired t-test

Among 61 patients, 50 (82.0% i.e 50/61) had raised ONSD indicating elevated intracranial pressure. Of these only 8.2% (5/61) had papilledema on fundus examination and 45 women (73.8% i.e 45 /61) with raised ONSD did not have any abnormality on fundus examination. The fundus exam did not reveal any abnormality in 91.8% (56/61) pre-eclamptic women and all normotensive females (Table 4).

**Table 4: Diagnostic performance of fundus examination for detecting raised intracranial pressure using ONSD as reference standard.**

| Fundus examination | Raised ONSD (ICP ↑) N (%) | Normal ONSD N (%) | Total N (%) |
|---|---|---|---|
| **Papilledema present** | 5 (8.2) | 0 (0.0) | 5 (8.2) |
| **Papilledema absent** | 45 (73.8) | 11 (18.0) | 56 (91.8) |
| **Total** | 50 (82.0) | 11 (18.0) | 61 (100.0) |

Fundus examination demonstrated a very low sensitivity (10%) but excellent specificity (100%) for detecting raised intracranial pressure reflected by increased ONSD (5/61). The positive predictive value was 100%, indicating that the presence of papilledema reliably confirms elevated ICP. However, the negative predictive value was low (19.6%), suggesting that absence of papilledema does not effectively exclude raised intracranial pressure. Overall, fundus examination has limited utility as a screening tool due to its low sensitivity but is highly reliable tool for confirmation in presence of finding of raised ICP/ papilledema (Table 5).

**Table 5: Diagnostic accuracy of fundus examination and ONSD.**

| Parameters | Value (%) |
|---|---|
| **Sensitivity** | 10.0 |
| **Specificity** | 100.0 |
| **Positive Predictive Value (PPV)** | 100.0 |
| **Negative Predictive Value (NPV)** | 19.6 |

On the other hand ONSD demonstrated good sensitivity (81.9%) and excellent specificity (100%) for detecting pre-eclampsia. The positive predictive value was 100%, indicating that raised ONSD reliably identifies pre-eclamptic patients. The negative predictive value was 84.3%, suggesting that normal ONSD reduces the likelihood of pre-eclampsia but does not completely exclude it. Overall, ONSD appears to be a useful diagnostic tool with high specificity and reasonable sensitivity.

Overall, papilledema was uncommon despite a high prevalence of raised ONSD, suggesting that fundus examination may miss a substantial number of cases with elevated intracranial pressure.

## DISCUSSION

Earliest studies on the role of ONSD measurement in detection of raised ICP in pre-eclampsia patients was done by Dubost et al.[6] In the present study too, ONSD was significantly higher in preeclamptic women compared to normotensive controls in both eyes, supporting its role as a non-invasive marker of raised intracranial pressure. The mean ONSD values observed in this study (approximately 5.7–5.8 mm in preeclampsia vs 4.8 mm in normotensive women) are consistent with findings from several previous studies done by El Zoghby et al and Dubost et al.[6,7] Studies by Jha et al, Jan et al, and Singh et al further demonstrated a stepwise increase in ONSD from normal pregnancy to mild and severe preeclampsia and even higher values in eclampsia, indicating a clear relationship between ONSD and disease severity.[8-10] In contrast, Arzpeyma et al found no significant difference between mild and severe preeclampsia, suggesting a possible plateau effect in some populations, while Mota et al. did not observe a statistically significant difference across hypertensive groups, potentially due to differences in study design, timing of measurement, or patient characteristics.[11,12] Additionally, Gonzalez et al reported significantly higher ONSD values in eclampsia compared to preeclampsia, indicating that ONSD may increase further with advanced neurological involvement.[13] Overall, the findings of the present study are in strong agreement with the majority of literature, demonstrating that ONSD is elevated in preeclampsia and tends to increase with disease severity, thereby supporting its utility as a reliable, non-invasive tool for assessing intracranial pressure and identifying patients at risk of neurological complications.

In the present study, a significant reduction in ONSD was observed in both eyes following therapy, indicating improvement in intracranial pressure due to better cerebral hemodynamics. Elevated pre-therapy values suggest underlying intracranial hypertension in preeclampsia. The standardized 24-hour measurement (82%) enhances reliability by allowing adequate time for treatment effects. These findings are supported by Rani et al, who reported significant ONSD reduction as early as 4 hours after magnesium sulfate administration, and by Biswas et al, who demonstrated a progressive decline from admission to day 7. Overall, ONSD serves as a sensitive, non-invasive marker for monitoring treatment response in preeclampsia.[14,15]

The diagnostic performance analysis confirms fundus examination's fundamental limitations as a screening tool for raised intracranial pressure in pre-eclampsia, exhibiting exceptionally low sensitivity (10%) despite perfect specificity (100%), positive predictive value (100%), and low negative predictive value (19.6%) when using ONSD as reference standard. Among 61 pre-eclamptic women, 82% had elevated ONSD (>5.4 mm) indicating ICP elevation, yet papilledema was present in only 5 cases (8.2%), all true positives, missing 45 patients (73.8%) with subclinical sheath distension reflecting early cerebral vasogenic edema. This aligns with neurocritical care literature documenting funduscopy's 10-30% sensitivity due to papilledema's delayed onset (requiring days of sustained ICP >20-25 mmHg for optic disc edema), while ONSD detects subarachnoid pressure transmission within hours. The superior performance of ONSD is further evidenced by Wilson et al s emergency department validation (NPV 91% versus fundoscopy) and Hemanth et al.[16,17] high accuracy (88% sensitivity, 100% specificity versus CT-confirmed ICP), which confirm its reliability for early detection in our high-risk pre-eclampsia cohort, where 90.2% received magnesium sulfate prophylaxis and eclampsia progression was limited to 3.3%, demonstrating that fundoscopy's 90% miss rate for ICP elevation could critically delay life-saving interventions. Therefore, ONSD measurement emerges as the indispensable bedside surrogate for ICP monitoring in pre-eclampsia, complementing but superseding funduscopy for timely risk stratification and management.

## CONCLUSION

The measurement of optic nerve sheath diameter offers several practical advantages. It can be performed bedside, requires minimal time, and avoids radiation exposure. It is particularly suitable in pregnancy, where imaging modalities such as CT or MRI may be limited due to logistical constraints or delayed access. Additionally, optic nerve ultrasonography can be repeated frequently for monitoring changes in intracranial pressure over time, making it valuable in dynamic clinical decision-making. Case–control comparison with normotensive pregnant women strengthened the validity of findings. However, Single-center study, which may limit generalizability to broader populations. But at the end of study, considering all factors we highly recommend incorporation of this tool in detection of pre-eclampsia related neurogenic changes.

*Funding: No funding sources*
*Conflict of interest: None declared*
*Ethical approval: The study was approved by the Institutional Ethics Committee*

## REFERENCES

1. American College of Obstetricians and Gynecologists. Gestational hypertension and preeclampsia: ACOG Practice Bulletin, Number 222. Obstet Gynecol. 2020;135(6):e237–60.
2. Mol BWJ, Roberts CT, Thangaratinam S, Magee LA, de Groot CJM, Hofmeyr GJ. Pre-eclampsia. Lancet. 2016;387(10022):999–1011.
3. Steegers EA, von Dadelszen P, Duvekot JJ, Pijnenborg R. Pre-eclampsia. Lancet. 2010;376(9741):631–44.
4. Rana S, Lemoine E, Granger JP, Karumanchi SA. Preeclampsia: pathophysiology, challenges, and perspectives. Circ Res. 2019;124(7):1094–112.
5. Hansen WF, Burnham SJ, Svendsen TO, Katz VL, Thorp JM Jr, Hansen AR. Transcranial Doppler findings of cerebral vasospasm in preeclampsia. J Matern Fetal Med. 1996;5(4):194–200.
6. Dubost C, Le Gouez A, Jouffroy V, et al. Optic nerve sheath diameter used as ultrasonographic assessment of the incidence of raised intracranial pressure in preeclampsia: a pilot study. Anesthesiology. 2012;116(5):1066–71.
7. El-Zoghby I, Fathy I, Atta F, Elhadidy SET. Ultrasonographic measurement of optic nerve sheath diameter as a predictor of severity of preeclampsia: a cross-sectional analytic study. Res Opin Anesth Intensive Care. 2025;12(2):126–32.
8. Singh SK, Bhatia K. Ultrasonographic optic nerve sheath diameter as a surrogate measure of raised intracranial pressure in severe pregnancy-induced hypertension patients. Anesth Essays Res. 2018;12(1):42–6.
9. Jan S, Nazir O, Hussain A, Kumar A. Comparison of optic nerve sheath diameter in preeclampsia and normal pregnancy using ocular USG. Int J Reprod Contracept Obstet Gynecol. 2022;11(7):1896–9.
10. Jha AK, Sah BK, Jha S. Measurement of optic nerve sheath diameter using ultrasound as an indicator of raised intracranial pressure in patients with pre-eclampsia. Nepal J Radiol. 2025;14(2):9–15.
11. Arzpeyma SF, Khorram PB, Asgharnia M, Mohtasham-Amiri Z. Investigating the relationship between ultrasound measured optic nerve sheath diameter and preeclampsia. AIMS Med Sci. 2019;6(3):250–9.
12. Mota MF da, Amorim MM de, Correia MDT, Katz L. The optic nerve sheath in hypertensive disorders of pregnancy and perinatal outcomes: a cohort study. BMC Pregnancy Childbirth. 2024;24(1):654.
13. González MC, Rodríguez DC, Alvarez MM, Wong LY, Escobedo LR, Roibal RS. Daily optic nerve sheath diameter monitoring for early detection of cerebral edema in preeclampsia and eclampsia. BioNatura J. 2025;2(4):13.
14. Rani K, Jain P, Bhogawar SD, Bhogawar RS, Prasad MK, Choudhary AK. Ultrasonographic changes in transorbital measurement of optic nerve sheath diameter in magnesium sulfate-treated severely preeclamptic patients. Anesth Essays Res. 2022;16(3):366–72.
15. Biswas J, Khatun N, Bandyopadhyay R, Bhattacharya N, Maitra A, Mukherjee S, et al. Optic nerve sheath

diameter measurements using ultrasonography to diagnose raised intracranial pressure in preeclampsia: an observational study. J Turk Ger Gynecol Assoc. 2023;24(1):5–11.
16. Wilson CL, Leaman SM, O'Brien C, Savage D, Hart L, Jehle D. Novice emergency physician ultrasonography of optic nerve sheath diameter compared to ophthalmologist fundoscopic evaluation for papilledema. J Am Coll Emerg Physicians Open. 2021;2(1):e12355.
17. Hemanth VS, Sethu Babu, Mithun Murali. Utility of optic nerve sheath diameter measurement by point-of-care ultrasound to detect raised intracranial pressure: a prospective observational study. J Res Med Dent Sci. 2022;10(7):66–71.

**Cite this article as:** Sharma A, Jindal N, Thakur R, Bhoil R. Correlation of optic nerve sheath diameter in raised intracranial pressure in pre-eclampsia: a prospective observational study in preeclampsia in a low-resource setting. Int J Reprod Contracept Obstet Gynecol 2026;15:4900-6.