

DOI: 10.5455/2320-1770.ijrcog20150432

Research Article

Evaluation of post hysterectomy vaginal cuff related complications and their management after different modes of hysterectomy

Shreejana Hamal*, Ju Wen Hui, Wang Xian Rong, Li Hui

Department of Obstetrics & Gynecology, Jingzhou Central Hospital, Yangtze University, Jingzhou-434020, Hubei, China

Received: 14 February 2015

Accepted: 27 February 2015

***Correspondence:**

Dr. Shreejana Hamal,

E-mail: me_whiterose2004@hotmail.com

Copyright: © the author(s), publisher and licensee Medip Academy. This is an open-access article distributed under the terms of the Creative Commons Attribution Non-Commercial License, which permits unrestricted non-commercial use, distribution, and reproduction in any medium, provided the original work is properly cited.

ABSTRACT

Background: Aim: To update the incidence of vaginal cuff related complications after different modes of hysterectomy and their management.

Methods: The study was conducted in Jingzhou central hospital, Jingzhou, Hubei, China. Patient's case files were reviewed who had undergone Hysterectomy from 1st Jan. 2013 - 31st Dec. 2014. The incidence of vaginal cuff related complications were retrospectively evaluated by different approaches. Data were collected according to our inclusion criteria and statistically analyzed its significance ($P < 0.05$).

Results: 887 patients underwent hysterectomy during 2 years of study period. Mean age was 54 ± 4 years. Overall incidence of vaginal cuff related complications were 34 (3.83%) which included vaginal cuff bleeding 12 (1.35%), vaginal cuff infections 16 (1.80%) and vaginal cuff dehiscence 6 (0.67%) without evisceration. Laparoscopic hysterectomy had higher incidence (6.12%), than open abdominal (2.56%) and vaginal (3.22%) hysterectomy. Incidences were significant ($P = 0.032$) to approaches of hysterectomy. The Incidence of vaginal cuff dehiscence between Laparoscopic and Open abdominal hysterectomy were significant ($P = 0.015$) but the incidence of vaginal cuff bleeding ($P = 0.90$) and vaginal cuff infection ($P = 0.74$) were not significant. Over all incidences were higher in malignancy (61%) than benign (20%).

Conclusions: Study suggests that vaginal cuff bleeding, cuff infection, cuff dehiscence and evisceration are rare but not negligible which may lead into catastrophic conditions. Early diagnosis and appropriate management reduces further complications. Partial cuff dehiscence can be managed conservatively without surgical repair with satisfactory outcome.

Keywords: Vaginal cuff bleeding, Vaginal cuff infection, Vaginal cuff dehiscence

INTRODUCTION

Hysterectomy is one of the most common gynecologic surgical procedures. Today, we have many feasible approaches for hysterectomy according to patient conditions, disease pathology, availability and patient's preferences. Because of advancement of knowledge in gynecological surgeries and progressive improvement in these fields, minimal invasive techniques becoming more popular and being practiced. But the advantage and

disadvantage of various surgical techniques for hysterectomy are still under the topics of research. To date, laparoscopic surgery has evolved rapidly worldwide, not only for patients with benign gynecologic disease, but also for the patient with malignancies. The proportion of laparoscopic hysterectomies has been increasing compared with traditional open abdominal hysterectomy.¹

However, variety of complications can be occurred with hysterectomies during intra-operative such as

hemorrhage, bladder, ureter, and gastrointestinal injuries or postoperative complications including infection, hematoma, DVT, fistula formation and neuropathy.² Vaginal cuff complications such as vaginal cuff bleeding, vaginal cuff infection, vaginal cuff dehiscence and vaginal cuff evisceration are also rare but serious complications of hysterectomy.

Vaginal cuff related complications may present with different signs and symptoms in different range of time period after hysterectomy and their management approaches are also differs according to clinical circumstances. Most common presentation includes pelvic or abdominal pain (58-100%), vaginal bleeding or watery vaginal discharge (33%-90%). One study reported 2 asymptomatic patients with a cuff dehiscence and patient with evisceration often describe feeling of a mass or pressure.³ Up to date, most of the literatures are still in doubt regarding exact incidence, and etiology of vaginal cuff related complications. There are few literatures mentioning the incidence of vaginal cuff dehiscence and evisceration but not about vaginal cuff bleeding and vaginal cuff infection.

So, the objective of this retrospective observational study was to update the incidence of vaginal cuff related complications such as cuff bleeding, cuff infection, cuff dehiscence and evisceration after different modes of hysterectomy and to describe their conservative as well as surgical management.

METHODS

This was a single centered retrospective observational study conducted in gynecological ward-1, Jingzhou central hospital, Jingzhou, Hubei, China. A total of 887 patients who underwent different modes of hysterectomy from 1st January 2013 to 31st December 2014 were considered in our study group. We allocated them into three major groups according to different approaches to hysterectomy. Laparoscopic hysterectomy (n=310) open abdominal hysterectomy (n=546) and vaginal hysterectomy (n=31). In which, laparoscopic was further sub divided into Total Laparoscopic Hysterectomy (TLH) and Laparoscopic Radical Hysterectomy and Node Dissection (LRHND), in the same way open abdominal hysterectomy also subdivided into Total Abdominal Hysterectomy (TAH) and Radical Abdominal Hysterectomy (RAH).

All patients were called for 2 routine postoperative follow up vaginal examinations at 4 weeks (1 month) and 12 weeks (3 months) after hysterectomy at gynecology OPD to detect any Vaginal Cuff Related Complications (VCRCs). The data were collected according to our inclusion criteria. The medical records of all patients with vaginal cuff related complications were further reviewed. Vaginal cuff related complications included vaginal cuff bleeding; vaginal cuff infection; vaginal cuff dehiscence and evisceration were thoroughly evaluated.

Inclusion criteria for vaginal cuff related complications (VCRCs)

Vaginal Cuff Bleeding (VCB): It was defined as:

1. Any active bleeding from vaginal cuff after hysterectomy at any time, or
2. Any mild to moderate postoperative vaginal bleeding (excluding postoperative vaginal spotting) that noticed more than 4 weeks, or
3. Any vaginal cuff bleeding that was noticed at the time of first follow up at OPD.

Vaginal Cuff Infection (VCI): It was defined as:

1. Any foul smell vaginal discharge noticed at first or second follow up at OPD with positive swab culture, or
2. Presence of vaginal cuff ulceration with signs of inflammation, fever, pelvic pain, vaginal discharge with or without raised TC/DC, or
3. Positive vaginal cuff swab culture at any time of post hysterectomy patient.

Vaginal Cuff Dehiscence (VCD): It was divided as partial and complete vaginal cuff dehiscence depending patient's clinical presentations.

1. Partial vaginal cuff dehiscence was defined as any partial split of vaginal cuff noticed during 2nd follow up (at 3 months or more) at OPD, with or without clinical presentation of Pelvic pain, vaginal bleeding or watery discharge that required conservative management.
2. Complete dehiscence defined as complete separation of vaginal cuff edges noticed at 1st follow up (after 30 days) at OPD that required surgical intervention, or
3. Complete separation of vaginal cuff at any time with or without clinical presentation of Pelvic pain, vaginal bleeding or watery discharge with or without evisceration that required conservative or surgical intervention.

Vaginal Cuff Evisceration (VCE): It was defined as complete separation of vaginal cuff with the protrusion of intra-abdominal content or any visceral organ into vagina.

The statistical analysis of the data collected was done using XLSTAT's statistical analysis software version 2015. The results were analyzed using Chi-square test. The P values ($P < 0.05$) were considered statistically significant. Evaluation of the incidence of vaginal cuff related complications in different modes of hysterectomy,

different indications for surgery, clinical presentations and management of these complications including conservative and surgical intervention were discussed.

RESULTS

A total of 887 hysterectomies were performed during 2 years of study period. Only 34 (3.83%) patients out of 887 hysterectomies were developed vaginal cuff related complications according to our inclusion criteria.

Out of 34 patients, 12 (1.35%) had vaginal cuff bleeding, 16 (1.80%) had vaginal cuff infection and 6 (0.67%) had vaginal cuff dehiscence.

We did not find any case of vaginal cuff evisceration during our study period. The mean age of the study population was 54 ± 4 years (range, 24-77 years), three approaches included open abdominal 546 (62%), laparoscopic 310 (35%) and vaginal 31 (3%) hysterectomy were performed.

Total incidence of vaginal cuff related complications are shown in Table 1.

Table 1: Evaluation of incidence of vaginal cuff related complications by different approaches to hysterectomy.

VCRC	LH	OAH	VH	Total	P value
Yes	19 (6.12%)	14 (2.56%)	1 (3.22%)	34 (3.83%)	0.032
No	291	532	30	853	
Total	310	546	31	887	

Incidence of vaginal cuff related complications between laparoscopic and open abdominal hysterectomies were compared in Table 2. And incidence of VCRCs by different modes of hysterectomy depending disease pathology were shown in Table 3.

Table 2: Incidence of vaginal cuff related complications in laparoscopic and open abdominal hysterectomy.

VCRC	LH	OAH	P value
VCB	6	6	0.909
VCI	8	7	0.747
VCD	5	1	0.015

Table 3: Incidence of vaginal cuff related complications by different modes of hysterectomy.

Modes of hysterectomy	Total N (%)	VCB	VCI	VCD	Total n (%)	P value
TAH	486 (55%)	1	1	0	2 (0.41%)	0.038
ARH	60 (7%)	5	6	1	12 (20%)	
TLH	275 (31%)	0	5	5	10 (3.63%)	
LRHND	35 (4%)	6	3	0	9 (25.7%)	
VH	31 (3%)	0	1	0	1 (3.22%)	
Total	887	12 (1.35%)	16 (1.80%)	6 (0.67%)	34 (3.83%)	

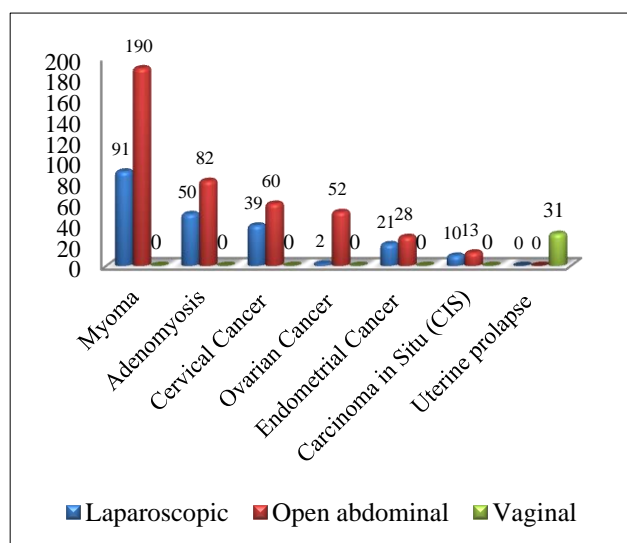


Figure 1: Seven most common indications of hysterectomy during study period.

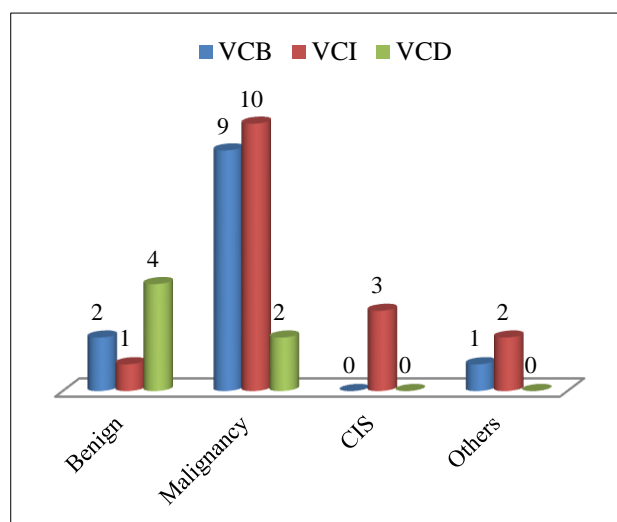


Figure 2: Relation between vaginal cuff related complications and disease pathology.

The 7 most common indications of hysterectomy (Figure 1) were myoma (31.67%), adenomyosis (14.88%), cervical cancer (11.16%), ovarian cancer (6.08%), endometrial cancer (5.52%), carcinoma *in situ* (cis-2.59%) and uterine prolapse (3.49%). Out of 34 cases the incidence of VCRCs were significantly higher in malignancy (61%) than benign (20%) pathology ($P = 0.40$) (Figure 2).

DISCUSSION

After hysterectomy every patient requires at least 2 routine postoperative follow up for vaginal cuff examinations. In our hospital we do first follow up at 4 weeks and second at 12 weeks from discharge date. We encounter with different types of postoperative vaginal cuff complications depending on patient's age, physical status, disease pathology and treatment approaches. We have tried our best to explore some rare but not negligible vaginal cuff related complications such as vaginal cuff bleeding, vaginal cuff infection, vaginal cuff dehiscence and evisceration. These are rare but serious complications after hysterectomy or pelvic surgery.⁴

Though the data are limited the exact incidence of vaginal cuff related complications are difficult to determine because the definition and the incidence varies from study to study. Our study showed the overall incidence of vaginal cuff related complications were 3.83%, in which Laparoscopic hysterectomy had higher incidence (6.12%), than compared with open abdominal hysterectomy (2.56%) and vaginal hysterectomy (3.22%). The incidence of vaginal cuff related complications were significant ($P = 0.032$) according to the approaches to hysterectomy. The incidence of VCD between laparoscopic and open abdominal hysterectomy was statistically significant ($P = 0.015$) but the incidence of VCB ($P = 0.90$) and VCI ($P = 0.74$) between them were not statistically significant.

In our study, laparoscopic hysterectomy approach was associated with increased incidence of VCD (1.61%) compared with total abdominal hysterectomy (0.18%). The literature shows the incidence of VCD ranging from 0% to 7.5%⁴ which supports our findings. Kho RM et al.⁵ and Nick AM et al.⁶ also confirmed our finding with their studies of incidence of VCD after laparoscopic hysterectomy (TLH) ranges from 1% to 4.1%. Another literature reported that incidence of VCD after robotic hysterectomy ranges from 0.14% to 4.1% which was higher than studies including all types of hysterectomy. (0.14%-0.27%).^{5,7,8}

Altogether, 12 (1.35%) patients had vaginal cuff bleeding, 10 patients were noticed at gynecology OPD during first F/U at 4 weeks. Most of them were associated with poor wound healing (malignancy) and treated with conservatively whereas 2 patients were noticed active bleeding at 2nd postoperative day in ward and had required per vaginal surgical cuff repair. First case was associated with LRHND of cervical cancer with loose

suture tie and second was associated with TLH of Myoma with loose suture tie. Sumeyra Nergiz et al.⁹ also reported a case of hematoma after postpartum hysterectomy repaired by vaginal suturing. Byron Cardoso Medina et al.¹⁰ has documented postoperative vaginal bleeding in 53 cases (32.5%) sutured with polygalactine group versus 13 cases (18.8%) with barbed suture group. they further concluded that suture during vaginal cuff closure in patients who underwent laparoscopic hysterectomy, the use of barbed suture showed a decrease of 43% in the proportion of patients who presented with Postoperative vaginal bleeding but in our case we had vaginal cuff closure with continuous vicryl suture. In fact, the occurrence of less post-operative vaginal cuff bleeding might represent a much better closure of the vaginal cuff edges and a decreased cuff dehiscence probability.

Vaginal cuff infection was diagnosed with positive cuff swab culture in 16 (1.80%) patients Three most common pathogens to cause post hysterectomy vaginal cuff infection in our study population were *Escherichia coli* (7), *Staphylococcus aureus* (4), and *Candida* species (2) and others (3) respectively. All were managed by conservatively with antibiotics according to culture sensitivity test and vaginal washing by NS diluted beta dine solution. VCI was associated with advance age, Diabetes and Malignancy who were under chemotherapy and radiotherapy. Whereas, Byron Cardoso Medina et al.¹⁰ documented incidence of vaginal cuff infection in 2 cases (1.2%) with polyglactine suture type versus 2 (2.9%) barbed suture type which was statistically not significant which also support our findings.

Vaginal cuff dehiscence noticed more common in TLH than open abdominal hysterectomy.⁹ In our study 4 cases were of partial cuff dehiscence identified at gynecology OPD during second F/U at 3 months of time. But 2 were of complete dehiscence, one was noticed at 4 weeks and another at 5 months but both were the case of ovarian cancer who were on chemotherapy. But literature shows it can occurs at any time after pelvic surgical procedures and has been reported as early as 3 days¹¹ and as late as 30 years post operatively.¹² Out of 6, 4 were managed conservatively as our hospital protocol with Chinese medicine. And 2 were managed surgically by trans-vaginal continuous suture.

Currently 50% of the cases reported about VCD in the literature occurred after total laparoscopic hysterectomy or robotic hysterectomy.⁸ TLH and Robotic hysterectomy may be associated with higher risk of vaginal cuff dehiscence. It may cause mortality and morbidity.¹³ Although, one study reported 2 asymptomatic patients with a cuff dehiscence (in a series of 21 patients) who were diagnosed at a routine post-operative appointment, most patients with cuff dehiscence present for medical care within 24 hours of the onset of symptoms. Evisceration occurs in up to 70% of vaginal cuff dehiscence cases.^{5,8} In addition, patient characteristics like smoking, diabetes, chronic lung disease, increasing

intra-abdominal pressure by coughing and constipation, malignancy, vaginal atrophy, advance age, chronic steroid therapy, postoperative radiation therapy and additional risk factors like early sexual intercourse, postoperative cuff infection and hematoma are associated with VCD.⁹ However, spontaneous vaginal cuff dehiscence has been representing up to 70% of cases.^{6,14}

In management aspect of VCD, vaginal repair is one of the techniques used for vaginal cuff dehiscence. The current evidence available on approaches are vaginal, abdominal, and laparoscopic. But it does not suggest that one approach is preferred over the others. The cases reported in the literature illustrate that vaginal, laparoscopic, abdominal, and combined approaches are all appropriate methods for secondary cuff closure.³

However; literature are silent on conservative management and healing by secondary intention in the cases of partial vaginal cuff dehiscence containing some granulated tissues or cuff dehiscence with infection or eroded stump. In such cases, we often practice conservative treatment in our hospital who neither fit for surgical repair nor need for immediate surgical intervention.

For such candidate protocol is as follows:

First of all, we treat all the aggravating factors for cuff dehiscence like bleeding, hematoma, infection, anemia, Hypoalbuminia, Diabetes, poor nutrition, poor perineum hygiene or any additional factors and risk factors.

1. We start i.v. antibiotics according to vaginal cuff swab culture and sensitivity for 7 to 14 days.
2. We start iv anti-inflammatory drugs for 7 to 10 days
3. We strictly advice patient to have every day vaginal washing with NS diluted beta dine solution for 1 month.
4. We advise local application of Baofukang gel (Chinese medicine) per vaginally once a day after each wash for at least one month.
5. We often evaluate the growth of granulation tissue every one week of interval and allow wound healing by secondary intention and do wait for one month for complete recovery.

Briefly, Baofukang is pure traditional Chinese medicine, the main ingredients are Curcuma wood oil (containing 20 chemical elements and borneol, etc. works as anti-fungal, anti-virus, anti-bacterial, anti-mycoplasma, trichomonas and anti-inflammatory effects,¹⁵ Baofukang suppository combined with gentamycin and metronidazole are effective in treating chronic cervicitis, the treatment could improve the levels of SOD, Hs-CRP, IL-6 and TNF-alpha as well as clinical symptom.¹⁶ Yang Zhi et al.¹⁷ have mentioned about application of Baofukang suppository in the treatment of cervical erosion is significant, the treatment can effectively reduce the vaginal discharge and bleeding volume and shorten

the bleeding time, reduce infection without significant adverse reactions.

CONCLUSION

Although, vaginal cuff related complications are rare but not negligible. Most of the literatures mention only about vaginal cuff dehiscence and surgical management but our study gives additional information about incidence of cuff bleeding and cuff infection which are also important risk factors for cuff dehiscence and evisceration, so it is important to select appropriate patient for appropriate approach, good intra-operative or postoperative management, right vaginal cuff closure techniques, post-operative counseling and post-operative follow up for vaginal cuff examination can avoid catastrophic complications of dehiscence and evisceration. Finally, conservative management gives satisfactory outcome for partial cuff dehiscence.

ACKNOWLEDGEMENTS

The authors would like to thank specially to Dr. Prakash Shahu. We really appreciate his great contribution during our study. We also thank Dr. Zhou Li and Dr. Liu Hua for their precious time during data collection and data analysis.

Funding: No funding sources

Conflict of interest: None declared

Ethical approval: The study was approved by the institutional ethics committee

REFERENCES

1. Shin JW, Lee HH, Lee SP, Park CY. Total laparoscopic hysterectomy and laparoscopy-assisted vaginal hysterectomy. *JLAS*. 2011;15:218-21.
2. Clarke-Pearson, Daniel L. Geller, Elizabeth J. Complications of hysterectomy. *Obstet Gynecol*. 2013;121(3):654-73.
3. Cronin B, Sung VW, Matteson KA. Vaginal cuff dehiscence: risk factors and management. *Am J Obstet Gynecol*. 2012;206(4):284-8.
4. Kim MJ, Kim S, Bae HS, Lee JK, Lee NW, Song JY. Evaluation of risk factors of vaginal cuff dehiscence after hysterectomy. *Obstet Gynecol Sci*. 2014;57(2):136-43.
5. Kho RM, Akl MN, Cornella JL, Magtibay PM, Wechter ME, Magrina JF. Incidence and characteristics of patients with vaginal cuff dehiscence after robotic procedures. *Obstet Gynecol*. 2009;114:231-5.
6. Nick AM, Lange J, Frumovitz M, Soliman PT, Schlumbrecht MP, dos Reis R, et al. Rate of vaginal cuff separation following laparoscopic or robotic hysterectomy. *Gynecol Oncol*. 2011;120(1):47-51.
7. Hur HC, Guido RS, Mansuria SM, Hacker MR, Sanfilippo JS, Lee TT. Incidence and Patient characteristics of vaginal cuff dehiscence after

- different modes of hysterectomies. *J Minim Invasive Gynecol.* 2007;14(3):311-7.
8. Iaco PD, Ceccaroni M, Albonic C, Roset B, Sansovini M, D'Alessandro L, et al. Transvaginal evisceration after hysterectomy: is vaginal cuff closure associated with a reduced risk? *Eur J Obstet Gynecol Reprod Biol.* 2006;125(1):134-8.
 9. Avcioğlu SN, Altinkaya SÖ, Küçük M, Yüksel H, Demircan-Sezer S. Vaginal repair of vaginal vault dehiscence after postpartum hysterectomy. *J Surg Case Rep.* 2014;2:1-2.
 10. Medina BC, Giraldo CH, Riaño G, Hoyos LR, Otorola C. Barbed suture for vaginal cuff closure in laparoscopic hysterectomy. *JLS.* 2014;18:83-8.
 11. Cardosi RJ, Hoffman MS, Roberts WS, Spellacy WN. Vaginal evisceration after hysterectomy in premenopausal women. *Obstet Gynecol.* 1999;94:859.
 12. Moen MD, Desai M, Sulkowski R. Vaginal evisceration managed by transvaginal bowel resection and vaginal repair. *Int Urogynecol J Plevic Floor Dysfunct.* 2003;14(3):218-20.
 13. Falcone T. Vaginal cuff dehiscence after hysterectomy. *Obstet Gynecol.* 2012;120:511-2.
 14. Croak AJ, Gebhart JB, Klingele CJ. Characteristics of patients with vaginal rupture and evisceration. *Obstet Gynecol.* 2004;103(3):572-6.
 15. Medical Paper, Clinical Medicine Papers. Microwave Baofukang clinical observation of treating cervical erosion suppository, 2011. Available at: <http://anpaper.com/medical/microwave-baofukang-clinical-observation-of-treating-cervical-erosion-suppository.html>. Accessed 12 February 2015.
 16. LIU Lin Jun. Baofukang Suppository and western Medicine in treating 30 cases of chronic cervicitis. *West J Trad Chin Med.* 2013;(9):1004-12.
 17. Zhi-ping Y, Xin W. Effects on LEEP combined with Interferon suppository and Baofukang suppository on treating cervical erosion. *Chin J Experiment Trad Med Form.* 2011;17(10):287.

DOI: 10.5455/2320-1770.ijrcog20150432

Cite this article as: Hamal S, Hui JW, Rong WX, Hui L. Evaluation of post hysterectomy vaginal cuff related complications and their management after different modes of hysterectomy. *Int J Reprod Contracept Obstet Gynecol* 2015;4:447-52.