

DOI: <http://dx.doi.org/10.18203/2320-1770.ijrcog20175490>

Case Report

Struma Ovarii associated with Pseudo-Meigs Syndrome and elevated serum Ca 125: Case report and literature review

Oyuki A. Morales^{1*}, Junior J. Araiza¹, Tania P. Alvarez Dominguez²,
Rafael Medrano Guzman³, Jorge A. Barbabosa⁴, Maria I. Tolentino Sosa⁴

¹Department of Gynecology, Postgraduate School in Naval Health, Coyoacán Delegation, Mexico

²Pathologist-Oncologist, Pathology Service, General Hospital Naval of High Specialty (HOSGENAES), Coyoacán Delegation, Mexico

³Oncology Surgeon, Oncological Surgery Service, General Hospital Naval of High Specialty (HOSGENAES), Coyoacán Delegation, Mexico

⁴Gynecology-Obstetrics Service of the General Hospital Naval of High Specialty (HOSGENAES), Coyoacán Delegation, Mexico

Received: 14 November 2017

Accepted: 23 November 2017

*Correspondence:

Dr. Oyuki A. Morales,

E-mail: aricet_512@hotmail.com

Copyright: © the author(s), publisher and licensee Medip Academy. This is an open-access article distributed under the terms of the Creative Commons Attribution Non-Commercial License, which permits unrestricted non-commercial use, distribution, and reproduction in any medium, provided the original work is properly cited.

ABSTRACT

Struma Ovarii is a highly specialized monodermal teratoma in which the major component is thyroid tissue. Its relationship with Pseudo Meigs syndrome, hyperthyroidism and elevation of Ca 125 is a rare condition; this could mimic malignancy. Ultrasound and axial tomography may be useful in diagnosis; but histopathological criteria play a very important role in the definitive diagnosis. Our objective is to present a case report of Struma ovarii, ascites, pleural effusion (pseudo meigs syndrome), elevation of Ca 125, hyperthyroidism, and review the published literature in relation to epidemiology and diagnostic characteristics.

Keywords: Ovary, Pseudo-Meigs´ syndrome, Struma Ovarii

INTRODUCTION

Struma ovarii is a highly specialized monodermal teratoma in which the major component is thyroid tissue. It constitutes 0.3-2.5% of ovarian teratomas and about 0.3% of all neoplasms of ovarian origin.^{1,2}

Originally described by Bottlin in 1888; later in 1903 Ludwig Pick who suggested that it represents a teratoma in which the thyroid tissue has grown more than the other elements.³ It is defined as ovarian goiter comprising total or predominantly thyroid tissue (> 50%), in which the thyroid tissue has coated the other tissues or only the

thyroid tissue has developed.^{4,5} it was defined as a teratoma that contained more than 50% of thyroid tissue⁴ or a thyroid-related malignant neoplasm.⁶

Thyroid tissue is functionally and structurally similar to normal cervical thyroid tissue.⁷ The presence of benign changes such as goiter are not of greater clinical importance, except in the cases of patients with symptoms of hyperthyroidism.⁸

Meigs and Cass described a rare triad consisting of ovarian fibroma / tecoma, ascites, and hydrothorax, and symptoms resolved with the removal of the benign tumor.⁹

In 1954 Meigs proposed limiting the true Meigs Syndrome to benign and solid ovarian tumors with the macroscopic appearance of a fibroid. Further on, the Pseudo-Meigs Syndrome was defined, which consisted of the same symptoms, but with other benign ovarian cysts.¹⁰ This syndrome usually presents in 5% in the Struma ovarii.¹¹

In a series by O'Connell et al., The predictive value of a CA 125 level above 35U/mL was 60% for ovarian cancer and 84% for any type of neoplasia.¹² In the literature, very few reports have been published on Struma Ovarii associated with ascites and elevated CA125.¹³⁻¹⁵

Due to the low frequency of the tumor and its clinical and histopathological features, the case of a 72-year-old female patient with pleural effusion, ascites, right ovary tumor, elevation of Ca 125, hyperthyroidism, of urgencies in General Hospital Naval of High Specialty; this in order to carry out a review of the published literature.

CASE REPORT

A 72-year-old patient, who attends the Emergency Department of the General Hospital Naval of High Specialty (HOSGENAES) in August 2017; referring to dyspnea, dry cough of 20 days of evolution. It has a history of importance: hypertension of 19 years of evolution treated with irbesartan; rest of history denied.

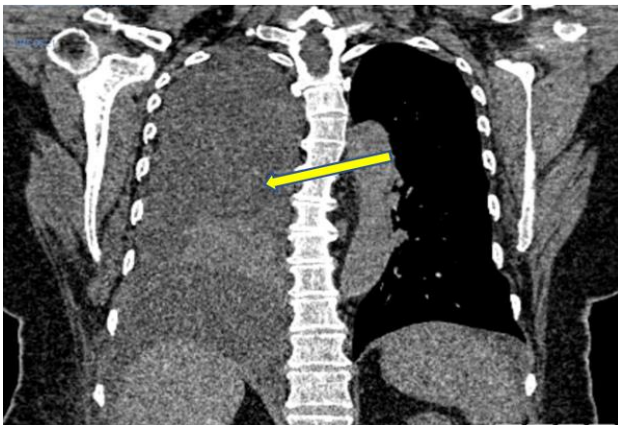


Figure 1: Pleural effusion in the right hemithorax.

At admission with clinical diagnosis of pleural effusion; Chest computed tomography showed 60% of pleural effusions in the right hemithorax, with no evidence of consolidation or reinforcement (Figure 1); is performed thoracentesis draining 2500ml to which cytology and cultures are performed; reporting exudative and negative characteristics to the development of microorganisms. Patient who has recurrent pleural effusion, so 3 days after admission, new thoracentesis is performed draining 1750ml. Among the extension studies that were requested, Ca 125 was found at 2639.90 U / ml, TSH

0.03 uUI / ml, Total T4 12.68 ug / Dl, as well as other laboratories in normal parameters.

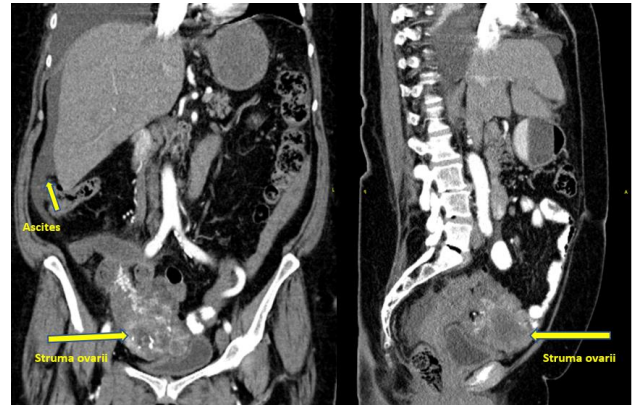

Figure 2: (a) Coronal and (b) sagittal section of the right Struma Ovarii, liquid and solid content is observed; as well as vascularity and presence of ascites.

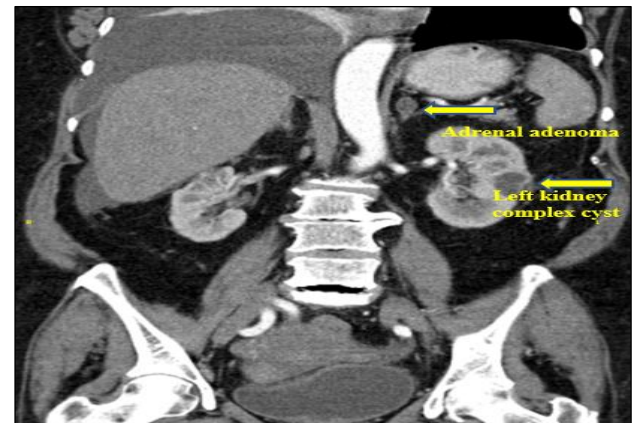


Figure 3: Coronal section showing adrenal adenoma Left and left ovarian complex cyst.

Due to high numbers of Ca 125 is suspected in malignant tumor of gynecological origin; for which abdominal-pelvic CT scan is requested, which report left adrenal adenoma of 19x11mm, complex cyst of left kidney of 33x29x22mm (Figure 3), right ovary tumor of 93x75x92mm with volume of 340cc; to correlate with mucinous cystadenocarcinoma; as well as free fluid in the abdominal cavity (Figure 2a and 2b). With previous antecedents it is decided to take percutaneous biopsy of ovary tumor by radio-oncology service, thinking about malignant tumor, with the purpose of staging; however, such a biopsy with a report consisting of Struma Ovarii.

Afterwards, it was evaluated by an oncologic surgery service, who decided to perform diagnostic and therapeutic laparoscopy, from which extra fluid ascitic 400ml, as well as a right ovary-dependent 10x8x8cm ovarian tumor, lobulated, with a solid and cystic consistency (Figure 4).

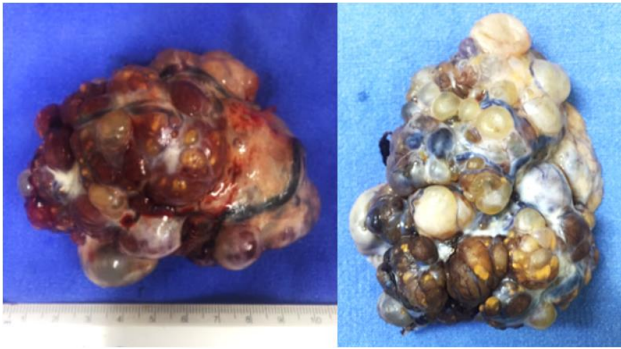


Figure 4: (macroscopic aspect of the specimen), ovarian of 10x8x8cm, which on the surface shows lobulated, brownish-yellow areas with vascularity, solid and liquid appearance.

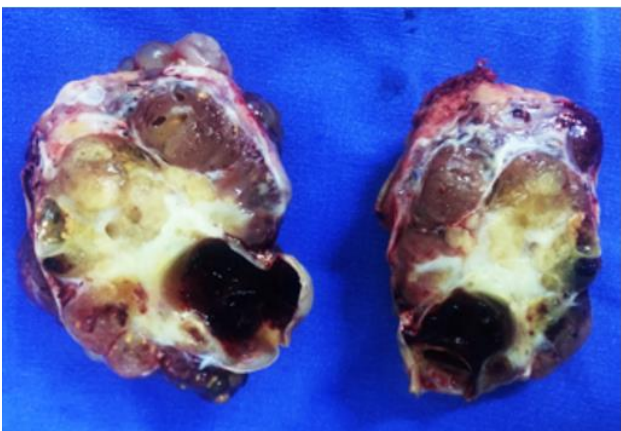


Figure 5: The macroscopic aspect of Struma Ovarii shows the solid component with tendency to the multinodularity, areas of hemorrhage and integral capsule.

It is sent to pathological transoperative study (right salpigo-ferectomy), which reports Struma Ovarii; mature teratoma with predominant component of thyroid glandular tissue (greater than 50%) (Figure 5), hyalinization of 20% of the tumor volume, with an integral capsule (Figures 6).

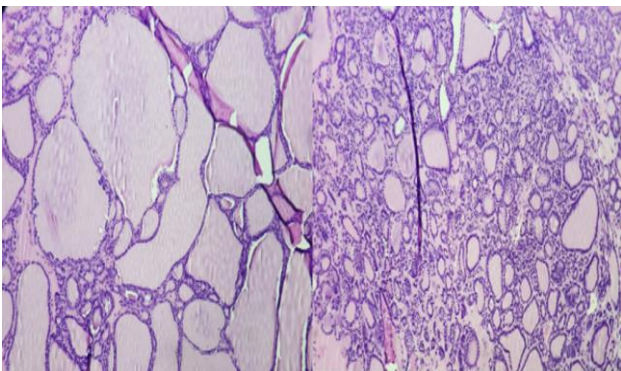


Figure 6: Histological section of the right ovary, showing tumor with multiple thyroid macrofollicles, with colloid content.

Patient who presented improvement after surgical procedure, being graduated 5 days after the same. Currently without evidence of ascites, pleural effusion or secondary complications; with laboratory studies tending to normal 2 months after surgery, Ca 125 70.6 U / ml, TSH 1.36 uUI / ml, T4 Total 10.15 ug / dl.

DISCUSSION

Mature cystic teratomas represent approximately 20% of all ovarian tumors; of these, approximately 15% contains normal thyroid tissue. Struma ovarii is a monodermal variant of ovarian teratoma, predominantly containing thyroid tissue. It occurs in 0.3% of all neoplasms of ovarian origin.

The age of presentation is similar to that of mature cystic teratomas, with the peak incidence in the fifth and sixth decades of life.² Although cases have been reported between the ages of 23 and 71 years, very similar to our patient, which was 72 years old.¹⁶ In 5-10% they are usually malignant; although their behavior is predominantly benign.^{1,7} Metastases are described in 5-6% of malignant struma ovarii.⁷ Papillary carcinoma is the most frequent malignant thyroid neoplasm that occurs in struma ovarii.¹⁷

It is usually unilateral (mainly right), although in 6-15% it is bilateral.^{2,7,16} It should be noted that our report presented unilateral right, as reported in the literature. In 20-44% of cases it is asymptomatic. The most frequent symptom is pelvic pain, followed by pelvic mass.^{2,16} Ascites occurs in 10-17%, however, the association of ascites and hydrothorax with this tumor is rare, and despite its prevalence, we observed presence of recurrent and progressive ascites of unclear etiology, as well as pleural effusion predominated right hemithorax. Symptoms of hyperthyroidism occur in 8% of cases, it is noteworthy that the patient's course is asymptomatic; however, with hyperthyroidism at the time of diagnosis.^{2,7,16}

As previously mentioned, the Pseudo-Meigs Syndrome consists of the presence of ascites, hydrothorax, benign ovarian cysts; the symptoms are resolved with the removal of the benign tumor.¹⁸ This syndrome usually occurs in 5% of the Struma ovarii.¹¹

Speaking of the pathophysiology of the triad that the patients present; it is worth mentioning that ascites can be caused by fluid transudation of interstitial edema or by the formation of cysts within the tumor secondary to injury or necrosis.¹⁹ A discrepancy between the arterial supply to a large mass of tumor tissue and its venous tissue and drainage lymphatic system can lead to stromal edema and transudation. The pressure on the lymphatics by the tumor itself can result in fluid leakage through the lymphatics.¹⁹ Less likely, tumor pedicle twisting could cause fluid production.²⁰ Conceivably, a combination of leakage of intratumoral fluid, mechanical irritation of the

tumor and peritoneal inflammation results in the production of ascites.¹⁰ As for the formation of pleural fluid, it has been thought to be the result of mechanical transfer of ascitic fluid to through the diaphragmatic openings or through the lymphatics.^{10,21} The ascitic and pleural fluids in the syndrome de Meigs and Pseudo-Meigs are usually serous, but may be serosanguinolent. In the literature, very few reports have been published on

Struma Ovarii associated with ascites and elevated CA125, we do not have statistics that tell us about prevalence.^{22,23} The exact reason for the elevation of CA 125 in Meigs Syndrome Pseudo-Meigs is still unclear; a possible explanation proposed by Mui et al is the irritation and subsequent inflammation of the pleural and peritoneal surface produced by the presence of free fluid in these spaces.²⁴

Table 1: Preoperative characteristics of Struma Ovarii associated with pseudo-Meigs syndrome and elevated Ca 125 levels.

Authors	Year	Age	Ca 125 (U/ml) Preoperative	Ascitis (ml)	Pleural spill (ml)	Thyroid change
Hurlow et al ²⁶	1975	60	NA	Present	8000	NA
Mantouvalos et al ²⁷	1982	42	NA	Present	2000	Hyperthyroidism
Amr et al ²¹	1994	55	NA	Present	3000	NA
Bethune et al ²⁸	1996	62	1621	Small quantity	3500	Absent
Zannoni et al ²⁹	2004	66	1636	5500	350	Absent
Loizzi et al ¹¹	2005	65	161	Few liters	Large amount	Hyperthyroidism
Uehara ³⁰	2007	67	2086	Massive	Massive	Absent
Obeidat et al ¹⁴	2007	52	149	4000	Moderate amount	Absent
Mitrou et al ³¹	2008	55	3803	29000	Small amount	Hypothyroidism
Rana et al ³²	2009	70	284	Present	Present	Absent
Mostaghel et al ³³	2012	72	607.4	700	Large amount	Absent
Obeidat et al ³⁴	2012	55	872	150000	Small amount	NA
Joan et al ³⁵	2013	60	280	600	Large amount	Hyperthyroidism
Chengjuan et al ³	2014	52	1289	1000	2000	Absent
Current report	2017	72	2639.9	4250	400	Hyperthyroidism

Authors searched Pubmed and Medline for all related articles under the terms of Medical Subject Headings (MeSH); in addition, all bibliographies of the primary documents were searched to recognize cited publications that had not been identified by electronic searches. The selection was not limited to the language.

The target population were cases of Struma Ovarii, combined with Pseudo Meigs syndrome and elevated Ca 125; of which a total of 15 cases were identified (Table 1 and 2). 93% (14) of the cases were unilateral, 46% (7) presented on the right side, as on the left side; only 6.6% (1) was reported bilaterally; all with an average size of 10cm by its greater diameter. The mean age oscillate between the 5th and 6th decade of life, with a range of 42 to 72 years. 46% presented ascites considered as large (>1000) and of those who presented pleural effusion 60% were of great quantity.

As for thyroid function, 33.3% (5) had alterations in the profile, 20% hypothyroidism and 80% hyperthyroidism, as in the case of our patient and in 46% of the cases were absent. It is worth noting that 80% (12) presented elevation of Ca 125 with a range of 149U / ml to 3803U / ml, as we can observe the oscillation of Ca 125 is very wide.

There is not much association between elevation of Ca 125 and pleural effusion; as there are cases that presented massive effusion with low elevation of Ca 125 and the case reported with a higher elevation of Ca125 (3803u / ml) presented only a small amount of pleural effusion; however in the association with ascites the opposite occurs; since the case with higher levels of Ca 125, if present large amounts of ascites and the case reported with lower levels of Ca 125 (149u / ml) present little amount of ascites; (2639.9u / ml) and a large amount of ascitic fluid (4250ml), but not with pleural effusion (400ml); so we could conclude that the elevation of Ca 125 is more in relation to large amounts of ascites.

100% of the cases submitted after surgical treatment, without requiring another type of management; of which 5 had salpingo-ferectomy; 24 total abdominal hysterectomy with salpingooferectomy and 6 total abdominal hysterectomy, salpingooferectomy combined with another procedure.

Only two cases, including ours (86.6%), presented as a renal complex cyst association. Associations of Pseudo Meigs syndrome with tumors of origin other than ovary have been reported; such as renal tumors, our patient had left adrenal adenoma and left kidney complex cyst;

apparently had no association with the clinical picture; however, it would be worthwhile to further analyze this association by the presence of case reports very similar to

this one where mention is made of the presence of Struma Ovarii, Pseudo Meigs syndrome and the presence of renal cysts as findings.²⁵

Table 2: Postoperative features of Struma Ovarii associated with pseudo-Meigs syndrome and elevated levels of Ca 125.

Author	Treatment	Size tumor (CM)	Uni or bilateral	Ca 125 (U/ml) Postoperative	Others
Hurlow et al	BSO	7.5x6.8x4.7	Left	NA	NA
Mantouvalos et al	TAH, BSO	15	Left	NA	NA
Amr et al	TAH, BSO, partial omentectomy	12x9x6	Right	NA	NA
Bethune et al	TAH, BSO, infracolic omentectomy	9x5x5	Right	Normal levels	NA
Zannoni et al	TAH, BSO, omentectomy, multiple peritoneal biopsies, pelvic lymph node sampling	12x9	Left	22	Malignant
Loizzi et al	RSO	7x7	Right	Normal levels	NA
Uehara	TAH, BSO	7	Left	25	NA
Obeidat et al	TAH, BSO and omentectom	10x15x8	Right	NA	NA
Mitrou et al	TAH, BSO, infracolic omentectomy and lymph node sampling	22x23x10	Left	Normal levels	Left renal cyst of 15cm
Rana et al	TAH, BSO and partial omentectomy	Left: 7.5x5.5x4 Right:2x1.5x1	Bilateral	Normal levels	NA
Mostaghel et al	TAH, BSO	9	Right	12.5	NA
Obeidat et al	LSOI	15x14	Left	Normal levels	NA
Joan et al	BSO	8x5	Left	Normal levels	NA
Chengjuan et al	TAH, BSO	7x5	Right	609.6	NA
Current report	RSO	10x8x8	Right	70.6	Adrenal Adenoma, left cyst complex kidney right

*RSO: right salpingo-oferectomy; *LSOI: left salpingo-oferectomy; *BSO: bilateral salpingo-oferectomy; *TAH: total abdominal hysterectomy

CONCLUSION

Struma Ovarii is a rare ovarian tumor and even more associated with Pseudo-Meigs Syndrome and elevation of Ca 125. Our patient had recurrent and progressive ascites of unclear etiology. Paracentesis produced serous fluid that was negative for malignancy. However, in the context of a complex ovarian mass in a postmenopausal woman, elevation of CA 125 level, ascites and pleural effusion, ovarian malignancy should be excluded. Surgical excision of the ovarian tumor produced an immediate and dramatic resolution of both pleural effusion and ascites.

This case report emphasizes that there are benign gynecological conditions that may present clinical, ultrasound and biochemical symptoms suggestive of malignancy; so it is necessary to carry out a detailed study of them, in order to arrive at a correct diagnosis.

Funding: No funding sources

Conflict of interest: None declared

Ethical approval: The study was approved by the Institutional Ethics Committee

REFERENCES

1. Ikeuchi T, Koyama T, Tamai K, Fujimoto K, Mikami Y, Konishi I et al. CT and MR features of struma ovarii. *Abdom Imaging.* 2011.
2. Ferrero A, Fernández-González C, Fernández-Corona A, Salas JS, Carriles R, Hernandez Rodriguez JL. Struma ovarii: un tumor ovárico infrecuente. *Clin Invest Ginecol Obstet.* 2003;30:270-2.
3. Roth LM, Miller AW, Talerma A. Typical thyroid-type carcinoma arising in struma ovarii: a report of 4 cases and review of the literature. *Int J Gynecol Pathol.* 2008;27(4):496-506.
4. Devaney K, Snyder R, Norris HJ, Tavassoli FA. Proliferative and histologically malignant struma ovarii:

- a clinicopathologic study of 54 cases. *Int J Gynecol Pathol.* 1993;12(4):333-343.
5. Kurman RJ, Ellenson LH, Ronnett BM Blaustein's Pathology of the Female Genital Tract. Springer US. 2012.
 6. Roth LM, Talerman A. Recent advances in the pathology and classification of ovarian germ cell tumors. *Int J Gynecol Pathol.* 2006;25(4):305-320.
 7. Shen J, Xia X, Lin Y, Zhu W, Yuan J. Diagnosis of struma ovarii with medical imaging. *Abdom Imaging.* 2011;36:627-631.
 8. Izumi T, Araki Y, Satoh H. A case report of postoperative thyroid crisis accompanied with struma ovarii. (Japanese) Masui. 1990;39:391.
 9. Meigs JV, Cass JW. Fibroma of the ovary with ascites and hydrothorax, with a report of seven cases. *Am J Obstet Gynecol.* 1937;33:249-67.
 10. Jimerson SD. Pseudo-Meigs' syndrome: an unusual case with analysis of the effusions. *Obstet Gynecol.* 1973;42:535-7.
 11. Loizzi V, Cormio G, Resta L, Fattizzi N, Vicino M, Selvaggi L. Pseudo-Meigs syndrome and elevated CA125 associated with struma ovarii. *Gynecol Oncol.* 2005;97:282-4.
 12. O'Connell GJ, Ryan E, Murphy KJ, Prefontaine M. Predictive value of carbohydrate antigen-125 for ovarian carcinoma in patients presenting with pelvic masses. *Obstet Gynecol.* 1987;70:930-2.
 13. Huh JJ, Montz FJ and Bristow RE. Struma ovarii associated with pseudo-Meigs' syndrome and elevated serum CA 125. *Gynecol Oncol.* 2002;86:231-4.
 14. Obeidat BR, Amarin ZO. Struma ovarii with pseudo-Meigs' syndrome and elevated CA125 levels. *J Obstet Gynaecol.* 2007;27:97-98.
 15. Paladini D, Vassallo M, Sglavo G, Nappi C. Struma ovarii associated with hyperthyroidism, elevated CA 125 and pseudo- Meigs syndrome may mimic advanced ovarian cancer. *Ultrasound Obstet Gynecol.* 2008;32:237-8.
 16. Van de Moortele K, Vanbeckevoort D, Hendrickx S. Struma ovarii: US and CT findings. *JBR-BTR.* 2003;86:209-10.
 17. Roth LM, Talerman A. The enigma of struma ovarii. *Pathology.* 2007;39(1):139-146.
 18. Jung SI, Kim YJ, Lee MW, Jeon HJ, Choi JS, Moon MH. Struma ovarii: CT findings. *Abdom Imaging.* 2008;33(6):740-3.
 19. Timmerman D, Moerman P, Vergote I. Meigs' syndrome with elevated serum CA 125 levels: two case reports and review of the literature. *Gynecol Oncol.* 1995;59:405-8.
 20. Kempers RD, Dockerty MB, Hoffman DL, Bartholomew LG. Struma ovarii: ascitic, hyperthyroid, and asymptomatic syndromes. *Ann Intern Med.* 1970;72:883-93.
 21. Amr SS, Hassan AA. Struma ovarii with pseudo-Meigs' syndrome. *Eur J Obstet Gynecol Reprod Biol.* 1994;55:205-8.
 22. Rim SY, Kim SM, Choi HS. Struma ovarii showing clinical characteristics of ovarian malignancy. *Int J Gynecol Cancer.* 2005;15(6):1156-9.
 23. Loizzi V, Cappuccini F, Berman ML. An unusual presentation of struma ovarii mimicking a malignant process. *Obstet Gynecol.* 2004;100(5 Pt 2):1111-2.
 24. Mui MP, Tam KF, Tam FK, Ngan HY. Coexistence of struma ovarii with marked ascites and elevated CA-125 levels: case report and literature review. *Arch Gynecol.* 2009 May 1;279(5):753-7.
 25. Chiara ST, Franklin CB, Luiz CF. Pseudo-Meigs' syndrome associated to renal pelvis tumor. *Int Braz J Urol.* 2005;31:256-8.
 26. Hurlow RA, Greening WP, Krantz E. Ascites and hydrothorax in association with struma ovarii. *Br J Surg.* 1976;63:110-2.
 27. Mantouvalos C, Metallinos C, Gouskos A. Struma ovarii with Meigs' syndrome. *Aust N Z J Obstet Gynaecol.* 1982;22:101-2.
 28. Bethune M, Quinn M, Rome R. Struma ovarii presenting as acute pseudo-Meigs syndrome with an elevated CA 125 level. *Aust N Z J Obstet Gynaecol.* 1996;36:372-3.
 29. Zannoni GF, Gallotta V, Legge F, Tarquini E, Scambia G, et al. Pseudo- Meigs' syndrome associated with malignant struma ovarii: a case report. *Gynecol Oncol.* 2004;94:226-8.
 30. Uehara T, Sawada M. Struma ovarii associated with Meigs syndrome. *Jpn J Clin Oncol.* 2007;37:73.
 31. Mitrou S, Manek S and Kehoe S. Cystic struma ovarii presenting as pseudo-Meigs' syndrome with elevated CA125 levels. A case report and review of the literature. *Int J Gynecol Cancer.* 2008;18:372-5.
 32. Rana V, Srinivas V, Bandyopadhyay S, Ghosh SK, Singh Y. Bilateral benign non functional struma ovarii with Pseudo-Meigs' syndrome. *Indian J Pathol Microbiol.* 2009 Jan 1;52(1):94.
 33. Mostaghel N, Enzevaei A, Zare K, Fallahian M. Struma ovarii associated with Pseudo-Meig's syndrome and high serum level of CA 125; a case report. *J Ovarian Res.* 2012;5(1):10.
 34. Obeital R, Perre TJ, Saidi SA. Struma Ovarii Associated with Pseudo-Meigs' syndrome and elevated serum CA 125: a case report and literature review. *Gynecol Obstet.* 2012;2:4.
 35. Andrés Cordón JF, Pinal Fernández I, Willekens Morales R, Freixa A. Recurrent pleural effusion and marked elevation of CA-125 in a patient with a pseudo Mend syndrome secondary to an ovarian struma. *Med Clin (Barc).* 2013;140(5):235-9
 36. Jin C, Dong R, Bu H, Yuan M, Zhang Y, Kong B. Coexistence of benign struma ovarii, pseudo-Meigs' syndrome and elevated serum CA 125: Case report and review of the literature. *Oncology Letters.* 2015;9(4):1739-42.

Cite this article as: Morales OA, Araiza JJ, Dominguez TPA, Guzman RM, Barbabosa JA, Sosa MIT. Struma Ovarii associated with Pseudo-Meigs Syndrome and elevated serum Ca 125: Case report and literature review. *Int J Reprod Contracept Obstet Gynecol* 2018;7:336-41.