

DOI: <http://dx.doi.org/10.18203/2320-1770.ijrcog20180935>

Case Report

Successful laparoscopic assisted myomectomy of a gigantic 9.4 kg uterine parasitic myoma: a case report and review of literature

B. B. Dash*, Anuradha Kapur, Anupama Bahadur

Department of Obstetrics and Gynecology, Max Superspeciality Hospital, New Delhi, India

Received: 03 January 2018

Accepted: 03 February 2018

***Correspondence:**

Dr. B. B. Dash,

E-mail: bishulee@gmail.com

Copyright: © the author(s), publisher and licensee Medip Academy. This is an open-access article distributed under the terms of the Creative Commons Attribution Non-Commercial License, which permits unrestricted non-commercial use, distribution, and reproduction in any medium, provided the original work is properly cited.

ABSTRACT

Uterine leiomyomas are the most common benign tumours of the female pelvis affecting around 25-30% women of reproductive age. A case of successful laparoscopic assisted myomectomy in a giant uterine parasitic myoma is presented. A 42-year nulliparous morbidly obese lady presented with an Ultrasound diagnosis of a large uterine mass, detected during routine health check-up. MRI revealed a giant uterine pedunculated myoma of size 35 × 28 × 18 cm arising from the fundus and a 6 × 7 cm posterior wall myoma. After counselling the patient regarding surgical and anaesthesia risk, need of hysterectomy and laparotomy, laparoscopic myomectomy was planned. Laparoscopic findings revealed an exceptionally large parasitic fundal myoma filling the whole abdominal cavity and another 7 × 6 cm subserous myoma. main technical challenge was to tackle the big feeding vessels from the omentum providing massive blood supply to the gigantic tumor. Laparoscopic myomectomy was completed successfully using harmonic ace for coagulating the giant feeding vessels from the omentum. As the size of myoma was too big to put in the morcellation bag, so specimen retrieval was done through small incision and manual morcellation. The weight of the specimen was 9.4 Kg. This case emphasizes that size does not pose a limit to removing these gigantic myomas laparoscopically when surgical expertise and good anaesthesia facility is available. This is the case of largest myoma managed laparoscopically.

Keywords: Giant uterine myoma, Laparoscopy, Morcellation, Myomectomy

INTRODUCTION

Uterine leiomyomas are the most common benign tumours of the female pelvis affecting around 25-30% women of reproductive age. More than 50% patients are asymptomatic.¹ Management of symptomatic myoma depends on the patient's age, size and location of the myoma and future fertility issues.

Myomectomy is the best option in women requiring further fertility and uterine conservation. The advantages of laparoscopic approach are well proven and include smaller incision, shorter hospital stay, less subjectively reported postoperative pain, faster recovery and better

assessment of the abdominal organs.² Limitations to laparoscopic approach include surgical expertise and need of suturing. Power morcellation further adds to the advantages of minimally invasive surgery to remove large myomas. Laparoscopic approach to huge myomas remains controversial and technically challenging.³ We present a case of asymptomatic giant parasitic myoma that was removed successfully through laparoscopy.

CASE REPORT

A 42-year nulliparous woman presented with diagnosis of a large uterine mass diagnosed incidentally on USG during routine health check-up.

Patient was asymptomatic and had no symptoms pertaining to this large myoma. On examination, patient was morbidly obese with weight of 117 Kg and BMI 42.8 kg/m². Abdominal examination revealed a large uterine mass equal to term size gravid uterus with restricted mobility. To confirm the diagnosis, MRI was done which revealed a giant 35 × 28 × 18 cm subserous fibroid uterus arising from uterine fundus and another 7 × 6 cm subserous myoma in the posterior uterine wall (Figure 1).

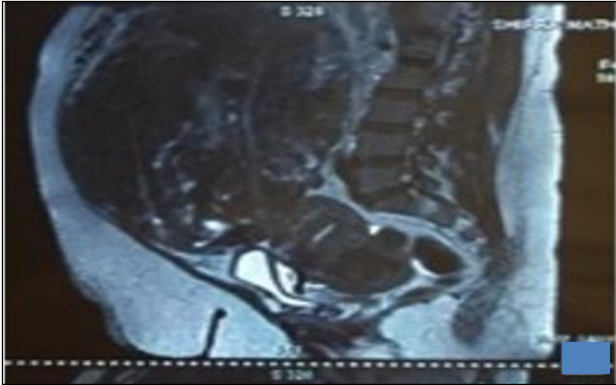


Figure 1: MRI abdomen showing the gigantic myoma filling the whole abdomen and another 7 × 6 cm posterior wall myoma.

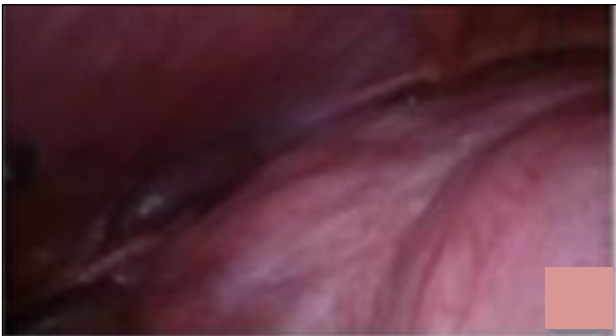

Figure 2: Laparoscopic finding showing large uterine mass filling the whole abdominal cavity.

The large myoma was extending up to hepatic surface displacing small intestinal loops and pancreas superiorly, retroperitoneal structures posteriorly and urinary bladder anteriorly. Her past medical and gynecological history was unremarkable.

The case was challenging in terms of gigantic size of myoma and route of surgery in this morbidly obese patient. After discussing the options with the patient, complete pre-anesthetic investigations and check-up was done. Laparoscopic myomectomy was planned to keep adequate blood products ready. The need and risk of laparotomy and hysterectomy was explained. Since putting the primary trocar above the fibroid was not possible, it was decided to put the primary port supraumbilically mid-way between upper and lower margin of fibroid so that uterine attachment and feeding vessels

can be visualized properly. Intra-operative findings revealed an exceptionally large myoma arising from uterine fundus and filling the entire abdomen (Figure 2). Manipulation of myoma and visualization of its attachment to uterus was a big challenge (Figure 3).

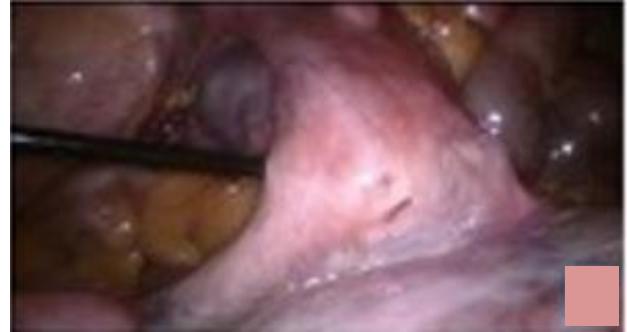

Figure 3: Uterine attachment of the myoma.

Another big challenge was large multiple feeding vessels coming from omentum which were the main source of blood supply to this giant parasitic myoma. The uterine attachment (about 5 cm pedicle), bilateral adnexa and other pelvic organs were visualized. Dilute vasopressin (20 units in 200 ml normal saline) was injected into the myometrium at the uterine attachment of myoma. The myoma was separated from the uterus using harmonic scalpel (Ethicon Endo-Surgery Inc, Cincinnati, OH, USA) and traction by myoma screw along with counter traction on the uterus. Myoma base was sutured using 1-0 V-loc unidirectional barbed suture (Covidien, UK). The challenge we faced while operating was the large serpentine feeding vessels (5-10 mm in diameter) from the omentum (Figure 4). These feeders were coagulated with bipolar coagulation and cut with harmonic scalpel.

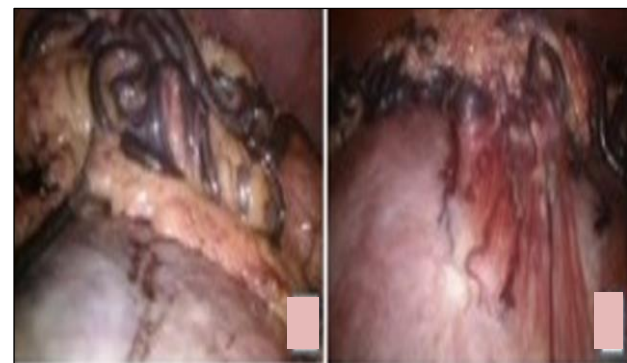

Figure 4: Large serpentine feeding vessels from omentum providing blood supply to the giant parasitic myoma

Next big challenge was to remove this giant myoma. Putting the myoma into bag was not possible due to huge size. Keeping in mind the risk of morcellation related complications, decision was taken for manual morcellation. Lower port incision was enlarged to about 3 cm length and manual morcellation was done. At the end

laparoscopy was done to check any residual pieces of myoma.

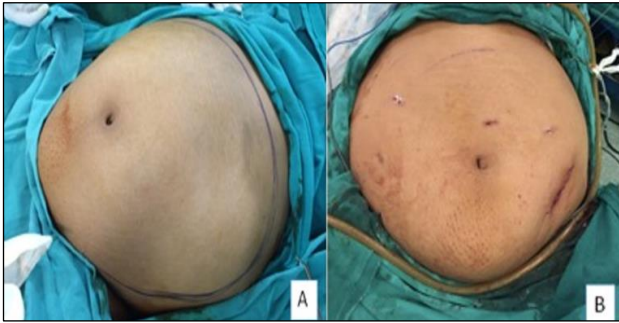


Figure 5: (a) Pre-operative picture of abdomen showing margins of myoma as marked. (b) Post-operative picture of abdomen.

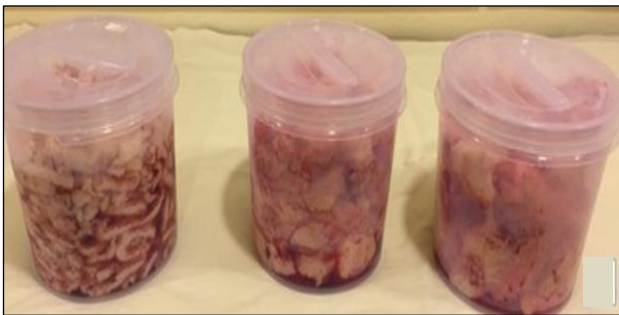

Figure 6: Morcellated pieces of myoma weighing 9.4 kg.

The procedure was completed in 4 hours with a blood loss of 700 ml. The weight of the specimen was 9.4 kg. Despite the difficulties faced there was no major intraoperative complications. Postoperative period was

uneventful, and patient did not receive any blood transfusion. The patient was discharged after 48 hours. The final histopathological report was compatible with the diagnosis of a uterine leiomyoma. Pre-op and post op pictures of abdomen are shown in Figure 5. Figure 6 shows the morcellated pieces of myoma weighing 9.4 kg. The case has been approved by our hospital Institutional Review Board (IRB).

DISCUSSION

A myoma weighing 9.4 kg, filling the entire abdomen and successfully removed laparoscopically has not been reported in literature so far. Major hurdles and challenges in removing a gigantic myoma of this size are difficulties in finding the uterine attachment, finding cleavage plane, narrow operating space, specimen retrieval, repairing the myometrial defect, increased operative time, vascular injury to adjacent structures and conversion to laparotomy. Surgical options and approaches are not standardized, and the appropriate management of these very large myomas is complex and requires exceptional surgical skill, laparoscopic suturing and anaesthesia back up.³ Laparoscopic myomectomy remains the gold standard of treatment for women harboring myomas that are in their reproductive age, infertile and wish to conserve their uteri. The removal of giant uterine leiomyomas is very rare, and literature is sparse with few case reports, largest measuring 21 cm and weighing 3400 g.⁴ Yoon et al demonstrated the feasibility and efficiency of laparoscopic approach to large myomas and in their prospective study of 51 patients the largest removed myoma was 15.2 cm.⁵ Table 1 shows the large myomas documented in literature which have been removed successfully through laparoscopic route. Our's is the largest myoma among all the cases documented in literature removed successfully so far by laparoscopy.

Table 1: Large uterine myomas removed laparoscopically.

Authors	No. of patients	Size of myoma	Procedure	Weight of myoma
Sinha et al ⁴	Case series	21 cm	Laparoscopic myomectomy	3400 gm
Yoon et al ⁵	51 patients	15.2 cm	Laparoscopic myomectomy	795 gm
Kavallaris et al ¹⁰	Case report	18 cm	Laparoscopic myomectomy	1200 gm
Ovali S et al ¹¹	Case report	25 cm	Laparoscopic myomectomy	1250 gm
Aksoy H et al ³	Case report	17 cm	Laparoscopic myomectomy	2005 gm
Present case	Case report	33 × 28 × 18 cm	Laparoscopic myomectomy	9400 gm

One of the major concerns is the relationship of myoma with obesity and diabetes, where the common factor in this association is insulin resistance, elevated IGF-I and androgen levels.⁶ Due to the decreased hepatic production of sex hormone binding globulin (SHBG) results in an increased bioavailability of estrogens and androgens.⁷ In a study by He et al an increased risk of myomas was found in premenopausal women of Asian origin with a high BMI.⁸ BMI of the present case was 42.8 kg/m².

Another major concern in removal of large uterine myomas laparoscopically, is specimen retrieval. Morcellation can lead to inadvertent dispersal of myoma fragments in the abdominal cavity leading to benign and malignant complications e.g. parasitic myoma, disseminated leiomyomatosis and even occult malignancy and leiomyosarcoma. As such there is no method for predicting whether the myoma being removed is malignant so the US Food and Drug Administration

(FDA) issued a statement of warning in November 2014 against the use of laparoscopic power morcellators in women undergoing hysterectomy or myomectomy for fibroid uterus. In Bag morcellation techniques have been devised to combat the risk of disseminating occult sarcomatous leiomyoma fragments throughout the abdominal cavity.⁹ In present case, the myoma was too big to put into a morcellation bag. Manual morcellation was done keeping in mind the risk of occult malignancy in a giant myoma.

CONCLUSION

The case emphasizes that size does not pose a limit to removing these gigantic myomas laparoscopically when surgical expertise, efficient energy sources and anesthesia is available. This is the largest myoma removed successfully through laparoscopy as documented in literature.

Funding: No funding sources

Conflict of interest: None declared

Ethical approval: Not required

REFERENCES

1. Zimmermann A, Bernuit D, Gerlinger C, Schaefer M, Geppert K. Prevalence, symptoms and management of uterine fibroids: an international internet-based survey of 21,746 women. *BMC Womens Health*. 2012;12:6
2. Chittawar BP, Franik S, Pouwer AW, Farquhar C. Minimally invasive surgical techniques versus open myomectomy for uterine fibroids. *Cochrane Database Syst Rev*. 2014;10:CD004638.
3. Aksoy H, Aydin T, Özdamar Ö, Karadag ÖI, Aksoy U. Successful use of laparoscopic myomectomy to remove a giant uterine myoma: a case report. *J Med Case Rep*. 2015;9:286.
4. Sinha R, Hegde A, Warty N, Patil N. Laparoscopic excision of very large myomas. *J Am Assoc Gynecol Laparosc*. 2003;10(4):461-8.
5. Yoon HJ, Kyung MS, Jung US, Choi JS. Laparoscopic myomectomy for large myomas. *J Korean Med Sci*. 2007;22(4):706-12.
6. Okolo S. Incidence, aetiology and epidemiology of uterine fibroids. *Best Pract Res Clin Obstet Gynaecol*. 2008;22(4):571-88.
7. He Y, Zeng Q, Li X, Liu B, Wang P. The association between subclinical atherosclerosis and uterine fibroids. *PLoS One*. 2013;8(2):e57089-e57089.
8. He Y, Zeng Q, Dong S, Qin L, Li G, Wang P. Associations between uterine fibroids and lifestyles including diet, physical activity and stress: a case control study in China. *Asia Pac J Clin Nutr*. 2013;22(1):109-117
9. McKenna JB, Kanade T, Choi S, Tsai BP, Rosen DM, Cario GM, et al. The Sydney contained in bag morcellation technique. *J Minim Invasive Gynecol*. 2014;21(6):984-5.
10. Kavallaris A, Zygouris D, Chalvatzas N, Terzakis E. Laparoscopic myomectomy of a giant myoma. *Clin Exp Obstet Gynecol*. 2013;40(1):178-80.
11. Ovalı S, Zorlu CG. Laparoscopic Myomectomy of A Giant Myoma. *Zeynep Kamil Med Bull*. 2014;45:175-7.

Cite this article as: Dash BB, Kapur A, Bahadur A. Successful laparoscopic assisted myomectomy of a gigantic 9.4 kg uterine parasitic myoma: a case report and review of literature. *Int J Reprod Contracept Obstet Gynecol* 2018;7:1265-8.