

DOI: <http://dx.doi.org/10.18203/2320-1770.ijrcog20183000>

Case Report

A rare presentation of a pyosalpinx in a post-menopausal woman

Ashwin Rao*, Reddi Rani, Setu Rathod

Department of Obstetrics and Gynecology, Mahatma Gandhi Medical College and Research Institute, Puducherry, India

Received: 08 July 2018

Accepted: 13 July 2018

***Correspondence:**

Dr. Ashwin Rao,

E-mail: ashwinrao2404@gmail.com

Copyright: © the author(s), publisher and licensee Medip Academy. This is an open-access article distributed under the terms of the Creative Commons Attribution Non-Commercial License, which permits unrestricted non-commercial use, distribution, and reproduction in any medium, provided the original work is properly cited.

ABSTRACT

Primary fallopian tube carcinoma is a rare tumour of the female genital tract with an incidence of 0.1-1.8% of all genital malignancies, which is generally an intra-operative or a histological diagnosis. It is a tumour that resembles epithelial ovarian cancer. A 61-year-old postmenopausal woman presented with complaints of continuous bleeding per vaginum with history of loss of appetite and weight for 6 months. She was also a known diabetic and hypertensive. On examination, per abdominal, per speculum and per vaginal findings were unremarkable. A transvaginal ultrasonography done previously showed fluid in the endometrial cavity suggestive of hematometra/pyometra due to cervical stenosis. A fractional curettage done previously had shown strips of acanthotic squamous epithelium in the endocervical curetting. She underwent abdominal hysterectomy with bilateral salpingo ovariectomy. Histopathological findings were suggestive of primary fallopian tube adenocarcinoma. Hence the patient was advised chemotherapy followed by a second look laparotomy. Preoperative diagnosis of fallopian tube carcinoma is difficult due to the silent course of this neoplasm and is usually first appreciated at the time of operation or by a pathologist. The treatment approach is similar to that of ovarian carcinoma, and it should consist of a total abdominal hysterectomy with bilateral salpingo-ovariectomy, omentectomy and lymph node dissection from the pelvic and the para-aortic regions.

Keywords: Epithelial ovarian tumours, Gynaecological malignancies, Hydrops tubae profluens, Primary fallopian tube carcinoma, Pyosalpinx

INTRODUCTION

Primary fallopian tube carcinoma is a rare tumour of the female genital tract with an incidence of 0.1-1.8% of all genital malignancies, which is generally an intra-operative or a histological diagnosis.¹ It is a tumour that resembles epithelial ovarian cancer.

Primary Fallopian tube carcinoma is the rarest malignancy of the female genital tract and was first described by Renand in 1897.¹ Clinically and histologically (PFTC) resemble epithelial ovarian cancer (EOC), and it is difficult to distinguish from serious epithelial ovarian cancer or primary peritoneal serous

carcinoma during or after operation.² EOC is often diagnosed at an advanced stage, but PFTC is found more in an early stage, because of abdominal pain from tubal distension and a shorter history of symptoms in PFTC than in EOC.³ High parity has been reported to be protective, and use of oral contraceptives and pregnancy decreases the risk of PFTC.⁴ Most patients with PFTC are postmenopausal.

CASE REPORT

A 61 year old P3L3 sterilised postmenopausal woman presented with complaints of continuous bleeding per vaginum with history of loss of appetite and weight for 6

months. She was also a known diabetic and hypertensive. On examination, abdomen was soft and tenderness was elicited in the right iliac fossa and hypogastric region and per speculum was unremarkable. Per vaginally uterus felt atrophic and there was fullness in the right lateral fornix with associated tenderness. A transvaginal ultrasonography done previously showed fluid in the endometrial cavity suggestive of a right adnexal mass and uterine cavity and left ovary appeared normal. The Ca 125 antigen level was 62.20 U/ml (normal up to 35 U/ml). The Pap smear was within normal limits. A fractional curettage done previously had shown strips of acanthotic squamous epithelium in the endocervical curetting and no endometrial curetting were obtained. She was planned for abdominal hysterectomy with bilateral salpingo-ovariectomy and infracolic omentectomy. Intra op findings showed that uterus was of normal size with pyosalpinx of the right fallopian tube. The left tube and both ovaries appeared normal.

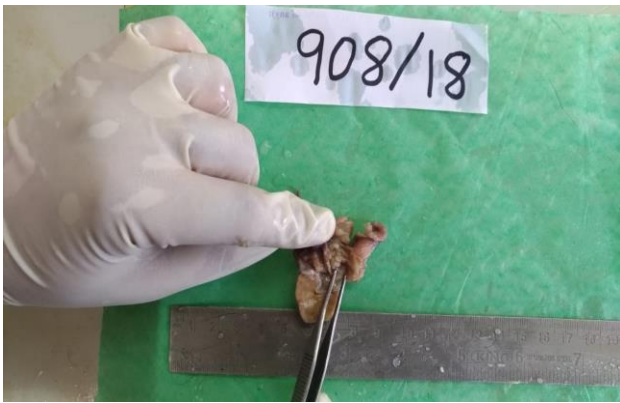

Figure 1: Histopathology - gross picture: right fallopian tube with the tumour.

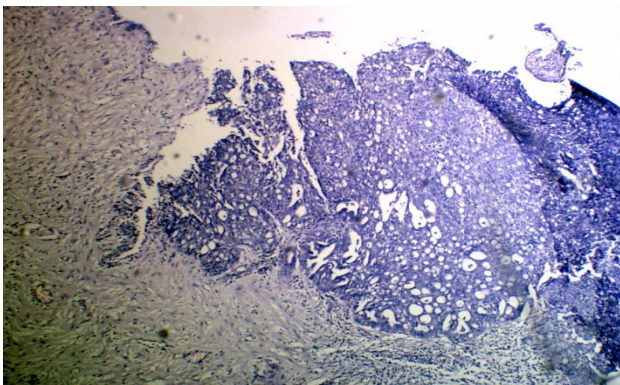


Figure 2: Histopathology - microscopic picture: showing poorly differentiated mucinous adenocarcinoma.

Cytology was negative for malignant cells. Histopathological impression was suggestive of primary right fallopian tube adenocarcinoma infiltrating the muscular wall and extending up to the serosa and the tumour being a poorly differentiated mucinous adenocarcinoma. The pathological stage classification

was pT1C2Nx. Post-operative CECT was done to assess the lymph node status and no lymph nodes were detected on radiograph. Hence the patient was advised adjuvant chemotherapy with carboplatin and paclitaxel.

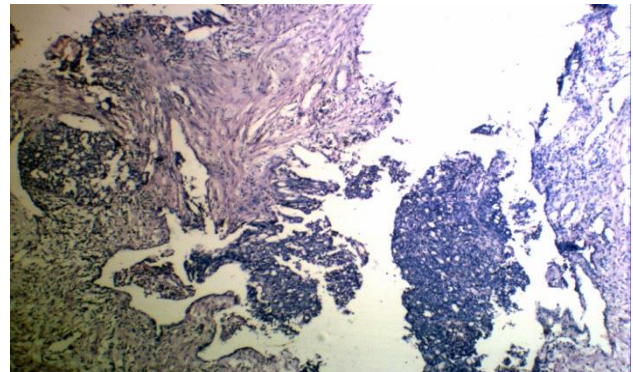


Figure 3: Histopathology-microscopic picture: showing nuclear atypia and increased nuclear cytoplasmic ratio.

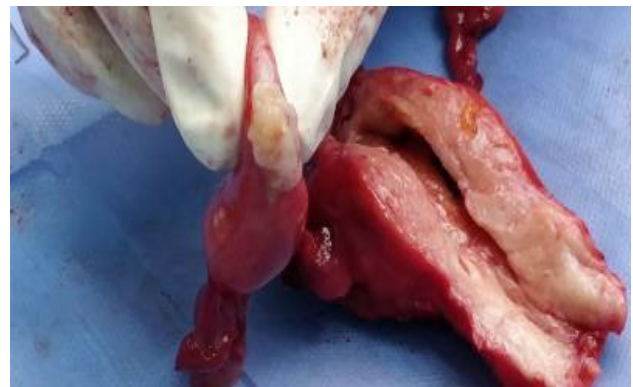

Figure 4: Post-operative cut section showing the normal endometrial cavity and right pyosalpinx.

DISCUSSION

PFTC most frequently seen between the fourth and sixth decades of life, with the median age being 55 years and range-17-88 years. Latzko's triad of symptoms, consisting of profuse intermittent serosanguinous vaginal discharge, pain which is colicky and relieved by discharge, and pelvic or abdominal mass has been reported in 15% of cases.^{5,6} Hydrops tubae profluens, a pathognomonic feature, implies intermittent blood stained or clear discharge and occurs in 5% of patients. PFTC is differentiated from epithelial ovarian cancer by the early onset of symptoms. PFTC may be suspected in postmenopausal spotting or bleeding with negative diagnostic curettage. Pap smear positivity occurs in 10%–36% of cases. The Pap smear may show atypical, suspicious, or poorly differentiated cells or glands which may alternate with a negative smear.⁷

The etiology of PFTC cancer is unknown. Hormonal, reproductive, and possibly genetic factors which may

increase the risk of epithelial ovarian cancer may also increase the risk of PFTC. Pregnancy, high parity and the use of oral contraceptives decreases the PFTC risk significantly.⁴ The occurrence of bilateral tumour is higher among infertile patients than in fertile patients and the prognosis is better among nulliparous women. PFTC has been found to be more associated among high-risk breast-ovarian cancer families with germ-line BRCA-1 and BRCA-2 mutations.⁸⁻¹¹

The common modes of imaging for suspected cases of gynecologic malignancies includes ultrasound, computed tomography (CT) scan and magnetic resonance imaging (MRI) of the abdomen. The ultrasound appearance of fallopian tubes is nonspecific similar to other pelvic diseases, such as tubo-ovarian mass, ovarian tumor and ectopic pregnancy showing a cystic mass with spaces and mural nodules or a multilobular mass with a cog-and-wheel appearance.¹²⁻¹⁴ Low-resistance vascular flow within the solid components and areas of neovascularization within the fallopian tube have been demonstrated which may aid in the diagnosis of primary fallopian tube carcinoma.¹⁵ Three-dimensional Doppler can show tubal wall irregularities such as papillary protrusions and pseudosepta and depictions of vascular abnormalities.¹⁶

On CT scan, a solid papillary intratubal mass allows for easy prediction of PFTC. MRI is considered a better method than CT or ultrasound for detecting tumour infiltration of extramural organs.⁴ The CA-125 level is raised. Ca-125 is a useful tumour marker for the diagnosis, assessment of response to treatment and detection of tumour recurrence during follow-up. 80% of patients with PFTC have elevated pretreatment serum levels of CA 125.⁴

The commonest types of primary fallopian tube carcinoma are serous and endometrioid type. It is difficult to differentiate primary fallopian tube carcinoma from epithelial ovarian carcinoma hence patients with at least one of the following criteria should have the diagnosis of primary fallopian tube carcinoma.¹⁷

- The main tumor is in the tube and arises from the endosalpinx.
- Histologically, the pattern reproduces the epithelium of the mucosa and often shows a papillary pattern.
- If the wall is involved, the transition between benign and malignant epithelium should be demonstrable.
- The ovaries and endometrium are either normal or contain less tumor than the tube.

The spread of tubal carcinoma is similar to that of epithelial ovarian carcinoma. The spread is generally by transcelomic exfoliation of cells which implant throughout the peritoneal cavity. Tumor spread can also occur by means of contiguous invasion, transluminal migration, and hematogenous spread.

The PFTC is richly permeated with lymphatic channels that drain into the para-aortic lymph nodes through infundibulopelvic lymphatics. An intrapelvic drainage into the superior gluteal lymph nodes has also been demonstrated. The existence of anastomoses with lymphatics of the uterus in the round ligament explains the development of inguinal node metastases.¹⁸ The nodal spread being more common in PFTC, lymph node sampling is a recommended procedure during surgical staging [19, 20] PFTC is often diagnosed at an earlier stage than EOC. In general, 20%–25% of patients have stage I, 20% have stage II, 45%–50% have stage III, and 5%–10% have stage IV.⁷

Surgery is the ideal treatment for PFTC and managed similar to ovarian cancer. Aggressive cytoreductive surgery with total abdominal hysterectomy, bilateral salpingo-oophorectomy, omentectomy and lymphadenectomy with removal of as much tumor as possible is preferable in case of advanced disease. If it is impossible to achieve optimal debulking despite maximum effort, surgery should be attempted again after a few courses of chemotherapy. Due to the increased tendency of lymphatic spread, a systematic pelvic and para-aortic lymphadenectomy is preferred to lymph node sampling. In young patients, fertility sparing surgeries can be considered for patients with an in-situ carcinoma and in those women with stage I and grade I carcinoma.⁷

Although radiotherapy was used traditionally as an adjuvant mode of therapy for PFTC, its role in the era of effective chemotherapy is less well defined and controversial. In view of its low efficacy and high rate of serious complications, the use of postoperative radiotherapy in the treatment of patients with PFTC is no longer recommended.

The current gold standard chemotherapy for EOC in North America is a platinum-taxane combination, and in Britain, it is platinum followed on relapse by a taxane. There are very few data that are extractable from the literature with regard to PFTC. Early-stage patients with tumors infiltrating the serosa or with pre- or intra-operatively ruptured tumors should receive chemotherapy.

Optimally cytoreduced patients with PFTC treated with a paclitaxel-based chemotherapy regimen have an excellent possibility of survival.²¹ Platinum-sensitive patients (relapse after 6 months) should be retreated with a platinum with or without paclitaxel, while platinum-refractory (progression during platinum-based therapy) or platinum-resistant (relapse within 6 months) patients should be treated with nonplatinum agents such as topotecan or liposomal doxorubicin.^{22,23}

Hormonal agents increasingly have been used in Primary fallopian tube carcinoma. The rationale is that tubal epithelia undergo changes with hormonal fluctuation during the menstrual cycle. Embryologically and

histologically the tubal epithelium is derived from the same source as the endometrial epithelium. Progestational agents have been used because of the known cyclic response of the normal tube to hormonal changes during the menstrual cycle.¹⁸

Stage of disease at the time of diagnosis is the most important factor affecting prognosis. In a large population-based tumor registry study of 416 women with PFTC, the reported 5-year survival rate by stage was as follows: stage I (n = 102), 95%; stage II (n = 29), 75%; stage III (n = 52), 69%; and stage IV (n = 151), 45%.²⁴ The presence or absence of invasion of the tubal wall, the depth of invasion, location of the tumor within the tube (fimbrial or nonfimbrial), histological grade of tumour and extent of lymphogenous spread advanced age [20, 25], serous versus endometrioid, bilaterality, positive peritoneal cytology, residual volume of the tumour after cytoreduction, HER-2/neu expression, p53 alteration, and elevated pretreatment CA-125 level.^{20,25}

CONCLUSION

Preoperative diagnosis of fallopian tube carcinoma is difficult due to the silent course of this neoplasm and is usually first appreciated at the time of operation or by a pathologist. It should be considered in differential diagnosis of peri and postmenopausal women who present with unexplained uterine bleeding, pelvic pain, adnexal mass, abnormal cervical smear and complicated pelvic inflammatory disease.

Funding: No funding sources

Conflict of interest: None declared

Ethical approval: Not required

REFERENCES

- Nordin AJ. Primary carcinoma of the fallopian tube: a 20-year literature review. *Obstet Gynecol Surv.* 1994;49(5):349-61.
- Tahiri Elousrouti L, Erragad FZ, Jayi S, Hammas N, Harmouch T. Primary Adenocarcinoma of the Fallopian Tube: Report of Two Cases. *J Clin Case Rep.* 2016;6:5.
- Moore KN, Moxley KM, Fader AN, Axtell AE, Rocconi RP, Abaid LN, et al. Serous fallopian tube carcinoma: a retrospective, multi-institutional case-control comparison to serous adenocarcinoma of the ovary. *Gynecol Oncol.* 2007;107:398-403.
- Riska A, Leminen A, Pukkala E. Sociodemographic determinants of incidence of primary fallopian tube carcinoma, Finland 1953-97. *Int J Cancer* 2003;104:643-5.
- Boutselis JG, Thompson JN. Clinical aspects of primary carcinoma of the Fallopian tube: a clinical study of 14 cases. *Am J Obstet Gynecol* 1971;111:98-101.
- Sedlis A. Carcinoma of the fallopian tube. *Surg Clin North Am* 1978;58:121-9.
- Lin CK, Chang CC, Pan SH, Yu MH. Primary fallopian tube carcinoma. *Obstet Gynecol Surv* 2005;60:247-52.
- Tonin P, Moslehi R, Green R, Rosen B, Cole D, Boyd N, et al. Linkage analysis of 26 Canadian breast and breast-ovarian cancer families. *Hum Genet.* 1995;95:545-50.
- Rose PG, Shrigley R, Wiesner GL. Germline BRCA2 mutation in a patient with fallopian tube carcinoma: a case report. *Gynecol Oncol.* 2000;77:319-20.
- Zweemer RP, Van Diest PJ, Verheijen RH, Ryan A, Gille JJ, Sijmons RH, et al. Molecular evidence linking primary cancer of the fallopian tube to BRCA1 germline mutations. *Gynecol Oncol* 2000;76:45-50.
- Aziz S, Kuperstein G, Rosen B, Cole D, Nedelcu R, McLaughlin J et al. A genetic epidemiological study of carcinoma of the fallopian tube. *Gynecol Oncol* 2001;80:341-5.
- Ajjimakorn S, Bhamarapravati Y, Israngura N. Ultrasound appearance of fallopian tube carcinoma. *J Clin Ultrasound* 1988;16:516-8.
- Subramanyam BR, Raghavendra BN, Whalen CA, Yee J. Ultrasonic features of fallopian tube carcinoma. *J Ultrasound Med.* 1984;3:391-3.
- Kol S, Gal D, Friedman M, Paldi E. Preoperative diagnosis of fallopian tube carcinoma by transvaginal sonography and CA-125. *Gynecol Oncol.* 1990;37:129-31.
- Kurjak A, Kupesic S, Ilijas M, Sparac V, Kosuta D. Preoperative diagnosis of primary fallopian tube carcinoma. *Gynecol Oncol.* 1998;68:29-34.
- Kurjak A, Kupesic S, Ilijas M, Sparac V, Kosuta D. Three-dimensional ultrasonographic and power Doppler characterization of ovarian lesions. *Ultrasound Obstet Gynecol.* 2000;16:365-71.
- Hu CY, Taymor ML, Hertig AT. Primary carcinoma of the fallopian tube. *Am J Obstet Gynecol.* 1950;59:58-67.
- Tamimi HK, Figge DC. Adenocarcinoma of the uterine tube: potential for lymph node metastases. *Am J Obstet Gynecol.* 1981;141:132-7.
- Baekelandt M, Kockx M, Wesling F, Gerris J. Primary adenocarcinoma of the fallopian tube. Review of the literature. *Int J Gynecol Cancer.* 1993;3:65-71.
- Gadducci A, Landoni F, Sartori E, Maggino T, Zola P, Gabriele A et al. Analysis of treatment failures and survival of patients with fallopian tube carcinoma: a cooperation task force (CTF) study. *Gynecol Oncol* 2001;81:150-9.
- Gemignani ML, Hensley ML, Cohen R, Venkatraman E, Saigo PE, Barakat RR. Paclitaxel-based chemotherapy in carcinoma of the fallopian tube. *Gynecol Oncol.* 2001;80:16-20.
- Bookman MA, Malmström H, Bolis G, Gordon A, Lissoni A, Krebs JB, et al. Topotecan for the treatment of advanced epithelial ovarian cancer: an open-label phase II study in patients treated after

- prior chemotherapy that contained cisplatin or carboplatin and paclitaxel. *J Clin Oncol* 1998;16:3345-52.
23. Hoskins P, Eisenhauer E, Beare S, Roy M, Drouin P, Stuart G, et al. Randomized phase II study of two schedules of topotecan in previously treated patients with ovarian cancer: a National Cancer Institute of Canada Clinical Trials Group study. *J Clin Oncol*. 1998;16:2233-7.
24. Kosary C, Trimble EL. Treatment and survival for women with Fallopian tube carcinoma: a population-based study. *Gynecol Oncol* 2002;86:190-1.
25. Alvarado-Cabrero I, Young RH, Vamvakas EC, Scully RE. Carcinoma of the fallopian tube: a clinicopathological study of 105 cases with observations on staging and prognostic factors. *Gynecol Oncol* 1999;72:367-79.

Cite this article as: Rao A, Rani R, Rathod S, A rare presentation of a pyosalpinx in a post-menopausal woman. *Int J Reprod Contracept Obstet Gynecol* 2018;7:3381-5.