

DOI: <http://dx.doi.org/10.18203/2320-1770.ijrcog20183361>

Case Report

Alveolar Rhabdomyosarcomatous endometrial polyp in a 70-year-old woman

Niranjanakesav¹, Sathiya Bama^{2*}, Radhakrishnan³, Arbind Kumar⁴

¹MBBS Student, Virchow Biopsy Centre, Thanjavur, Tamil Nadu, India

²Department of Pathology, IRT Perundurai Medical College and Hospitals (IRT-MPCH), Perundurai, Tamil Nadu, India

³Department of Pathology, Virchow Biopsy Centre, Thanjavur, Tamil Nadu, India

⁴Department of Pharmacology, IRT Perundurai Medical College and Hospitals (IRT-MPCH), Perundurai, Tamil Nadu, India

Received: 04 June 2018

Accepted: 16 July 2018

***Correspondence:**

Dr. Sathiya Bama,

E-mail: sathiyabamad@gmail.com

Copyright: © the author(s), publisher and licensee Medip Academy. This is an open-access article distributed under the terms of the Creative Commons Attribution Non-Commercial License, which permits unrestricted non-commercial use, distribution, and reproduction in any medium, provided the original work is properly cited.

ABSTRACT

This case report concerns a 70-year woman with a complaint of abnormal vaginal bleeding and foul smelling vaginal discharge of a short duration. Speculum examination revealed a huge polyp occupying the cervix and extending further downwards. On operation, it turned out to be an endometrial polyp arising from the fundus. Histologically the polyp showed classical features of alveolar rhabdomyosarcoma; confirmed immunochemically.

Keywords: Endometrial polyps, Rhabdomyosarcomatous, Sarcomatous neoplasm

INTRODUCTION

Rhabdomyosarcoma of uterus is an unusual sarcomatous tumor in gynecologic practice; and when seen it is associated as a component of carcinosarcoma; considered now as a classical example of epithelial mesenchymal transition tumor in human

Oncogenesis

As a distinct tumor, this is recognized long back in 1968 by Enter line and Horn later was analyzed in detail a large survey of 112 cases by Enzinger and Shiraki.^{1,2} The oldest patient in their series was 58 years.

Parham and Barr succinctly defined it as cellular sarcomatous neoplasm; containing a monomorphous population of primitive cells and showing skeletal muscle differentiation.³

CASE REPORT

The main complaints of this 70-year-old lady was foul smelling vaginal discharge for few months and post-menopausal bleeding for a month. Speculum revealed a fungating mass protruding into the cervix and vagina. Subsequently a total abdominal hysterectomy with BSO was done.

A large polypoidal mass (5 × 5 × 4 cm); fleshy in nature was arising from fundus and occupying the entire uterus and cervix. There were two other smaller polyps, were friable, necrotic and partly gangrenous at its tip. Microscopically it was moderately cellular; separated by thick fibrovascular septa. Pseudo alveolar spaces were seen throughout this neoplasm, constituting more than 50% of the tumor showing features consistent with alveolar rhabdomyosarcoma (ARMS) (Figure1). The non-cohesive cells contained in these spaces are mostly

nondescript. Classical rhabdomyoblasts with round morphology and abundant eosinophilic cytoplasm were noticed in their midst, strap and racquet shaped cells being rare. Bulbous cells were arranged at the periphery sticking to the walls of septa. In addition, in few sections a spindle shaped sarcomatous growth; with fasciculated pattern co-existed with the above but not mixing with predominantly primitive cells featuring leiomyosarcoma (LMS). This collision tumor showed multiple foci of coagulative necrosis with a mitotic rate of 10 per 10 high power field.

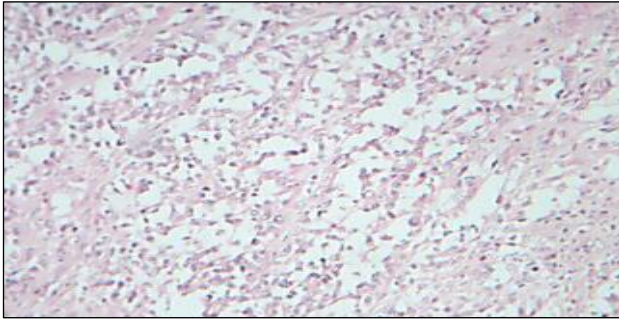


Figure 1: Low power view of ARMS: high power view to show rhabdomyoblastic differentiation.

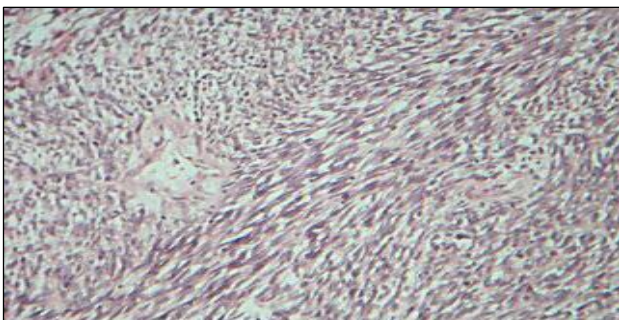


Figure 2: Medium power view of Leiomyosarcoma.

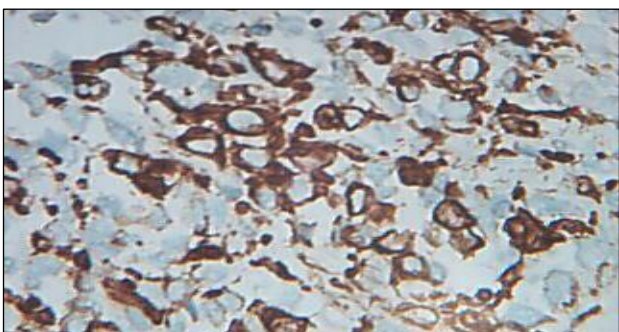


Figure 3: Myogenin nuclear positivity. Inset: Desmin cytoplasmic positivity

The abrupt transition between ARMS and low grade LMS was surprisingly distinct and morphologically heterogenous (Figure 2). Immunohistochemistry was done to confirm the nature of the neoplastic cells; proving thereby the histogenesis of this tumor conclusively. The tumor

cells were strongly positive for skeletal muscle markers like cytoplasmic desmin, muscle specific actin and nuclear positivity for myogenin D. Cytokeratin was positive for benign endometrial glands; distributed singly amidst malignant cells (Figures 3).

DISCUSSION

Endometrial polyps at this age are unusual; most often are due to Malignant Mixed Mullerian Tumor (MMMT) or rarely due to adenocarcinoma arising from EIN in endometrial polyp. The rarity of this tumor is well illustrated in the IRS study dealing with ARMS; in which only eight such cases were of genitourinary system.⁴ The histological hallmark of this neoplasm of pseudo-alveolar spaces amidst solidly arranged tumor cells; after downgrading its extent from 75% to 50% helped to diagnose this condition better and realistically. Another histological feature like detecting many forms of rhabdomyoblasts amidst nondescript cells arranged solidly as well as in pseudo alveolar spaces helped to diagnose this condition accurately and rule out other possibilities like small cell synovial sarcoma, malignant lymphoma, small blue cell tumors and solid carcinomas of epithelial origin.

After the advent of immunochemistry, the diagnosis can be firmly established by employing myogenic transcription factors; myogenin and Myo-D1. They are transcriptional regulatory proteins expressed early in muscle differentiation and display a nuclear staining pattern.⁵ In a recent review of 956 cases, myogenin and MyoD1 showed a sensitivity of 97% and specificity of 90% and 95% respectively.⁶

Myogenin is considered technically superior to other markers.⁷ Though Ober long ago recognized malignant mesenchymal tumors of uterus as homologous or heterologous or mixed, the number of case reported as mixed is still rare; particularly collision tumor as described in this patient.

Reported cases of ARMS involving uterus are rare and when compared with the case under discussion differed markedly in presentation. Fukanya reported a case of ARMS of uterine corpus in a 70-year-old woman with the tumor replacing the wall of the body of uterus by multiple friable nodules.⁸ She developed extensive metastases and died 12 months after surgery.

The second such case was in a 21yr old lady; unique for uterine inversion secondary to ARMS.⁹ The last such case was seen in a 44-year-old African woman, presenting with widespread disseminated tumor and involving all abdominal viscera.¹⁰ It is clear the case details recorded in our patient differed vastly from other reported cases and appear unique. We feel from our experience myogenin immunochemistry in future will help to discover many more cases and to plan for effective therapy in such patients.

CONCLUSION

Endometrial polyps due to Malignant Mixed Mullerian Tumor with features of ARMS is very rare. The classical picture of pseudo- alveolar spaces with scattered rhabdomyoblasts is characteristic feature. Myogenin immunohistochemistry help to discover many more cases and to plan for effective therapy in such patients.

Funding: No funding sources

Conflict of interest: None declared

Ethical approval: Not required

REFERENCES

1. Garcia L, Palacios J. Pathologic and molecular features of uterine carcinosarcomas. *Seminars in Diag Path.* 2010;27:274-86.
2. Enzinger FM, Shiraki. Alveolar Rhabdomyosarcoma. An analysis of 110 cases. *Cancer.* 1969;14:18-31.
3. Parham DM, Barr FG. Alveolar Rhabdomyosarcoma in WHO classification of tumours of soft tissue and Bone. Ed by Christopher DM. Fletcher, Julia Bridge, Pancras CW, Hogendron and Fredrik Mertens *Iarc;*2002:130-132.
4. Goldblum Tr, Folpe AC, Weiss SW. *Soft tissue tumors.* 6th ed. Elsevier; 2013:604.
5. Hornick JL. *Practical soft tissue Pathology. A diagnostic approach.* Eds. Hornick JL. Elsevier; 2013:207.
6. Hosoi H, Sugimoto T, Hayashi Y, Inaba T, Horii Y, Morioka H, et al. Differential expression of myogenic regulatory genes, MyoD1 and myogenin, in human rhabdomyosarcoma sublines. *Int J Canc.* 1992;50(6):977-83.
7. Cui S, Hano H, Harada T, Takai S, Masui F, Ushigome S. Evaluation of new monoclonal anti-MyoD1 and anti-myogenin antibodies for the diagnosis of rhabdomyosarcoma. *Pathol Int.* 1999;49(1):62-8.
8. Fukunaga M. Pure alveolar rhabdomyosarcoma of uterine corpus. *Pathol Int.* 2011;61:377-81.
9. Case AS, Kirby TO, Conner MG, Huh WK. A case report of rhabdomyosarcoma of the uterus associated with uterine inversion. *Gynecol Oncol.* 2005;96(3):850-3.
10. Odoi AT, Dassah ET, Darkey DE, Owusu-Afriyie O, Valkov AY. Advanced alveolar rhabdomyosarcoma of the uterus: a case report. *Afr J Reprod Health.* 2009;13(1).

Cite this article as: Niranjanakesav, Bama S, Radhakrishnan, Kumar A. Alveolar Rhabdomyosarcomatous endometrial polyp in a 70-year-old woman. *Int J Reprod Contracept Obstet Gynecol* 2018;7:3422-4.