

## Comparison of saline instillation sonography with trans vaginal sonography in abnormal uterine bleeding: a prospective study

Banishree Pati<sup>1\*</sup>, Rupa Vani K.<sup>1</sup>, Gowri A. L.<sup>2</sup>, Debendra Kumar Tripathy<sup>3</sup>

<sup>1</sup>Department of Obstetrics and Gynecology, Indira Gandhi Medical College and Research Institute, Pondicherry, India

<sup>2</sup>Department of Obstetrics and Gynecology, PHC, Valathi, Villupuram, Tamil Nadu, India

<sup>3</sup>Department of Anaesthesiology, Indira Gandhi Medical College and Research Institute, Pondicherry, India

**Received:** 29 October 2018

**Accepted:** 02 November 2018

**\*Correspondence:**

Dr. Banishree Pati,

E-mail: drbani1807@gmail.com

**Copyright:** © the author(s), publisher and licensee Medip Academy. This is an open-access article distributed under the terms of the Creative Commons Attribution Non-Commercial License, which permits unrestricted non-commercial use, distribution, and reproduction in any medium, provided the original work is properly cited.

### ABSTRACT

**Background:** Abnormal vaginal bleeding may be caused by an extensive spectrum of disorders, both gynecologic and non-gynecologic. Diagnostic accuracy of abnormal uterine bleeding is important for the management. Trans vaginal sonography (TVS) is one of the commonest investigation used for the diagnosis, but the diagnosis is not always accurate for all clinical conditions. Saline instillation sonography (SIS) has been shown to improve the diagnosis. Authors aimed to compare the TVS and SIS diagnosis with the final histopathological diagnosis.

**Methods:** Seventy-five patients with the complained of abnormal uterine bleeding attending outpatient department of a tertiary care institute were enrolled for the study. Trans vaginal sonography (TVS) and saline instillation sonography (SIS) was done on outpatient basis. The diagnosis was compared with final histopathological diagnosis, in term of diagnostic accuracy, sensitivity, specificity, positive predictive value and negative predictive value.

**Results:** Seventy-five patients who were enrolled for the study. Sixty-four patients underwent surgery and final histopathological diagnosis was established. Four patients SIS was not possible, data was analysed for sixty patients.

**Conclusions:** In SIS abnormal uterus diagnosis confidence was significantly improved (p value 0.001) when compared to TVS. The diagnosis of submucous myoma significantly improved (p=0.015) by SIS when compared to TVS. There was no significant difference between TVS and SIS diagnosis of Myoma remote from the endometrium (p=0.522), Adenomyosis (p=1), Focal endometrial abnormality (p=0.654) and Diffuse endometrial abnormality (p=1). The SIS sensitivity, specificity, PPV and NPV were either improved or same, when compare to TVS for all the diagnosis except for the diagnosis of focal endometrial abnormality.

**Keywords:** Abnormal uterine bleeding, Saline instillation sonography, Trans vaginal sonography

### INTRODUCTION

Abnormal vaginal bleeding is the most common reason for women to undergo an interventional gynecological procedure.<sup>1</sup> Abnormal vaginal bleeding may be caused by an extensive spectrum of disorders, both gynecologic and non-gynecologic. The International Federation of Gynecology and Obstetrics working group on menstrual disorders has proposed nine main categories, which are

arranged according to the acronym PALM-COIN: Polyp; adenomyosis; leiomyoma; malignancy and hyperplasia; coagulopathy; ovulatory dysfunction; endometrial; iatrogenic; and not yet classified. It is necessary to diagnose the cause of abnormal uterine bleeding accurately for further management.<sup>2</sup>

Diagnostic hysteroscopy combined with histological examination of an endometrial aspiration or biopsy is

consider the 'Gold standard' in the diagnosis of intrauterine abnormalities and is recommended in women with abnormal uterine bleeding.<sup>3</sup> However compared with ultrasound based diagnostic tools hysteroscopy is expensive and invasive and for the 50% of the women who actually have a normal uterine cavity it is in retrospect unnecessary.<sup>4</sup>

Trans vaginal sonography (TVS) performed to evaluate double-layer thickness of the endometrium were done for the work-up of patients with postmenopausal bleeding and abnormal uterine bleeding. These procedures were often inadequate for evaluation because approximately 50% of cases of abnormal uterine bleeding are caused by focal lesions such as polyps, submucosal fibroids, and focal endometrial hyperplasia. Focal lesions are more likely to be missed at routine endometrial biopsy because of sampling error and are under diagnosed at trans vaginal sonography (TVS) because of limitations of the double-layer thickness evaluation.<sup>5-8</sup>

Saline infusion sonohysterography (SIS) is a technique that involves placing a catheter into the uterine cavity through the cervical os to inject 5-20ml of sterile saline into the endometrial canal. The saline distends the cavity, pushing the opposed walls of the endometrium apart. The anechoic fluid is then juxtaposed against the echogenic endometrium, giving exquisite detail of the uterine lining.<sup>9</sup> It reliably distinguishes focal from diffuse endometrial pathologic conditions. Saline instillation sonography is well tolerated, requires no anesthesia, and has no reported complications.<sup>10</sup> This technique has been known by many names, including sonohysterography, hysterosonography, transvaginal sonography (TVS) with fluid contrast augmentation and finally Parson and Lense in 1993 coined the term Saline Infusion Sonohysterography (SIS).<sup>11</sup>

Against this background the present study is designed to compare the sensitivity, specificity, PPV and NPV of trans vaginal sonography with and without saline instillation.

## METHODS

After ethical clearance from institute Ethics committee seventy-five women above 18 years of age, who attended the OPD with complains of abnormal uterine bleeding were enrolled for the study. Patients with change in regularity, frequency of menses, duration or amount of bleeding during or in between periods were considered as abnormal uterine bleeding. Patient with pregnancy related complications and active pelvic inflammatory diseases were excluded from the study. After obtaining informed consent the patients were asked to empty the bladder. The pelvis was scanned in the sagittal and coronal or transverse planes with covered trans vaginal probe (HD-11, C5-9MHz, Philips), findings were noted and recorded.

Next the cervix was exposed and cleaned with an iodine swab. A sterile 8F/10F Foleys catheter was flushed with sterile saline solution and was inserted by grasping the tip with a ring forceps, carefully threading it into the endometrial canal to position the tip beyond the endocervical canal. The speculum was removed leaving the catheter in place. Then, the covered trans vaginal probe was inserted into the vagina, and continuous scanning in the sagittal and coronal or transverse planes was performed during instillation of sterile saline solution. Various amounts (10–20 ml or more) of saline solution was used depending on how much is retained within the canal. Two 20-mL syringes of saline solution were kept ready during the procedure to compensate any cervical leakage. The probe and catheter were removed after the procedure.

All the sonograms before and after instillation of saline was reviewed by a senior gynaecologist. Abnormal uterus was rated in a scale of 1 to 3 (1- uncertain; 2- probably yes; and 3- definitely yes) based on the confidence of diagnosis.

Authors considered sonographic features of individual lesions as per the description by Pearson and Lense. Typical leiomyoma or fibroid in sonography appears as well defined, homogenous lesion with same echogenic as myometrium and hypoechogenic in relation to endometrium. Authors have taken all the fibroids which did not had any continuation with endometrium as myoma remote from endometrial cavity (intramural, sub serosal). Myoma with an overlying layer of echogenic endometrium that distorts the endometrial myometrial interface was considered as submucous myoma. Ill-defined areas of myometrial echotexture, heterogenous and distorted myometrium, and a globular or enlarged uterus with asymmetry was considered for the diagnosis of Adenomyosis. Focal endometrial abnormality (polyp) usually appears as an ill-defined homogenous polypoid lesion that is isoechoic to the endometrium with preservation of endometrial myometrial interface. Diffuse endometrial abnormality usually appears as diffuse thickening of the echogenic endometrial stripe without focal abnormality, but occasionally focal hyperplasia can be seen. The findings were compared before and after instillation of saline and with the final pathological diagnosis.

## Statistical analysis

The quantitative variables were analyzed with t-independent test. As for the qualitative variables, the significance of their occurrence in the two groups were compared in terms of proportions. The proportions between the two groups were compared using chi-square test. Descriptive analysis was also included in the study as frequencies and percentages wherever it is necessary. In all comparisons, a P-value of <0.05 was considered to be statistically significant.

## RESULTS

Out of seventy-five patients sixty-four patients were operated and final morphological and histopathological diagnosis was established. Four patient's saline instillation sonography (SIS) could not be done, those cases were excluded from study. Final data was analysed for sixty patients.

The patients were between 32-52 years of age. The mean age was 42.37 and standard deviation 4.98. Largest diagnosis was myoma remote from endometrial cavity 24/60 (40%). 13/60 (21.7%) cases were submucous myoma, focal endometrial abnormality (polyp) was final diagnosis in 10/60 (16.7%). Diffuse endometrial abnormality was final diagnosis in 8/60 (13.3%) and 5/60 (8.3 %) cases were diagnosed as Adenomyosis (Figure 1).

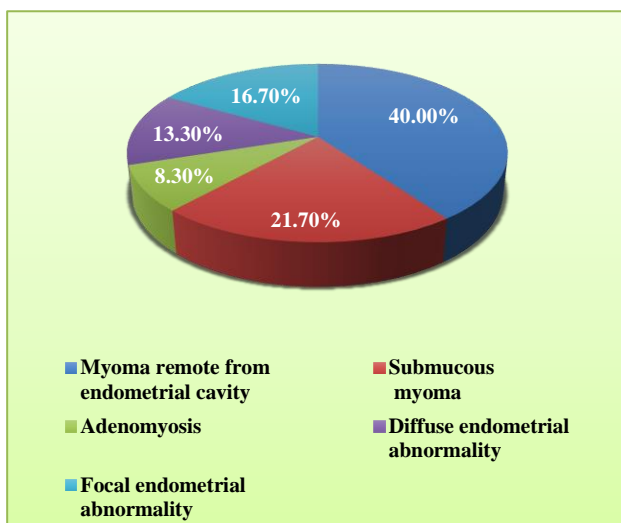


Figure 1: Final pathological diagnosis.

### TVS diagnosis

All type of positive findings (1-uncertain, 2-probably yes and 3-definitely yes) by Trans Vaginal Sonography were taken as positive for calculation. Based on the confidence of diagnosis. 37 cases were graded as 3, 22 cases were graded as 2 and one case was graded 1 (Figure 2).

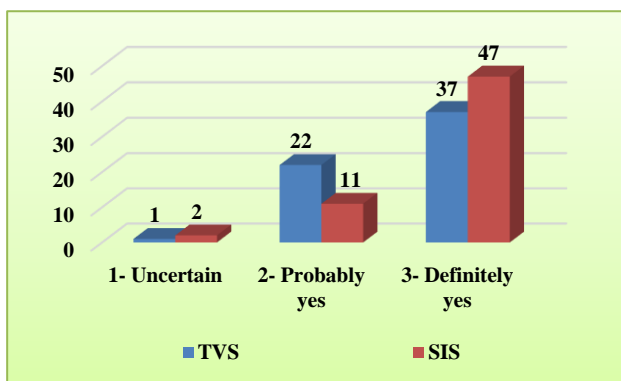


Figure 2: Comparison of confidence of diagnosis.

Maximum 28 cases were diagnosed as myoma remote from the endometrial cavity, out of which 19 cases (67.85%) diagnosis was confirmed by histopathological findings. 9 cases were diagnosed as submucous myoma, but only 3 (33.33%) were confirmed by histopathology. 6 cases were diagnosed as adenomyosis out of which 5 (100% of all adenomyosis) cases were confirmed by histopathology. Focal endometrial abnormality was the diagnosis in 7 cases out of which 6 cases were confirmed as final diagnosis. Diffuse endometrial abnormality was the finding in 10 cases, 7 cases were confirmed in final diagnosis.

All five cases (100%) of adenomyosis were correctly diagnosed by TVS. TVS finding was accurate in 6 cases (60.0%) of focal endometrial abnormality and 7 (87.5%) diffuse endometrial abnormality. Eight (61.5%) cases were wrongly diagnosed as myoma remote from the endometrial cavity by TVS. Five (55.5%) cases out of 9 cases diagnosed as submucous myoma, turned out to be myoma remote from endometrial cavity (Table 1).

### Sensitivity, specificity, PPV and NPV of TVS

TVS was highly sensitive and specific for the diagnosis of adenomyosis (100% and 98.18%) and diffuse endometrial abnormality (87.5% and 94.23%).

Though the specificity for the diagnosis of submucous myoma and focal endometrial abnormality was good (89.36% and 98.00%) the sensitivity was significantly poor (23.08% and 60%). Positive predictive value was low for submucous myoma (37.5%) and diffuses endometrial abnormality (70%) (Table 2).

### SIS diagnosis

The confidence of diagnosis of abnormal uterus significantly ( $p=0.001$ ) improved in SIS findings than the TVS. Forty-seven cases were graded as 3 (definitely yes), 11 cases were graded as 2 (probably yes) and 2 cases graded as 1 (uncertain) (Figure 2).

After taking all grades of positive findings into account, total 24 cases diagnosis was myoma remote from endometrial cavity. Out of which 22 cases (91.2%) diagnosis was confirmed by histopathological findings. 12 cases were diagnosed as Submucous myoma out of which 11(91.66%) cases were confirmed which was significantly improved than the TVS diagnosis ( $p$  value 0.015). One case turned out to be Myoma remote from endometrial cavity. Adenomyosis was the finding in 6 cases out of which 5 cases (100% of final diagnosis) were confirmed by histopathology. Focal endometrial abnormality was the diagnosis in 6 cases, 5 (50 % of final diagnosis) cases were confirmed by histopathological finding. 12 cases diagnosed as diffuse endometrial abnormality, out of which 7 cases were confirmed by histopathology 5 cases turned out to be Focal endometrial abnormality (Table 3).

**Table 1: TVS diagnosis versus final pathological diagnosis.**

TVS diagnosis		Final diagnosis					Total (n)
		Myoma remote from endometrial cavity	Submucous myoma	Adenomyosis	Focal endometrial abnormality	Diffuse endometrial abnormality	
Myoma remote from endometrial cavity	n	19	8	0	0	1	28
	% of final diag	79.20%	61.50%	0.00%	0.00%	12.50%	46.70%
Submucous myoma	n	5	3	0	1	0	9
	% of final diag	20.80%	23.10%	0.00%	10.00%	0.00%	15.00%
Adenomyosis	n	0	1	5	0	0	6
	% of final diag	0.00%	7.70%	100.00%	0.00%	0.00%	10.00%
Focal endometrial abnormality	n	0	1	0	6	0	7
	% of final diag	0.00%	7.70%	0.00%	60.00%	0.00%	11.70%
Diffuse endometrial abnormality	n	0	0	0	3	7	10
	% of final diag	0.00%	0.00%	0.00%	30.00%	87.50%	16.70%
Total	n	24	13	5	10	8	60

**Table 2: Sensitivity, specificity, PPV and NPV of TVS.**

TVS diagnosis	Sensitivity (95% CI)	Specificity (95% CI)	Positive predictive value (95% CI)	Negative predictive value (95% CI)
Myoma remote from endometrial cavity	70.83% (48.88-87.37)	75% (57.78-87.89)	65.38% (44.31-82.77)	79.41% (62.11-91.29)
Submucous myoma	23.08% (50.37-53.79)	89.36% (76.88-96.45)	37.50% (85.23-75.52)	80.77% (67.48-90.37)
Adenomyosis	100% (47.83-100)	98.18% (90.27-99.95)	83.33% (35.88-99.58)	100% (93.40-100.0)
Focal endometrial abnormality	60.00% (26.25-87.84)	98.00% (89.36-99.95)	85.71% (42.10-99.64)	92.59% (82.13-97.59)
Diffuse endometrial abnormality	87.50% (47.33-99.68)	94.23% (84.05-98.79)	70.00% (34.76-93.32)	98.00% (89.36-99.95)

**Table 3: SIS diagnosis versus final pathological diagnosis.**

SIS diagnosis		Final diagnosis					Total
		Myoma remote from endometrial cavity	Submucous myoma	Adenomyosis	Focal endometrial abnormality	Diffuse endometrial abnormality	
Myoma remote from endometrial cavity	n	22	1	0	0	1	24
	% of final diag.	91.70%	7.70%	0.00%	0.00%	12.50%	40.00%
Submucous myoma	n	1	11	0	0	0	12
	% of final diag.	4.20%	84.60%	0.00%	0.00%	0.00%	20.00%
Adenomyosis	n	1	0	5	0	0	6
	% of final diag.	4.20%	0.00%	100.00%	0.00%	0.00%	10.00%
Focal endometrial abnormality	n	0	1	0	5	0	6
	% of final diag.	0.00%	7.70%	0.00%	50.00%	0.00%	10.00%
Diffuse endometrial abnormality	n	0	0	0	5	7	12
	% of final diag.	0.00%	0.00%	0.00%	50.00%	87.50%	20.00%
Total	n	24	13	5	10	8	60

**Sensitivity, specificity, PPV and NPV of SIS**

Sensitivity, specificity, positive and negative predictive value for the diagnosis of Myoma remote from endometrial cavity, submucous myoma and Adenomyosis were very high in SIS findings. Though the specificity,

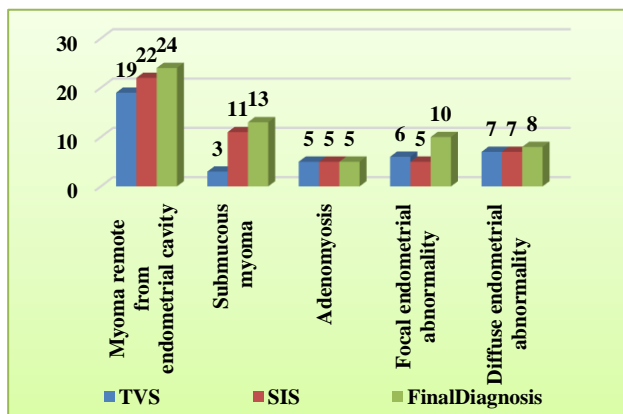
positive and negative predictive value were high for the diagnosis of focal endometrial abnormality the sensitivity was low (50%). Sensitivity, specificity and negative predictive value were good for diffuse endometrial abnormality, but positive predictive value was low (58.33%) (Table 4).

**Table 4: Sensitivity, specificity, PPV and NPV of SIS.**

SIS diagnosis	Sensitivity (95% CI)	Specificity (95% CI)	Positive predictive value (95% CI)	Negative predictive value (95% CI)
Myoma remote from endometrial cavity	91.67% (72.98-98.97)	94.44% (81.35-99.32)	91.67% (72.98-98.97)	94.44% (81.35-99.32)
Submucous myoma	84.62% (54.58-98.08)	97.87% (88.71-99.95)	91.67% (61.51-99.79)	95.83% (85.74-99.49)
Adenomyosis	100% (47.83-100)	98.18% (90.27-99.95)	83.33% (35.88-99.58)	100% (93.40-100.0)
Focal endometrial abnormality	50.00% (18.71-81.29)	98.00% (89.36-99.95)	83.33% (35.88-99.58)	90.74% (79.68-96.93)
Diffuse endometrial abnormality	87.5% (47.33-99.68)	90.38% (78.94-96.80)	58.33% (27.66-84.83)	97.92% (88.93-99.95)

**Comparison of TVS and SIS**

In SIS abnormal uterus diagnosis confidence was significantly improved (p value 0.001) when compared to TVS (Figure 3). The diagnosis of Submucous myoma significantly improved (p= 0.015) by SIS when compared to TVS. There was no significant difference between TVS and SIS diagnosis of Myoma remote from the endometrium (p=0.522), Adenomyosis (p=1), Focal endometrial abnormality (p=0.654) and Diffuse endometrial abnormality (p=1). The SIS sensitivity, specificity, PPV and NPV were either improved or same, when compare to TVS for all the diagnosis except for the diagnosis of focal endometrial abnormality. The sensitivity was markedly improved for the diagnosis of submucous myoma by SIS (Figure 3).



**Figure 3: Comparison of individual diagnosis.**

**DISCUSSION**

In the year 1984 Richman et al distend the uterine cavity with 70% dextran through a rigid cannulae while performing transabdominal sonography, later in the year 1986 Randolph et al used saline to distend the uterine cavity.<sup>12,13</sup> The use of fluid to distend the uterine cavity was based on the principle that the fluid enhances the details of sonography images (e.g. presence of amniotic fluid); the anechoic fluid juxtaposed against the echogenic endometrium giving exquisite details of the uterine lining and echogenic mass.<sup>9</sup>

Present study consisted of seventy-five patients out of which sixty-four patients underwent surgery and final histopathological diagnosis was established. Out of sixty-four, in four patients SIS could not be done and they were excluded from the study. Jorizzo et al have found that cervical stenosis, severe uterine anteversion, a lower uterine leiomyomas or endometrial masses can lead to failure of SIS.<sup>10</sup> The mean age of the patients was 42.37 years (32-52 years, SD 4.98), similar findings were reported by Varadarajan R et al.<sup>14</sup>

It has been demonstrated by Wolmen et al that the SIS done during proliferative phase (first 10 days) yields better result.<sup>15</sup> As it is not possible to time the SIS in abnormal uterine bleeding (AUB) and bleeding is not a contraindication for SIS, as observed by Berridge et al.<sup>9</sup> Authors did not time the TVS and SIS with any particular phase of the menstrual cycle. All present patients underwent TVS followed by SIS in the same sitting.



Although characteristics sonography features have been described for different uterine pathologies, wide range of appearances possible with significant overlap between the entities.<sup>16,17</sup> Any pathological abnormality in the uterus found during TVS and SIS was described as abnormal uterus and graded in a scale of three (1-uncertain, 2-probably yes and 3-definitely yes), based on the confidence of diagnosis. Authors found that more no (47/60, 78%) of diagnosis in the grade 3 by SIS, which was significantly ( $p=0.001$ ) better than TVS finding (37/60, 62%). This shows that the SIS definitely increases the confidence with which diagnosis can be made. Becker et al used similar subjective grading on a scale of 1-5 and they concluded that sonohysterography does provide additional information over transvaginal sonography alone and is an important adjunct to transvaginal sonography.<sup>18</sup>

In present patients Myoma remote from endometrial cavity was the diagnosis in 24 cases (40%), 13 cases (21.7%) were submucous myoma, focal endometrial abnormality was final diagnosis in 10 cases (16.7%). Diffuse endometrial abnormality was final diagnosis in 8 cases (13.3%) and 5 cases (8.3 %) were diagnosed as Adenomyosis. In present patients myoma remote from the endometrial cavity was correctly diagnosed in 79.2% (19/24) of cases by TVS, though statistically non-significant the diagnosis improved to 91.2% (22/24) with SIS. For this diagnosis TVS had Sensitivity 70.83%, specificity 75.00%, PPV 65.38%, NPV 79.41%. SIS significantly improved Sensitivity to 91.67%, specificity to 94.44% PPV to 91.67 % and NPV to 94.44%. Similar results were reported by Schwarzler et al, they calculated a sensitivity of 94%, specificity of 98%, PPV of 89% and NPV 99% by SIS, whereas in TVS sensitivity was 82%, specificity was 98%, PPV was 82% NPV was 96%.<sup>19</sup> Authors found that SIS can be better choice for the screening for the diagnosis of myoma remote from the endometrial cavity.

In present study submucous myoma was correctly diagnosed only in 23.1% (3/13) cases by TVS, but SIS significantly ( $P=0.015$ ) improved the diagnosis to 84.6% (11/13). TVS had a good specificity of 89.36% and NPV of 80.77%, but the Sensitivity and PPV were very poor 23.08% and 37.50% respectively. SIS improved all the parameters, Sensitivity to 84.62%, specificity to 97.87%, PPV to 91.67% and NPV to 95.83%. Epstein et al reported sensitivity of 80%, PPV of 80%, NPV of 98.63% by SIS whereas in TVS sensitivity was 33.34% PPV was 40% and NPV of 96%.<sup>20</sup> Goldstein et al has reported SIS sensitivity as 100% and specificity as 90% for the diagnosis of submucous myoma. Authors conclude that for the diagnosis of submucous myoma the SIS should be the first line of investigation, as SIS is good in diagnosis as well screening.<sup>21</sup>

In present study 8 cases (61.5%) were wrongly diagnosed as myoma remote from the endometrial cavity by TVS. The significant improvement in diagnosis of submucous

myoma by SIS can be explained by the fact that, submucous myomas projects into the uterine cavity, the presence of fluid in the cavity enhance the outline and helps in differentiating from other lesions. Similar observation has been made by Farquhar et al and Davis et al.<sup>17,22</sup>

TVS and SIS both correctly diagnosed all 5 cases of adenomyosis and both had wrongly diagnosed one case as adenomyosis, which turned out to be a submucous myoma. Both TVS and SIS had same sensitivity (100%), specificity (98.18%), NPV (83.33%) and PPV (100%). Authors conclude that both the TVS and SIS can be used for screening and diagnosis of Adenomyosis with equal confidence. Verma SK et al reported detection rate of adenomyosis by TVS 53%, SIS 85% and by MRI 96% respectively. They also mentioned that, confusion with fibroid is one of the most frequently encountered pitfalls in the diagnosis of adenomyosis.<sup>23</sup>

In present study, TVS diagnosed 60 % (6/10) and SIS diagnosed 50% (5/10) of focal endometrial abnormality correctly. The sensitivity, specificity, PPV, NPV of TVS was found to be 60%, 98%, 85.71% and 92.59% respectively, whereas for SIS the corresponding values were 50%, 98%, 83.33%, and 90.74%. The specificity was high enough to use either of the modality for diagnostic purpose, but it is not good enough for screening. Soares et al had quoted a very high success rate by SIS, (sensitivity, specificity, NPV and PPV all 100%).<sup>24</sup> Dueholm et al also quoted high sensitivity (99%), specificity (72%), PPV (85%) and NPV (98%).<sup>25</sup> But in present finding SIS parameters were even lower than the TVS finding. Cicinelli et al also quoted success rate for SIS similar to present finding, they quoted sensitivity of 58.3 %, specificity of 100%, PPV 100% and NPV 86.1%.<sup>26</sup> In present finding some cases which were missed by TVS were found by SIS and Vis a versa.

The wide variation in success rates of SIS and TVS for the diagnosis of focal endometrial abnormality can be explained by the factors which influences the success rate of each modality. The factors are size of the polyp (smaller polyps can be compressed by probe or saline), location (cervical polyp can be obscured by balloon of the catheter), multiple pathology and the phase of menstrual cycle (after 10 days mucosal fold or wrinkling also mimic like a polyp).<sup>9,27</sup> Most of the authors have concluded that SIS has a high success rate for intracavitary lesions. Authors found the same high success rate for submucous myoma, but it was low (50%) for focal endometrial abnormality (polyp).

There is a difference of opinion in literature about cut off thickness for the diagnosis of diffuse endometrial thickening. A meta-analysis study by Smith-Bindman found that with the use of a cutoff of 5 mm, 96% of endometrial carcinomas would be detected in postmenopausal patients with bleeding.<sup>28</sup> Dueholm et al reported sensitivity of 93%, specificity of 54%, PPV of

79% and NPV of 82% for TVS.<sup>25</sup> They have calculated sensitivity of 99%, specificity of 57%, PPV of 81% and NPV of 97% for SIS. In present study both TVS and SIS diagnosis was correct in 87.33% (7/8) of the final diagnosis. The sensitivity (87.5%), specificity (90.38%) and NPV (97.92%) were good and similar for both the diagnostic modality. Only the NPV value differed, it was 70% for TVS, 58.33% for SIS. Authors are of the opinion that either of the modality is good enough for screening as well as for diagnosis for diffuse endometrial abnormality.

Four cases (4/60, 6.66%) were wrongly diagnosed by both TVS and SIS. Two cases were diagnosed as myoma remote from endometrial cavity by both TVS and SIS, but final histopathological diagnosis was submucous myoma in one case and in the other the diagnosis was diffuse endometrial hyperplasia. In third case diagnosis was submucous myoma by both TVS and SIS, but the final diagnosis came as Myoma remote from the endometrial cavity. Fourth case was diagnosed as focal endometrial hyperplasias by TVS and SIS, but the final diagnosis was submucous myoma.

Bonnamy et al has described complications of SIS as infection, syncope and sever pain.<sup>29</sup> Authors did not find any such complications; present findings were in agreement with most of authors who have reported SIS as very safe procedure.

## CONCLUSION

Saline instillation into the uterine cavity provides additional information, it increases the confidence with which diagnosis can be made for abnormal uterus. Screening and diagnosis of submucous myoma is superior with saline instillation sonohysterography than transvaginal sonography. Saline instillation sonohysterography is equally effective for the diagnosis of myoma remote from endometrial cavity, adenomyosis and diffuse endometrial abnormality. For the diagnosis of focal endometrial abnormality transvaginal sonography and saline infusion sonohysterography should be considered complementary investigation. Future study with larger sample size adequately powered for individual diagnosis can be more conclusive.

*Funding: No funding sources*

*Conflict of interest: None declared*

*Ethical approval: The study was approved by the Institutional Ethics Committee*

## REFERENCES

1. Bronz L, Suter T, Rusca T. The value of transvaginal sonography with and without saline instillation in the diagnosis of uterine pathology in pre- and postmenopausal women with abnormal bleeding or suspect sonographic findings. *Ultrasound Obstet and Gynecol.* 1997;9(1):53-8.

2. Munro MG, Critchley HO, Fraser IS, FIGO Menstrual Disorders Working Group. The FIGO classification of causes of abnormal uterine bleeding in the reproductive years. *Fertil Steril.* 2011;95(7):2204-8.
3. Gimpelson RJ, Rappold HO. A comparative study between panoramic hysteroscopy with directed biopsies and dilatation and curettage. A review of 276 cases. *Am J Obstet Gynecol.* 1988;158(3 Pt 1):489-92.
4. Dijkhuizen FPHLJ, Vries LDD, Mol BWJ, Brölmann HAM, Peters HM, Moret E, et al. Comparison of transvaginal ultrasonography and saline infusion sonography for the detection of intracavitary abnormalities in premenopausal women. *Ultrasound Obstet Gynecol.* 2000;15(5):372-6.
5. O'Connell LP, Fries MH, Zeringue E, Brehm W. Triage of abnormal postmenopausal bleeding: a comparison of endometrial biopsy and transvaginal sonohysterography versus fractional curettage with hysteroscopy. *Am J Obstet Gynecol.* 1998;178(5):956-61.
6. Bree RL, Bowerman RA, Bohm-Velez M, Benson CB, Doubilet PM, DeDreu S, et al. US evaluation of the uterus in patients with postmenopausal bleeding: a positive effect on diagnostic decision making. *Radiol.* 2000;216(1):260-4.
7. Jain M, Chakraborty S. Evaluation of abnormal uterine bleeding with transvaginal sonography. *Int J Reprod Contracept Obstet Gynecol.* 2017;6:2794-9.
8. Tangri MK, Srivastava AK. Diagnostic accuracy of saline infusion sonography as compared to hysteroscopy in premenopausal women with abnormal uterine bleeding. *Int J Reprod Contracept Obstet Gynecol.* 2017;6:682-7.
9. Berridge DL, Winter TC. Saline infusion sonohysterography: technique, indications, and imaging findings. *J Ultrasound Med.* 2004;23(1):97-112.
10. Jorizzo JR, Riccio GJ, Chen MYM, Carr JJ. Sonohysterography: the next step in the evaluation of the abnormal endometrium. *Radiographics.* 1999;19(suppl 1):S117-30.
11. Parsons AK, Lense JJ. Sonohysterography for endometrial abnormalities: preliminary results. *J Clin Ultrasound.* 1993;21(2):87-95.
12. Richman TS, Viscomi GN, deCherney A, Polan ML, Alcebo LO. Fallopian tubal patency assessed by ultrasound following fluid injection. *Work in progress. Radiol.* 1984;152(2):507-10.
13. Randolph JF, Ying YK, Maier DB, Schmidt CL, Riddick DH, Randolph JR. Comparison of real-time ultrasonography, hysterosalpingography, and laparoscopy/hysteroscopy in the evaluation of uterine abnormalities and tubal patency. *Fertil. Steril.* 1986;46(5):828-32.
14. Varadarajan R, Sreekantha SM. Role of hysteroscopy in abnormal uterine bleeding in perimenopausal age group. *J Evol Med Dent Sci.* 2013;2(10):1504-9.

15. Wolman I, Groutz A, Gordon D, Kupferminc MJ, Lessing JB, Jaffa AJ. Timing of sonohysterography in menstruating women. *Gynecol Obstet Invest.* 1999;48(4):254-8.
16. Williams PL, Laifer-Narin SL, Ragavendra N. US of abnormal uterine bleeding. *Radiographics.* 2003;23(3):703-18.
17. Davis PC, O'Neill MJ, Yoder IC, Lee SI, Mueller PR. Sonohysterographic findings of endometrial and subendometrial conditions. *Radiographics.* 2002;22(4):803-16.
18. Becker E, Lev-Toaff AS, Kaufman EP, Halpern EJ, Edelweiss MI, Kurtz AB. The added value of transvaginal sonohysterography over transvaginal sonography alone in women with known or suspected leiomyoma. *J Ultrasound Med.* 2002;21(3):237-47.
19. Schwärzler P, Concin H, Bösch H, Berlinger A, Wohlgenannt K, Collins W, et al. An evaluation of sonohysterography and diagnostic hysteroscopy for the assessment of intrauterine pathology. *Ultrasound Obstet Gynecol.* 1998;11(5):337-42.
20. Epstein E, Ramirez A, Skoog L, Valentin L. Transvaginal sonography, saline contrast sonohysterography and hysteroscopy for the investigation of women with postmenopausal bleeding and endometrium > 5 mm. *Ultrasound Obstet Gynecol.* 2001;18(2):157-62.
21. Goldstein SR, Zeltser I, Horan CK, Snyder JR, Schwartz LB. Ultrasonography-based triage for perimenopausal patients with abnormal uterine bleeding. *Am J Obstet Gynecol.* 1997;177(1):102-8.
22. Farquhar C, Ekeroma A, Furness S, Arroll B. A systematic review of transvaginal ultrasonography, sonohysterography and hysteroscopy for the investigation of abnormal uterine bleeding in premenopausal women. *Acta Obstetrica et Gynecologica Scandinavica.* 2003;82(6):493-504.
23. Verma SK, Lev-Toaff AS, Baltarowich OH, Bergin D, Verma M, Mitchell DG. Adenomyosis: sonohysterography with MRI correlation. *Am J Roentgenol.* 2009;192(4):1112-6.
24. Soares SR, Barbosa dos Reis MM, Camargos AF. Diagnostic accuracy of sonohysterography, transvaginal sonography, and hysterosalpingography in patients with uterine cavity diseases. *Fertil Steril.* 2000;73(2):406-11.
25. Dueholm M, Forman A, Jensen ML, Laursen H, Kracht P. Transvaginal sonography combined with saline contrast sonohysterography in evaluating the uterine cavity in premenopausal patients with abnormal uterine bleeding. *Ultrasound Obstet Gynecol.* 2001;18(1):54-61.
26. Cicinelli E, Romano F, Anastasio PS, Blasi N, Parisi C. Sonohysterography versus hysteroscopy in the diagnosis of endouterine polyps. *Gynecol Obstet Invest.* 1994;38(4):266-71.
27. Dueholm M, Lunderdorf E, Olesen F. Imaging techniques for evaluation of the uterine cavity and endometrium in premenopausal patients before minimally invasive surgery. *Obstet Gynecol Surv.* 2002;57(6):388-403.
28. Smith-Bindman R, Kerlikowske K, Feldstein VA, Subak L, Scheidler J, Segal M, et al. Endovaginal ultrasound to exclude endometrial cancer and other endometrial abnormalities. *JAMA.* 1998;280(17):1510-7.
29. Bonnamy L, Marret H, Perrotin F, Body G, Berger C, Lansac J. Sonohysterography: a prospective survey of results and complications in 81 patients. *Europ J Obstet Gynecol Reprod Biol.* 2002;102:42-7.

**Cite this article as:** Pati B, Vani RK, Gowri AL, Tripathy DK. Comparison of saline instillation sonography with trans vaginal sonography in abnormal uterine bleeding: a prospective study. *Int J Reprod Contracept Obstet Gynecol* 2018;7:4819-26.