

DOI: <http://dx.doi.org/10.18203/2320-1770.ijrcog20190263>

## Original Research Article

# Prevalence of various dermatoses in pregnancy at a tertiary care centre in Moradabad, Uttar Pradesh, India: an observational study

Shruti Uniyal<sup>1</sup>, Ritika Agarwal<sup>1\*</sup>, Nupur Nandi<sup>1</sup>, Pulkit Jain<sup>2</sup>

<sup>1</sup>Department of Obstetrics and Gynecology, <sup>2</sup>Department of Orthopedics, Teerthankar Mahaveer Medical College and Research Center, Moradabad, Uttar Pradesh, India

**Received:** 14 November 2018

**Accepted:** 29 December 2018

### \*Correspondence:

Dr. Ritika Agarwal,

E-mail: [driritika2@yahoo.com](mailto:driritika2@yahoo.com)

**Copyright:** © the author(s), publisher and licensee Medip Academy. This is an open-access article distributed under the terms of the Creative Commons Attribution Non-Commercial License, which permits unrestricted non-commercial use, distribution, and reproduction in any medium, provided the original work is properly cited.

### ABSTRACT

**Background:** This was a prospective study which was done to observe various skin lesions in pregnancy and to determine the most likely causes and their incidence in antenatal patients, it was noticed that many women in our institute were having pregnancy related cutaneous complaints thus this observational study was carried out so that better preventive measures and treatment options could be provided to these patients.

**Methods:** Study was conducted in out-patient department of Obstetrics and Gynaecology, TMU, Moradabad. All ANC cases between October 2017 to September 2018 having any type of dermatoses were included in the study irrespective of gestational age. 6348 patients appeared in OPD in the given time period out of which 1256 were included. In case of pruritus, liver function tests were done with USG whole abdomen and patients were reviewed by physician if required. Screening with VDRL, HCV, HbSAg and ELISA for HIV was done in all. Results were tabulated and analyzed.

**Results:** 50.8% primi gravidas, 49.2% multi gravidas. age range 18-38 years. 29.3% presented in third trimester, 25.6% presented in second trimester. Physiological changes seen in all cases, 8.68% specific dermatoses of pregnancy. 40.4% no complaints, 5.65% melasma, 90.8% hyperpigmentation, 94.6% linea nigra. Secondary areola 89.3%, striae 80.3% out of which 38.9% - primi gravidas and 41.40% - multi gravidas. 92.9% no change in hair density. Montgomery's tubercles 30-50% of cases. spiders nevi 67%. No cases of palmar erythema. Pruritus gravidarum 38.53%. PUPPP 28.4%. Pemphigoid Gestationis 9.17%. Prurigo of pregnancy 18.34%. Pruritic folliculitis 1.8%. Eczema in pregnancy: pre-existing in 3.7%, out of which exacerbation 1, 3 unaffected. 3 chicken pox. 1 filariasis. 24 herpetic lesions (herpes simplex). 1 scleroderma. 17.27% pre-existing taenia infection. Scabies 20.46%. 11 0.87% dual infection (scabies-taenia).

**Conclusions:** This study highlights high prevalence of community acquired infections in our region like taenia, scabies giving rise to skin lesions in Antenatal women. Moreover, it highlights a probable association between the prevalence of skin lesions with factors like poor personal hygiene, overcrowding, low socioeconomic status, anaemia and poor nutritional status.

**Keywords:** Eczema, EP, Herpes, PF, PP, Pregnancy skin lesions, Prurigo, Pruritic, PUPPP

### INTRODUCTION

Benign skin changes occur as a result of physiological hormonal changes during pregnancy include striae gravidarum; hyperpigmentation; and hair, nail, and

vascular changes. Hyperpigmentation during pregnancy is present in majority of women up to some level. Face, areola, axillae, and genitalia are most commonly affected. Linea nigra is present in almost 90% of women melasma (chloasma or mask of pregnancy) being the second most

common. Striae gravidarum (stretch marks) occur in majority of women in the third trimester. Appear as pink-purple, atrophic bands mostly over the abdomen but buttocks, breasts, thighs, or arms may also be affected. Most shrink in the postpartum period; however, they do not disappear completely. Stretching of the skin occurs due to hormonal factors like adrenocortical steroids, estrogen, and relaxin on the skin's elastic fibres. Mostly seen in overweight or obese women or in women with larger babies. Vascular changes occurring during pregnancy are a result of increased estrogen production. Changes such as spider telangiectasias (spider nevi or spider angiomas) occur in about two thirds of women mostly in the first and second trimester.<sup>1-3</sup> Other changes such as palmar erythema, saphenous, vulvar, or haemorrhoidal varicosities may also be seen in second and third trimester. Hirsutism on the face, limbs, and back occur as a result of physiological endocrinal changes, these generally resolve postpartum, as a result of prolonged active (anagen) phase of hair growth in pregnancy mild thickening of scalp hair is present in the postpartum phase, scalp hair enters a prolonged resting (telogen) stage of hair growth, which causes increased shedding of hair postpartum lasting for several months.

#### **Pre-existing skin conditions**

There may be exacerbation of pre-existing skin conditions like dermatitis, psoriasis, any candidal or fungal infections in pregnancy. There are some pregnancy specific inflammatory skin dermatoses present, most of them are benign and get resolved in the postpartum period.

Classifications for pregnancy specific dermatoses the first ever classification was given in 1983 by Holmes and Black which comprised the skin lesions into four<sup>1</sup>:

- Pemphigoid gestationis (Herpes gestationis)
- Polymorphic eruption of pregnancy (PUPPP)
- Prurigo of pregnancy (PP) and
- Pruritic folliculitis of pregnancy (PF).

Another classification given in 1998 by Shornick, included PG, PEP and PP with intrahepatic cholestasis of pregnancy (ICP) in addition. The most recent classification was given in 2006 by Ambros-Rudolph et al, they added "atopic eruption of pregnancy (AEP)" in the pre-existing classification.<sup>3,4</sup> They subdivided AEP into eczema in pregnancy (ep), prurigo of pregnancy and pruritic folliculitis of pregnancy.

So as per the new classification four main skin conditions present in pregnancy are:

- Atopic Eruption of Pregnancy
  - Eczema in pregnancy (EP)
  - Prurigo of pregnancy
  - Pruritic folliculitis of pregnancy
- Polymorphic eruption of pregnancy

- Pemphigoid gestationis
- Intrahepatic cholestasis of pregnancy under dermatoses of pregnancy.

The aim of the present study was to observe the incidence of various skin lesions in all pregnant cases attending the outpatient department of Obstetrics and Gynecology in Teerthanker Mahaveer Medical College on Mondays and Thursdays from October 2017 to June 2018 and on Wednesdays and Saturdays from July 2018 to September 2018.

The objectives of the present study were to observe the various skin lesions in all antenatal women, to determine the most likely causes and their incidence in antenatal patients.

#### **METHODS**

An observational prospective study that was conducted in the out-patient department of Obstetrics and Gynaecology, TMU, Moradabad. All ANC cases seen between October 2017 to September 2018 having any type of dermatoses were included in the study irrespective of period of gestation. Informed consent was obtained before the interview and clinical examination. A total of 6348 patients appeared in the OPD in the given time period out of which 1256 patients were included. A detailed history was taken in a pre-designed proforma including demographic data, socioeconomic status, overcrowding, history of patient's hygiene, chief complaints related to skin, presence of itching, pre-existing skin lesions, their onset, history related to jaundice, fever, history of vaginal discharge, family history of similar lesions, exacerbating / relieving factors, associated medical or skin disorders etc. Complete cutaneous examination was carried out in all cases. In case of any specific dermatoses, patient was reviewed in the outpatient clinic in the department of dermatology. For pre-existing skin conditions any evidence of exacerbation or remission was recorded. Investigations were done as advised by dermatologist to confirm diagnosis if required. To confirm diagnosis skin biopsies were done in a few cases. In all cases with history of pruritus liver function tests were done with USG whole abdomen and patients were reviewed by physician if required. Screening with VDRL, HCV, HbSAg and ELISA for HIV was done in all the cases. Results were tabulated and analyzed.

#### **RESULTS**

1256 pregnant women were taken in the study. Of these, 638(50.8%) were primi gravidas and 618 (49.2%) were multi gravidas. Their age range was between 18 to 38 years. Most of them presented in the third trimester i.e. (368 of total cases, 29.3%) or second trimester i.e. (321 of all cases, 25.6%). Pregnancy dermatoses were divided into three categories: Physiological changes, Pregnancy Specific dermatoses and Skin diseases exacerbated by

pregnancy. Physiological changes were seen in all 1256 cases, 109 (8.68%) cases of specific dermatoses of pregnancy were seen. Majority of the patients 507 (40.4 %) had no complaints. those who had, the primary complaint was itching (282, 22.45%) followed by

complaints of presence of skin lesions (203, 16.16%), vaginal discharge (84, 6.69%), melasma (71, 5.65%), Past history of striae and pigmentary changes was observed in 612 multi gravidas and obese patients.

**Table 1: Clinical characteristics of different pregnancy dermatoses.**

	ICP	PP	PUPPP	HG
Number (%)	42 (38.53%)	20 (18.34%)	31(28.4%)	10 (9.17%)
Primigravida	16 (1.27%)	6 (0.47%)	8 (0.63%)	2 (0.16%)
Multigravida	26 (2.07%)	14 (1.14%)	23 (1.83%)	8 (0.64%)
Similar complaints in previous pregnancy	18 (1.43%)	3 (0.56%)	9 (.72%)	0
<b>Gestation at the time of examination</b>				
1st trimester	0	0	0	0
2nd trimester	29 (2.31%)	2 (0.16%)	7 (0.56%)	4 (0.31%)
3rd trimester	13(1.04%)	18 (1.43%)	24 (1.9%)	6 (0.48%)

**Table 2: Clinical characteristics of skin lesions not specific to pregnancy.**

	Taenia	Scabies	Dual infection of Taenia with scabies	Scleroderma	Eczema	Filariasis	Chicken pox	Herpes simplex
Number (%)	217	257	11	1	4	1	3	24
Primigravida	88	108	4		3		2	13
Multigravida	129	149	7	1	1	1	1	11
Similar complaints in previous pregnancy/pre-existing skin condition	112	183	8	1	4 (pre-existing)	1	-	16 (pre-existing) 3 (previous pregnancy)
Starting of the condition								
1 <sup>st</sup> trimester	29	52	3	1	4	-	-	6
2 <sup>nd</sup> trimester	70	107	3	-	-	-	-	11
3 <sup>rd</sup> trimester	118	98	5	-	-	1	3	7
Exacerbation	153	63	3	1	1	-	-	9
Overcrowding	182	176	7	-	-	1	1	13
Poor personal hygiene	147	203	9	1	2	1	3	19
Anaemia	139	174	6	1	2	1	2	18
Low socioeconomic status	152	198	8	1	2	1	2	17
Pruritis	183	254	7	-	4	-	3	7
Vaginal discharge	18	21	4	-	-	-	-	3
Fever	12	8	3	-	-	1	2	3
Jaundice	17	12	2	-	-	-	-	2
Diabetes	13	22	4	-	-	-	-	3

The commonly observed physiological changes were striae gravidarum, linea nigra, melasma and generalized hyperpigmentation. Vascular changes resulted in palmar erythema, spider nevi and varicosities. Some women had

hair changes as well. In present study, 90.8% of cases had hyperpigmentation; linea nigra was seen in 94.6% cases. Secondary areola developed in 89.3% cases. Common Sites of hyperpigmentation were abdomen,

face, buttocks, and breasts. Melasma was seen in 71/1256 (5.65%) of our cases. Its onset was mostly seen in the first trimester. It persisted in 30 % of cases. In present study, striae were seen in 1009 (80.3%) cases of which 489 (38.9%) were primi gravidas and 520 (41.40%) were multi gravidas. Onset was most commonly seen during the second trimester. In primigravidas pink shiny striae were seen in lower abdomen while in Multi gravidas striae appeared to be white and atrophic.

Of the 1256 women, 89 gave a history of increased hair loss whereas 1167 (92.9%) had history of no change in hair density.

Montgomery's tubercles were seen in 30-50% of cases. In Vascular changes spiders nevi appeared in 67% of women in the second trimester.

No cases of palmar erythema were observed in present study this may be due to less visibility in darker skin. Specific dermatoses of pregnancy were mostly associated with pruritus.

In present study of 1256 cases, 109 (8.67%) had specific dermatoses of pregnancy. Most common finding was Pruritus gravidarum (intrahepatic cholestasis of pregnancy) (ICP) was seen in 42 (38.53%) of total cases.

PUPPP was seen in 31 (28.4%). Pemphigoid Gestationis was seen in 10 (9.17%) cases. Prurigo of pregnancy was seen in 20 cases (18.34%) Pruritic folliculitis was seen in 2 (1.8%) cases.

Eczema in pregnancy was pre-existing in 4 (3.7%) cases, out of which exacerbation was seen in 1 case, 3 remain unaffected. 3 patients were admitted from the OPD with chicken pox. 1 patient was admitted in ICU had filariasis. 24 patients had herpetic lesions (herpes simplex).

1 patient of scleroderma was seen. 217 out of 1256 cases i.e. (17.27%) had pre-existing taenia infection that got exaggerated in the late second trimester.

257 out of total cases had scabies, i.e. around (20.46%), and 11 (0.87%) had a dual infection of both scabies as well as taenia (Table 1) (Table 2).

## DISCUSSION

In skin the changes are striae gravidarum, melasma and some hair, nail and vascular changes. Common skin lesions that occur during pregnancy can be divided into three categories: hormone-related, pre-existing, and pregnancy-specific.

Pregnancy specific dermatosis include:

- Atopic eruption of pregnancy
- AEP starts earlier in pregnancy as compared to PEP, PG, and ICP which appear late.

## Eczema in pregnancy

Occur mostly in the first and second trimester, including all parts of the body. In Pregnancy there is suppression of maternal cell-mediated immunity and increased humoral immune response to prevent fetal rejection.<sup>5</sup> This leads to the exacerbation of atopic dermatitis. The patients have high serum IgE levels. Eruptions are seen more commonly in primigravida with single foetus.

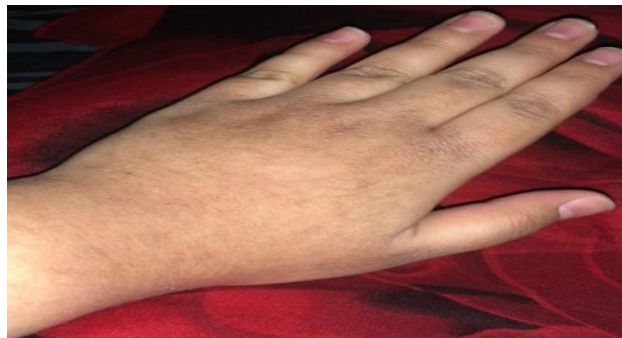

Figure 1: Eczema exacerbated in pregnancy.

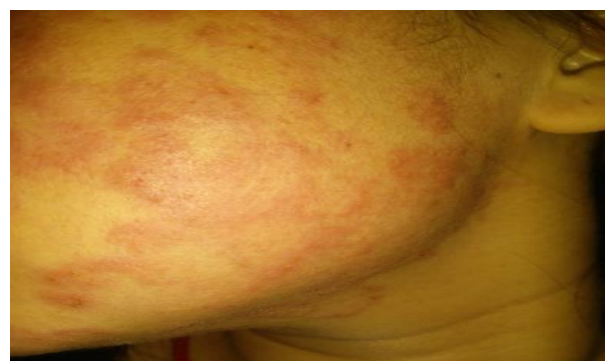

Figure 2: Another instance of eczema exacerbated in pregnancy.

## Prurigo of pregnancy

Prurigo is characterized by pruritis with excoriated papules and nodules mostly on legs and upper arms, abdomen. It may occur in all trimesters. The cause is unknown.<sup>4</sup> It has no adverse effect on the mother or the fetus.

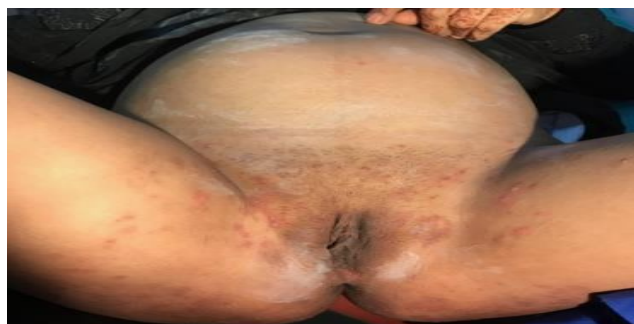

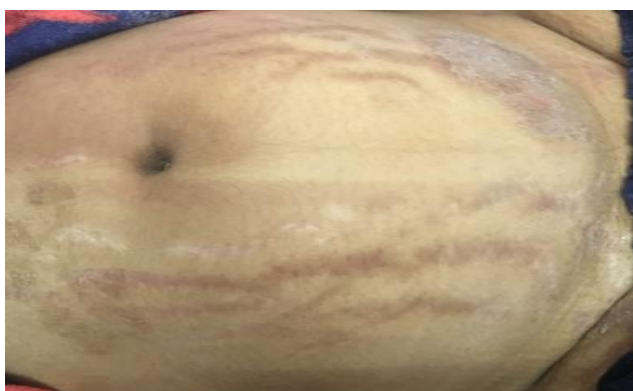
Figure 3: Prurigo of pregnancy.

### **Pruritic folliculitis**

It is a rare condition. It may be mistaken for acne or microbial folliculitis. Pruritic lesions measure about 2- to 4-mm. Diagnosis is made clinically when all other conditions causing skin rashes are excluded. The lesions get resolved in the postpartum period. Histopathological finding shows, acute sterile folliculitis. There is no associated perinatal morbidity.<sup>6-12</sup>

### **Polymorphic eruption of pregnancy**

Polymorphic eruption of pregnancy also called pruritic urticarial papules and plaques of pregnancy (PUPPP), occurs as a result of stretching of the skin leading to damage of connective tissue and conversion of non-antigenic molecules to antigenic ones, leading to skin eruptions.<sup>13,14</sup> Abdomen is the most commonly affected area while breasts, upper thighs, and arms may also get affected. Often seen with multifetal pregnancies in the third trimester. The cause is unknown. There is marked pruritis and the onset of pruritis is associated with skin lesions that are polymorphous, erythematous, non-follicular papules, plaques, and sometimes vesicles. The histopathological findings are nonspecific. The lesions get spontaneously resolved in the early postpartum period. The maternal and fetal prognosis remains unaffected.<sup>14,15</sup>



**Figure 4: Pruritic urticarial papules and plaques of pregnancy (PUPPP).**

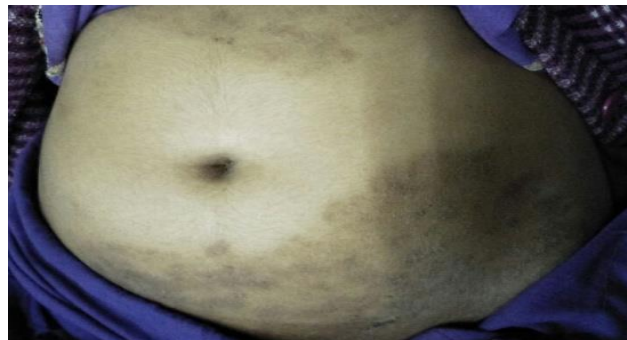### **Pemphigoid gestationis (herpes gestationis)**

It is a rare autoimmune disorder that begins in the second or third trimester. It is associated with HLA-DR3 and HLA-DR4 and with molar pregnancies and choriocarcinoma.<sup>16,17</sup>

It could be triggered by a placental antigen which leads to a cross-reaction with skin antibodies. The skin lesions are pruritic, urticarial and vesiculobullous.

Histological findings include subepidermal vesicle formation. Around 5 to 10 percent of new-borns have risk of developing these lesions.<sup>18</sup> It may also lead to mild

placental failure that may cause premature deliveries and small for gestational age babies. Antenatal surveillance is recommended.



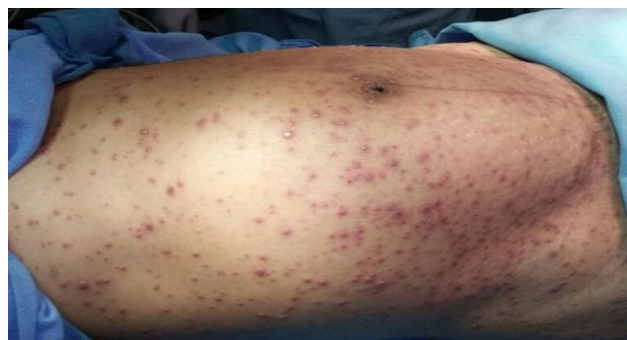**Figure 5: Pemphigoid gestationis.**

### **Pruritus gravidarum (intrahepatic cholestasis of pregnancy) (ICP)**

Pruritus gravidarum is classically associated with itching, without any skin lesions and occurs in the third trimester, jaundice maybe present, there are increased bile acids (4.08 mcg per ml [10 μmol per L] or more) and bile salts with deranged liver function test.<sup>19</sup> Excoriated papules are seen that occur as a result of scratching mostly on limbs, abdomen and back. The severity of skin lesions depends on the duration of pruritus.<sup>3</sup> As per aetiology, a positive family history of cholelithiasis may be present, with association of (HLA-A31) and HLA-B8. It may recur in subsequent pregnancies.<sup>7,19</sup> There are higher chances of premature delivery and IUD due to hypoxia caused by decreased excretion of bile acids vitamin K deficiency and Coagulopathy may also occur with prolonged cholestasis. Close obstetric surveillance is mandatory.<sup>19-22</sup>

### **Impetigo herpetiformis**

Impetigo herpetiformis is a form of pustular psoriasis; it is a rare skin disorder occurring in the second half of pregnancy.

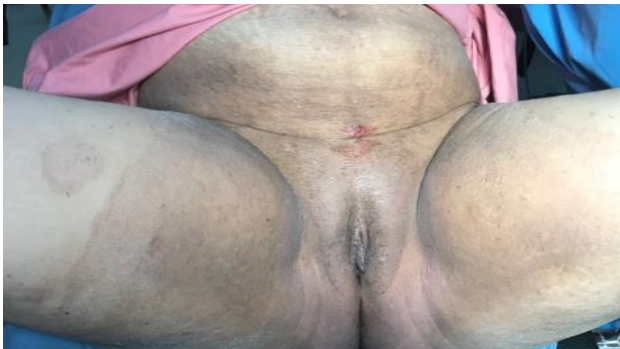

**Figure 6: Impetigo herpetiformis**

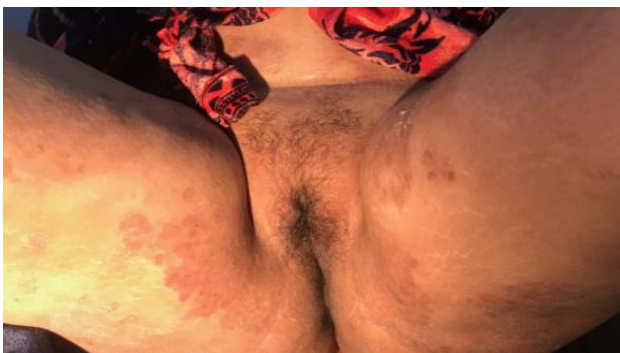Symptoms include nausea, vomiting, diarrhoea, fever with chills, and lymphadenopathy. It is associated with an

increased risk of fetal morbidity so antenatal surveillance is required.<sup>22</sup>

Physiological changes were striae gravidarum, linea nigra, melasma and generalized hyperpigmentation. Vascular changes were palmar erythema, spider nevi and varicosities. Some women had hair and nail changes as well. In this study, 90.8% of cases had hyperpigmentation; linea nigra was seen in 94.6% cases. Secondary areola developed in 89.3% cases. These findings are comparable to other studies.<sup>4,6,7</sup> Melasma was seen in 71/1256 (5.65%) of our cases. Its onset was mostly seen in the first trimester. It persisted in 30 % of cases.



**Figure 7: Occurrence of Taenia.**

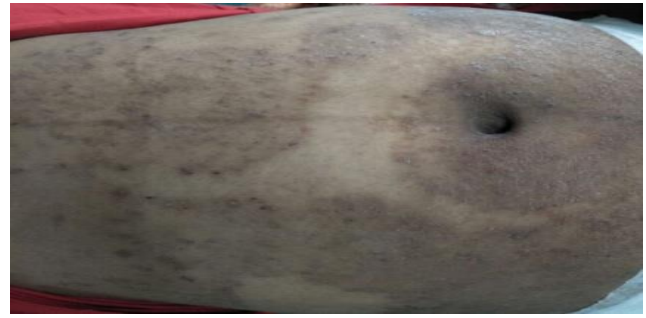

**Figure 8: Another occurrence of Taenia.**

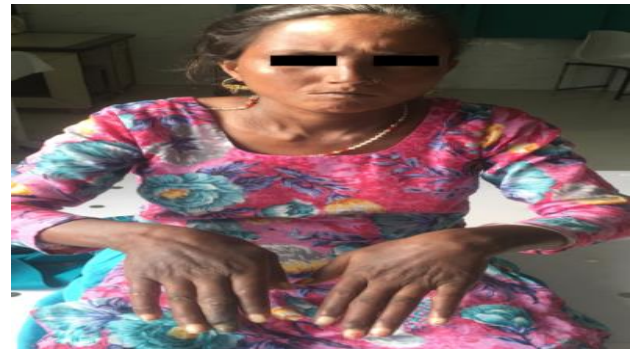In present study, striae were seen in 1009 (80.3%) cases of which 489 (38.9%) were primi gravidas and 520 (41.40%) were multi gravidas. Of the 1256 women, 89 gave a history of increased hair loss whereas 1167(92.9%) had history of no change in hair density. Montgomery's tubercles were seen in 30-50% of cases. These findings were found to be consistent with other studies.<sup>14</sup>

In Vascular changes spiders' nevi appeared in 67% of women in the second trimester. No cases of palmar erythema were observed in present study this may be due to less visibility in darker skin. These were found to be consistent with other studies.<sup>15</sup> Specific dermatoses of pregnancy were mostly associated with pruritus. In

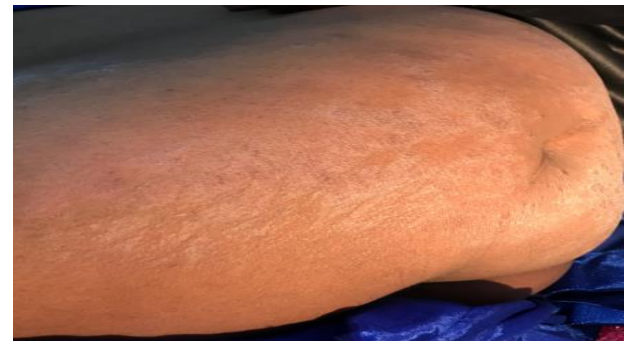
present study of 1256 cases, 109 (8.67%) had specific dermatoses of pregnancy.



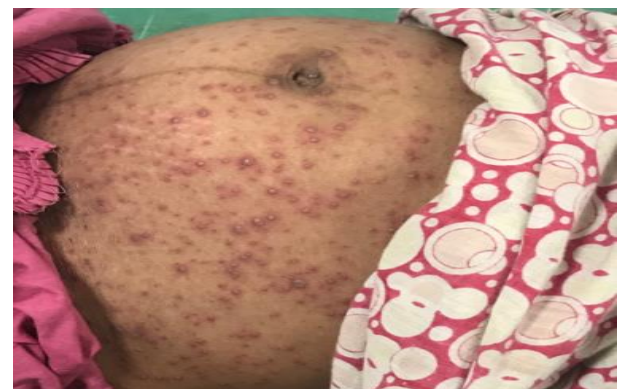**Figure 9: Taenia and scabies dual infection.**



**Figure 10: scleroderma seen on right middle finger.**



**Figure 11: Scabies seen on right thigh.**



**Figure 12: Chicken pox in pregnancy**

Of these the most common was Pruritus gravidarum (intrahepatic cholestasis of pregnancy) (ICP) was seen in 42 (38.53%) of total cases. PUPPP was seen in total 31(28.4%) cases. Pemphigoid Gestationis was seen in 10 (9.17%) cases. Prurigo of pregnancy was seen in 20 of total 1256 cases (18.34%) Pruritic folliculitis was seen in 2 (1.8%) cases. These findings were found to be consistent with other studies.<sup>12,13</sup> Eczema in pregnancy was pre-existing in 4 (3.7%) cases, out of which exacerbation was seen in 1 case, 3 remain unaffected. 3 patients were admitted from the OPD with chicken pox. 1 patient was admitted in ICU had filariasis. 24 patients had herpetic lesions (herpes simplex). 1 patient of scleroderma was seen. 217 out of 1256 cases i.e. (17.27%) had pre-existing taenia infection that got exaggerated in the late second trimester. 257 out of total cases had scabies, i.e. around (20.46%). And 11(0.87%) had a dual infection of both scabies as well as taenia.

There were many limitations in present study, many patients were lost to follow up, a few of them did not visit the outpatient department of dermatology as advised, there was non-compliance seen in a few. Some out of the total (6384) no of ANC patients refused to participate in the study, while some gave a negative consent for cutaneous examination. Many patients came to the OPD for the first time in the third trimester, so the start of occurrence of infection could not be made.

## CONCLUSION

Pregnancy is a physiological state which occurs as a direct result of hormonal, vascular, metabolic and immunological changes. Pregnancy being an immunocompromised state, there are increased chances of acquiring skin infections or exacerbation of the pre-existing ones during pregnancy. There are some climate and seasonal specific dermatoses also present. The skin lesion may also be present as a result of some underlying cause such as diabetes, chickenpox, measles, cholestasis of pregnancy, scleroderma. It may also occur as a result of poor personal hygiene and factors like overcrowding, low socioeconomic status, anaemia. This study highlights high prevalence of community acquired infections in our region like taenia, scabies giving rise to skin lesions in Antenatal women. Moreover, it highlights a probable association between the prevalence of skin lesions with factors like poor personal hygiene, overcrowding, low socioeconomic status, anaemia and poor nutritional status.

*Funding: No funding sources*

*Conflict of interest: None declared*

*Ethical approval: The study was approved by the Institutional Ethics Committee*

## REFERENCES

1. Holmes RC, Black MM. The specific dermatoses of pregnancy. *J Am Acad Dermatol.* 1983;8(3):405-12.

2. Shornick JK. Dermatoses of pregnancy. *Semin Cutan Med Surg.* 1998;17(3):172-81.
3. Ambros-Rudolph CM, Mullegger RR, Vaughan-Jones SA, Kerl H, Black MM. The specific dermatoses of pregnancy revisited and reclassified: Results of a retrospective two-center study on 505 pregnant patients. *Am Acad Dermatol.* 2006;54(3):395-404.
4. Thomas RG, Liston WA. Clinical associations of striae gravidarum. *J Obstet Gynaecol.* 2004;24(3):270-1.
5. Chang AL, Agredano YZ, Kimball AB. Risk factors associated with striae gravidarum. *J Am Acad Dermatol.* 2004;51(6):881.
6. Torok HM, Jones T, Rich P, Smith S, Tschen E. Hydroquinone 4%, tretinoin 0.05%, fluocinonide acetone 0.01%: a safe and efficacious 12-month treatment for melasma. *Cutis.* 2005;75(1):57-62.
7. Tunzi M, Gray GR. Common skin conditions during pregnancy. *Am Fam Physician* 2007;75(2):2118.
8. Daneshpazhooh M, Chams-Davatchi C, Valikhani M, Aghabagheri A, Mortazavizadeh SM, Barzegari M, et al. Pemphigus and pregnancy: A 23-year experience. *Indian J Dermatol Venereol Leprol* 2011;77(4):534.
9. Sachdeva S. The dermatoses of pregnancy. *Indian J Dermatol* 2008;53(3):103-5.
10. Cobo MF, Santi CG, Maruta CW, Aoki V. Pemphigoid gestationis: Clinical and laboratory evaluation. *Clinics (Sao Paulo)* 2009;64(11):1043-7.
11. Ruiz-Villaverde R, Blasco Melguizo J, Naranjo-Sintes R. Pigmentary demarcation lines in a pregnant Caucasian woman. *Int J Dermatol* 2004;43(12):911-2.
12. Kroumpouzou G, Cohen LM. Dermatoses of pregnancy. *J Am Acad Dermatol* 2001;45(1):1-19.
13. Roth MM: Pregnancy dermatoses: diagnosis, management, and controversies. *Am J Clin Dermatol.* 2011;12(1):25-41
14. Sceppa JA, Smith BL, Marghoob AA, Gottlieb GJ. Melanosis of the areola and nipple. *J Am Acad Dermatol.* 2008;59(1):S33-4.
15. Muallem MM, Rubeiz NG: Physiological and biological changes in pregnancy. *Clin Dermatol* 2006;24(2):80-4.
16. Oumeish OY, Al-Fouzan AS: Miscellaneous diseases affected by pregnancy. *Clin Dermatol.* 2006;24(2):113-7.
17. Vaughan Jones SA, Black MM: Pregnancy-related conditions. In Parish LC, Brenner S, Ramos-e-Silva M. *Women's Dermatology: From infancy to maturity*, pp 397-413. New York, Parthenon Publishing, 2001.
18. Salter SA, Kimball AB: Striae gravidarum. *Clin Dermatol.* 2005;24(2):97-100.
19. Higgins CA, Westgate GE, Jahoda CA. From telogen to exogen: mechanisms underlying formation and subsequent loss of the hair club fiber. *J Invest Dermatol.* 2009;129(9):2100-8.

20. Millikan L. Hirsutism postpartum telogen effluvium, and male pattern alopecia. *Cosmet Dermatol* 2006;5(1):81-6.
21. Matz H, Orion E, Wolf R: Pruritic urticarial papules and plaques of pregnancy: polymorphic eruption. *Clin Dermatol* 2005;24(2):105-8.
22. Ghazeeri G, Kibbi AG, Abbas O. Pruritic urticarial papules and plaques of pregnancy: epidemiological,

clinical, and histopathological study of 18 cases from Lebanon. *Int Dermatol* 2012;51(9):1047-53.

**Cite this article as:** Uniyal S, Agarwal R, Nandi N, Jain P. Prevalence of various dermatoses in pregnancy at a tertiary care centre in Moradabad, Uttar Pradesh, India: an observational study. *Int J Reprod Contracept Obstet Gynecol* 2019;8:425-32.