

DOI: <http://dx.doi.org/10.18203/2320-1770.ijrcog20190909>

Case Report

Successful management of a patient with severe brady-arrhythmia in peripartum period

Aditi Tandon*, Meena Satia, Vijaya Badhwar

Department of Obstetrics and Gynecology, DY Patil Hospital, Mumbai, Maharashtra, India

Received: 12 January 2019

Accepted: 06 February 2019

***Correspondence:**

Dr. Aditi Tandon,

E-mail: aditi.tandon28@gmail.com

Copyright: © the author(s), publisher and licensee Medip Academy. This is an open-access article distributed under the terms of the Creative Commons Attribution Non-Commercial License, which permits unrestricted non-commercial use, distribution, and reproduction in any medium, provided the original work is properly cited.

ABSTRACT

Pregnancy is a normal physiological state with hyperdynamic circulation that is characterised by important physiological changes, many of which take place in the cardiovascular system. Few patients with physiological bradycardia may, in the second trimester, feel symptomatic as their blood pressure drops due to a reduction in systemic vascular resistance however, treatment is rarely required. Pathological bradycardia in pregnant women is rare and usually secondary to either Congenital heart block, Myocarditis, or Severe Hypocalcaemia with an incidence as low as 1:20 000 women. Authors present a rare case of severe bradycardia during peripartum period who required LSCS in view of IUGR with Anhydroamnios. On admission her general condition was good her pulse was 42 beats per mins and BP was 170/100 mm of Hg with 1+ proteinuria. A clinical impression of preeclampsia was made. ECG showed sinus bradycardia with no irregularity. 2 DEcho showed no structural lesion in the heart and normal functional capacity so dilated peripartum cardiomyopathy was ruled out. Her serum electrolytes were normal and serum calcium and magnesium was markedly reduced which was corrected. Post operatively on day 4 pulse was more than 60 and she was transferred out of ICU. The ECG performed on day 6 was normal.

Keywords: Arrhythmia, Bradycardia, Hypotensive syndrome, Myocarditis

INTRODUCTION

In pregnancy, Heart rate (HR) increases by 25%; thus, sinus tachycardia, particularly in the third trimester, is expected hence severe bradycardia during the last trimester of pregnancy should be taken seriously and thoroughly evaluated. Symptomatic bradycardia has been sometimes attributed to supine hypotensive syndrome of pregnancy, which responds to maternal changing of position.¹ Bradycardia usually begins in the sinus node. Bradycardia might occur because the sinus node discharges electrical impulses that are slower than normal or stops or does not discharge an impulse at a regular rate. In some patients the sinus nodal problems cause an alternating slow and fast heart rates called bradycardia - tachycardia syndrome. Among the multiple causes of bradycardia like the damage to the heart tissues due to

aging, congenital heart defect, infection of heart tissue like myocarditis, hypothyroidism and electrolyte imbalance in the blood, along with hypokalemia or hypocalcemia which should be ruled out. Various degrees of heart block could be due to electrical impulses not passing from atria to the ventricles which could cause bradycardia. Cardiac arrhythmias are known to be more common during pregnancy and labour. Management of these women is clinically challenging. It is mandatory to evaluate any lesion in the heart for making a decision with regards to the mode and timing of delivery. Authors report a case which illustrates these complexities.

CASE REPORT

A 26-year-old primigravida with 39 weeks gestation was referred to our tertiary care centre at D Y Patil Hospital

for Elective LSCS in view of severe IUGR and anhydroamnios and bradycardia which may require intensive Cardiac Care facility. She gave history of fever with cough for 4-5 days one week ago which responded to the antibiotics and antipyretics given by her general practitioner. Following this episode, she developed persistent bradycardia and hence was referred to our tertiary care centre. Her pulse throughout pregnancy was reported normal from her previous visits. The present medications she was taking were iron and calcium. The patient had no significant past medical history, and there was no known family history of cardiac disease or genetic syndromes. She had no symptoms of bradycardia.

On admission her general condition was good her pulse was 42 beats per mins and BP was 170/100 mm of Hg with 1+ proteinuria. Her chest auscultation was normal. On auscultation of heart bradycardia was noted. Heart sounds were normal. On per abdominal examination she was 34 weeks of pregnancy and uterus did not show any uterine activity. She was given 10 mg oral nifedipine after which the BP was normal. A clinical impression of preeclampsia was made. Routine laboratory tests were normal. Preeclampsia work-up was negative. Doppler studies were normal and biophysical profile was 8/10. Non-stress test was reactive. In view of bradycardia an ECG was done, and cardiology opinion was taken. ECG showed sinus bradycardia with no irregularity (Figure 1 and Figure 2).

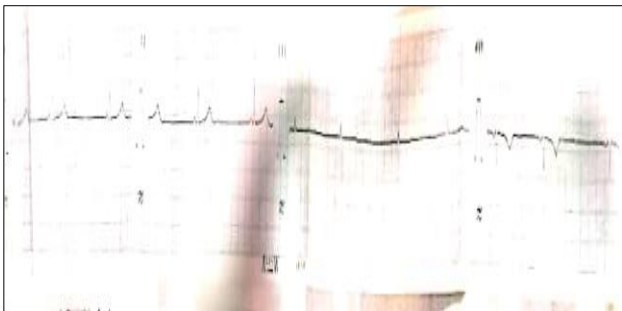


Figure 1: ECG representing bradycardia at the initial stage.

2 DEcho was advised which showed no structural lesion in the heart and normal functional capacity so dilated peripartum cardiomyopathy was ruled out. Her serum electrolytes were normal and serum calcium and magnesium was markedly reduced which was corrected by giving 10 ml of 10 % Calcium gluconate IV slowly and 1gm Magnesium sulphate IV after 48 hours.

After ruling out arrhythmia she was given 0.5 mg intravenous atropine as her pulse had fallen below 40 bpm. She responded to atropine with her pulse reaching 120 bpm and complained of severe headache and photophobia. Cardiologist was of the opinion that intra-operatively the need of pacemaker may arise and hence the high-risk consent was taken and pacemaker kept ready. Elective LSCS under GA was done with

cardiologist as a standby along with a senior anaesthesiologist. In the OT before induction of anaesthesia due to the glycopyrolate her pulse went to 100/min and she again complained of severe headache along with photophobia with OT lights.

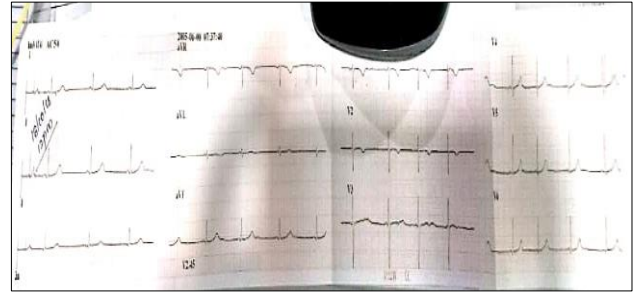


Figure 2: ECG showing bradycardia with no irregularities.

With the fear of impending eclampsia and anhydroamnios LSCS was performed which was uneventful. The baby was delivered by vertex, cried immediately and handed over to the neonatologist. Post operatively her pulse was in the normal range.

She was given oral nifedipine to control her BP and prophylactic magnesium sulphate to prevent eclampsia and to control low serum magnesium. Post-operative day 2 and 3 the patient was absolutely fine with her pulse being 50 and 60 bpm. Post op day 4 pulse was more than 60 and she was transferred out of ICU. The ECG performed on day 6 was normal as shown in the Figure 3 and 4.

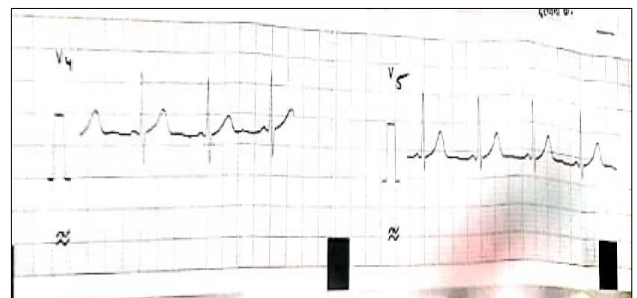


Figure 3: Normal ECG (Day 4, 5).

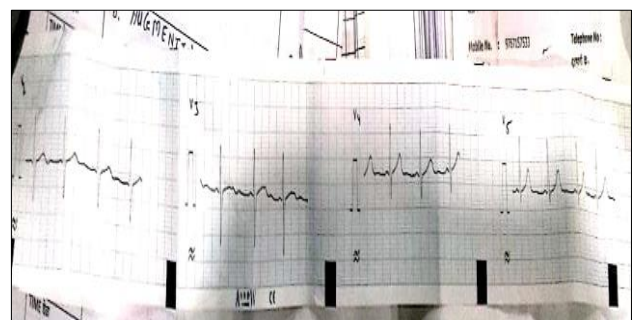


Figure 4: Normal ECG (Day 3, 4, 5).

Her hypocalcemia was corrected and by day 6 her serum calcium and magnesium levels were normal, and patient was discharged on day 6.

DISCUSSION

Pregnancy and labour are known to be associated with a higher incidence of maternal cardiac arrhythmias.^{2,3} In pregnancy, physiological changes to the cardiovascular system cause an increase in plasma volume and red cell mass by 45% and 30% respectively. Cardiac output increases by 40%. Peripheral vascular resistance is lowered by 20% and regional blood flow is altered.² There is evidence of an increase in the left ventricular diameter and myocardial hypertrophy.⁴ These altered anatomical and functional changes are believed to be the cause for an increased incidence of maternal cardiac arrhythmias. The sinus node has an intrinsic automaticity and always produces an impulse; however, the rate of impulse generation is controlled by other factors, particularly the autonomic nervous system. With increased parasympathetic stimulation or reduced sympathetic stimulation, the sinus rate slows, and the PR interval prolongs due to a vagally mediated slowing of conduction through the atrioventricular node.

Symptomatic bradycardia can cause complications like frequent fainting attacks, inability of the heart to pump enough blood or sudden cardiac arrest or death so all patients with severe bradycardia require intensive cardiac care unit at a tertiary care centre. A Congenital cause of heart block is rare and rarely poses a problem in pregnancy. There is conflicting evidence about whether to advise temporary pacing for delivery. There is concern that the Valsalva manoeuvre associated with delivery increases the chance of worsening bradycardia and syncope and pacing also allows for an adequate heart rate response for the increased cardiovascular stress.⁵ Spinal anaesthesia for caesarean section, however, can be associated with a higher incidence of all grades of bradycardia (up to 13%).⁶

Syncope may occur from marked bradycardia or atrioventricular dissociation or complete heart block. Bradycardia in pregnancy is rare but may occur in a patient that has a high vagal tone. The cause of conduction system disease in this population is usually congenital and may first come to medical attention during pregnancy.⁷ Acquired heart block may result from acute myocarditis, after cardiac surgery, hyperkalemia, drug toxicity, systemic illness, or spinal cord injury. The various medications which may affect the conduction system include digoxin, quinidine, phenothiazines, and tricyclic antidepressants. It may be seen with systemic lupus erythematosus, sarcoidosis or thyroid disease. Lyme disease or endocarditis may also cause heart block. Patients with symptomatic profound bradycardia and those with symptomatic or asymptomatic advanced conduction system disease require placement of a permanent pacemaker.⁸

This case remains unusual Firstly because the woman presented with a bradycardia. Other case series have established that arrhythmias most commonly seen in labour are atrial premature beats, ventricular premature beats, sinus and supraventricular tachycardias.⁹⁻¹¹ A parturient woman is at a high risk of emotional and physical strain and the predominance of tachycardia-related arrhythmias as a consequence of endogenous catecholamine release is understandable. Although bradycardias have been reported in the peripartum period, previous studies suggest that these tend to occur following delivery rather than during labour. Secondly, this presentation was unique in that the bradycardia presented only in the late third trimester and resolved after delivery.^{12,13} Other authors report that a more common pattern is transient arrhythmias which occur intermittently during labour.¹⁴ There is hardly any correlation between arrhythmias and symptoms in pregnant women. This lady had no presenting complaints. Dizziness as well as presyncope and even syncope, are not uncommon during pregnancy.¹² These could be attributed to the physiological changes that occur in pregnant women. Anaesthesia proved to be a clinical dilemma. There was concern that a regional anaesthetic could precipitate cardiac failure due to the hypotension it causes, in a woman who would not be able to compensate a physiological response in the form of tachycardia. Nevertheless, the absence of detectable cardiac disease and the fact that she remained haemodynamically stable supported the eventual decision to proceed with general anaesthesia. LSCS is known to carry a higher risk of postpartum haemorrhage and maternal mortality than vaginal delivery.¹⁵ These risks could be further compounded in the presence of a cardiac arrhythmia. However, this patient needed a caesarean for obstetric reasons.

CONCLUSION

Authors highlight this case to emphasise the fact that while cardiac arrhythmias are common in pregnancy, their nature and presentation can be quite varied. When faced with such a clinical situation, a thorough search for underlying cardiovascular disease is mandatory. In addition to this a multidisciplinary approach and team work with senior consultants is essential. In the absence of this and haemodynamic compromise, authors propose that watchful waiting should be the rule and vaginal delivery the goal unless indicated otherwise.

Funding: No funding sources

Conflict of interest: None declared

Ethical approval: Not required

REFERENCES

1. Dawn Adamson and Catherine Nelson-Piercy. (2007) Managing palpitations and arrhythmias during pregnancy. *Heart* 2007;93(12):1630-6.

2. Blackburn TS, Lee LD. Cardiovascular system. In: Eoyang T, ed. *Maternal, Fetal and Neonatal Physiology: a clinical Perspective*. Philadelphia: WB Saunders, 1992:201-12.
3. Leung CY, Brodsky MA. Cardiac arrhythmias and pregnancy: diagnosis and management of maternal and fetal disease. In: Elkayam U, Gleicher N, eds. *Cardiac Problems in Pregnancy*. 3rd ed. New York: Wiley-Liss, 1998:155-75.
4. Robson SC, Hunter S, Boys RJ, Dunlop W. Serial study of factors influencing changes in cardiac output during human pregnancy. *Am J Physiol.* 1989; 256(4):H1060-5.
5. Hidaka N, Chiba Y, Kurita T, Satoh S, Nakano H. Is intrapartum temporary pacing required for women with complete atrioventricular block? An analysis of seven cases. *BJOG.* 2006;113(5):605-7.
6. Shen CL, Ho YY, Hung YC, Chen PL. Arrhythmias during spinal anesthesia for Cesarean section. *Can J Anaesth.* 2000;47(5):393-7.
7. Dalvi BV, Chaudhuri A, Kulkarni HL: Therapeutic guidelines for congenital complete heart block presenting in pregnancy. *Obstet Gynecol.*1992;79(5 pt 2):802-4.
8. Jaffe R, Gruber A, Fejgin M. Pregnancy with an artificial pacemaker. *Obstet Gynecol.*1987 42(3):137-9.
9. Hair TE Jr, Eagan JT, Orgain ES. Paroxysmal ventricular tachycardia in the absence of demonstrable heart disease. *Am J Cardiol.* 1962; 9(2):209-14.
10. Hubbard WN, Jenkins BA, Ward DE. Persistent atrial tachycardia in pregnancy. *Br Med J (Clin Res Ed).* 1983;287(6388):327.
11. Brodsky M, Doria R, Allen B, Sato D, Thomas G, Sada M. New-onset ventricular tachycardia during pregnancy. *Am Heart J.* 1992;123(4):933-41.
12. Shotan A, Ostrzega E, Mehra A, Johnson JV, Elkayam U. Incidence of arrhythmias in normal pregnancy and relation to palpitations, dizziness, and syncope. *Am J Cardiol.* 1997;79(8):1061-4.
13. Romem A, Romem Y, Katz M, Battler A. Incidence and characteristics of maternal cardiac arrhythmias during labor. *Am J Cardiol* 2004; 93:931-3. Comment in: *Am J Cardiol.* 2005;95(7):435.
14. Upshaw CB Jr. A study of maternal electrocardiograms recorded during labor and delivery. *Am J Obstet Gynecol* 1970;107(1):17-27.
15. Hall MH. Mortality associated with elective caesarean section. *BMJ* 1994;308(6943):1572.

Cite this article as: Tandon A, Satia M, Badhwar V. Successful management of a patient with severe brady-arrhythmia in peripartum period. *Int J Reprod Contracept Obstet Gynecol* 2019;8:1211-4.