

DOI: <http://dx.doi.org/10.18203/2320-1770.ijrcog20191978>

Case Report

Chronic non-puerperal uterine inversion in the absence of risk factors: a rare case report

Rajesh Tile, Supriya Jamkhani*

Department of Obstetrics and Gynecology, ESIC Medical College, Gulbarga, Karnataka, India

Received: 17 January 2019

Revised: 30 January 2019

Accepted: 08 April 2019

***Correspondence:**

Dr. Supriya Jamkhani,

E-mail: sjsupriyajamkhani@gmail.com

Copyright: © the author(s), publisher and licensee Medip Academy. This is an open-access article distributed under the terms of the Creative Commons Attribution Non-Commercial License, which permits unrestricted non-commercial use, distribution, and reproduction in any medium, provided the original work is properly cited.

ABSTRACT

Non puerperal chronic uterine inversion is a rare entity; representing 1/6th of all uterine inversions. Usually precipitated by risk factors like fibroid uterus, endometrial polyp, endometrial malignancies. We present a case of 25 year old P2L2 with irregular vaginal bleeding and pain abdomen, with severe anemia. On per abdomen examination no abnormality detected, per speculum revealed a red friable mass 5*5cms protruding through vagina and per vaginal examination same findings confirmed. A diagnosis of fibroid polyp made initially and planned for polypectomy after correction of anemia. Under spinal anaesthesia diagnosis was changed to uterine inversion. Exploratory laparotomy done, which revealed characteristic flower pot appearance. Inversion was corrected by Haultens method, where in posteriorly incision was given to cut the tight cervical ring, and uterus was repositioned back to normal anatomic position. Bilateral tubal sterilization was done as per patients request. Post operative period was uneventful and she was discharged in stable condition. Thus chronic non puerperal uterine inversion can be difficult to diagnose in the absence of risk factors.

Keywords: Haultens method, Uterine inversion

INTRODUCTION

Uterine inversion refers to descent of the uterine fundus to or through the cervix, so that the uterus is turned inside out. It is a rare condition, usually occurs as complication of III stage of labor. Acute inversion occurs within 24 hours of delivery; and chronic uterine inversion presents after 4 weeks of childbirth or in the non pregnant state. Non puerperal inversion is extremely rare and no estimate of its incidence occurs in the literature. It is often associated with uterine pathology. The most important pathology being prolapsed submucosal fibroid, and less commonly endometrial polyp or neoplasm.¹⁻⁴

We here present a case of non puerperal inversion, which was earlier misdiagnosed as fibroid polyp protruding

through vagina, since there were no risk factors for the inversion. Intraoperatively proper diagnosis was made and inversion corrected by Haultens method.

CASE REPORT

A 25 years old woman presented to OBG OPD with complains of irregular per vaginal bleeding since 6 months, increase in flow since 1 week, associated with lower abdomen pain. She also complained of mass per vagina since 1 week, associated with difficulty in passing urine and constipation since 1 week. She is para 2, with both full term vaginal deliveries at peripheral health centre by trained birth attendant, with no history of difficulties in deliveries, last child birth 3 years back.

Prior to 6 months menstrual cycles were regular with average flow. There was no history of coital difficulties.

On examination

She was average built with pallor ++, pulse rate-102/m, blood pressure-100/60mm Hg. Per abdomen was soft with tenderness +. Local examination- normal external genitalia. Per speculum examination revealed- mass 5*5cms, angry red looking, friable, bleeding on touch protruding in the vagina (Figure 1). Per vagina examination revealed same mass, with cervix completely taken up over the mass.

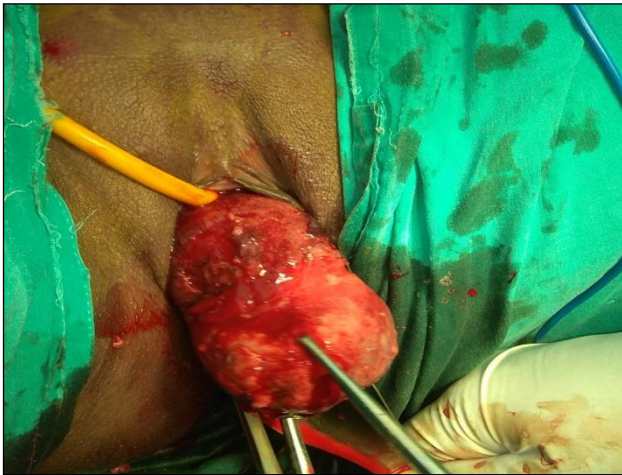

Figure 1: Polyp like mass protruding through vagina.

Investigations

Hb-5.1gm%. LFT and RFT- normal. USG: uterus 9*6.25*3.6, anteverted. ET 8mm. A solitary mass ~5.4*5.5*3.9cms located at posterior cul de sac, homogenous with low level echoes. Ligaments and ovarian ligaments giving a characteristic flower-pot appearance (Figure 2).

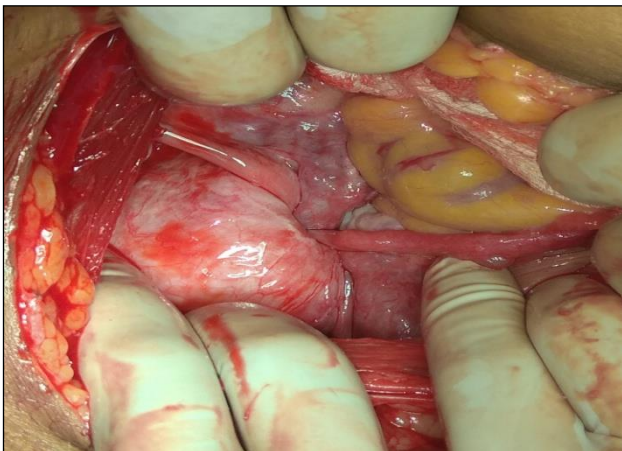


Figure 2: Flower pot appearance on laparotomy showing fundus dipped within the body of uterus along with tubes and ovarian ligaments.

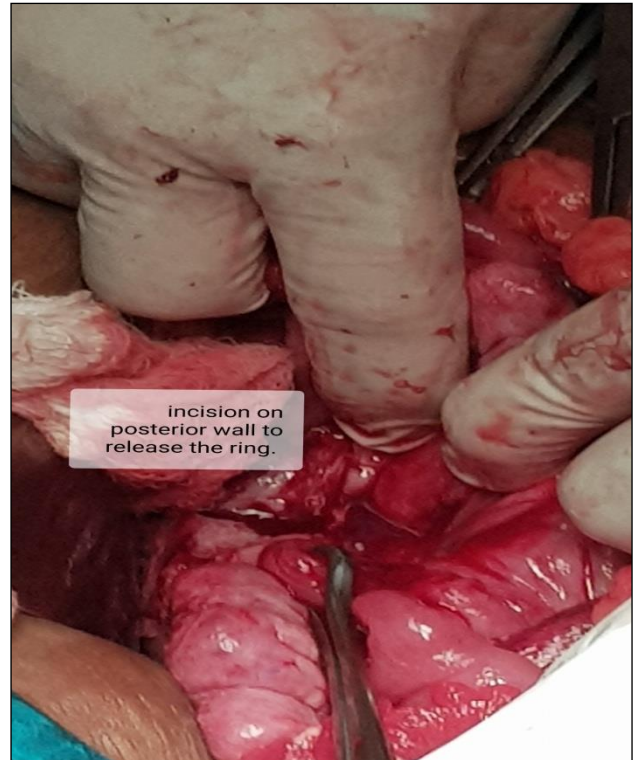

Figure 3: Incision on the posterior uterine wall and the tight cervical ring (Haultens procedure).

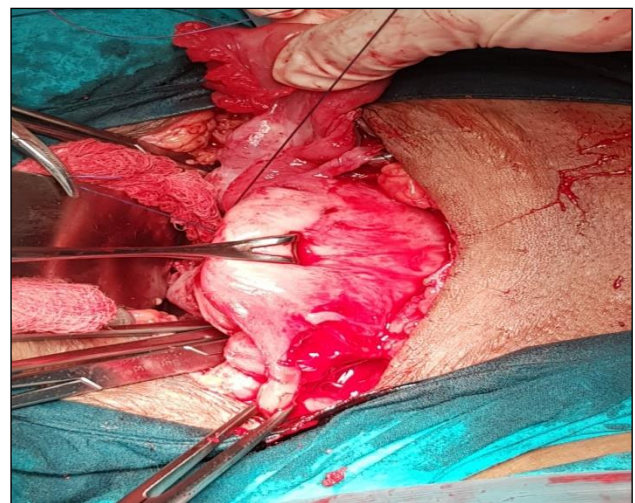


Figure 4: restored uterine anatomy after Haultens procedure.

Huntingtons method was tried pulling the round ligaments with babcock forceps to bring out the fundus but failed because of the tight cervical ring. Thus Haultens method was used, putting a incision in the posterior uterine wall involving the cervical ring (Figure 3) and then vaginal part of the inverted uterine fundus was pushed back to normal anatomic position (Figure 4). Then the posterior uterine incision closed in 2 layers (Figure 5). Because of the young age of patient and no desire for future childbearing bilateral tubal ligation was performed simultaneously.

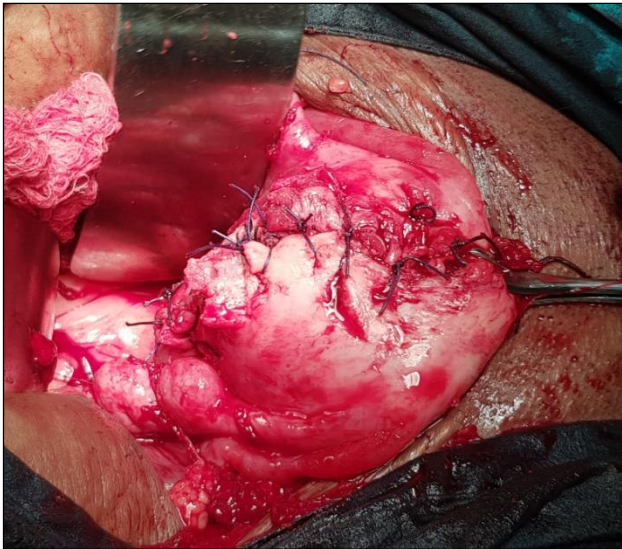


Figure 5: Posterior uterine incision being closed in layers.

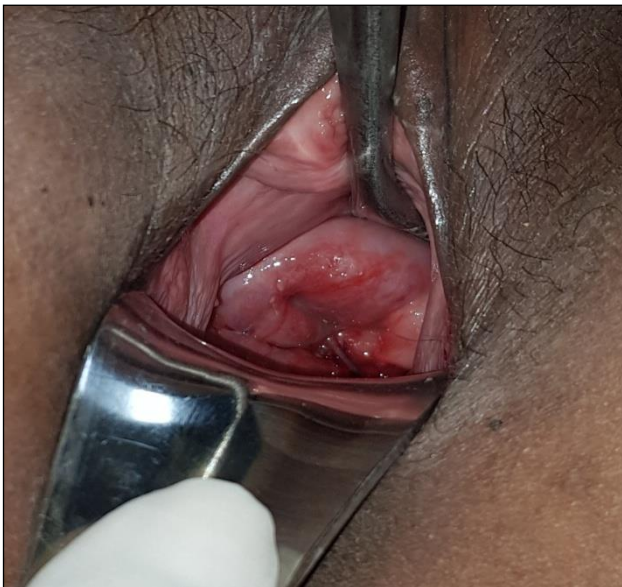

Figure 6: Per speculum examination 2 weeks postoperative showing normal position of cervix.

Patient received total of 5 units of packed RBC transfusion both pre-operative and post operative period. Postoperative course was uneventful and the patient discharged in stable condition on the day 10. On further follow up 2 weeks later patient was doing completely fine.

DISCUSSION

Uterine inversion is a rare, life threatening complication of the third stage of labour. The incidence varies widely between 1 in 2000 to 1 in 50000 deliveries.⁵ Non-puerperal inversion is extremely rare representing about one sixth of all inversion. Uterine leiomyoma (79-85% of cases), leiomyosarcoma, rhabdomyosarcoma, endometrial

polyps, endometrial carcinoma, cervical carcinoma, and total uterovaginal prolapse has been described as possible preceding factors.

Uterine inversion can be classified as

Stage 1: Inverted uterus remains in the uterine cavity. Stage 2: Complete inversion of the fundus through the cervix is seen. Stage 3: Inverted fundus protrudes through vulva. Stage 4: Inversion of the uterus and vaginal wall through the vulva are seen together.⁶

Inversion can also be classified as acute and chronic. Acute uterine inversion causes severe pain and hemorrhage whereas chronic inversion is insidious and characterized by pelvic discomfort, vaginal discharge, irregular vaginal bleeding and anemia.

In acute inversion the uterus can be generally reverted by intravaginal manipulation. In chronic uterine inversions, surgery is imperative. Many surgical methods have been described to treat chronic non puerperal uterine inversion. Huntington and Haultain are commonly used abdominal approaches; whereas Kustner and Spinelli procedures are the commonly used vaginal approaches.⁷

Our case presented late after child delivery in the absence of any high risk factors, even the ultrasonography findings were misleading. The diagnosis is said to be difficult and requires high index of suspicion especially when the inversion is partial.

In doubtful cases of partial inversion, T2 weighted MRI scans are recommended, which show U shaped uterine cavity with inverted uterine fundus on sagittal image and a 'bull eye' appearance on axial image.^{8,9}

Huntington and Haultain techniques are commonly-used abdominal operation procedures. Huntington procedure involves grasping the round ligament and slowly pulling up until the uterus is reinverted. Haultain procedure is incising posterior of the vaginal-cervical ring and carrying up the posterior wall of the uterus until it is reinverted to its normal anatomy. The Kustner and Spinelli vaginal approach procedures could also be used. The Kustner procedure is to enter the pouch of Douglas vaginally and to split the posterior aspect of the uterus and the cervix for reinverting the uterus. In Spinelli operation, an incision is made on the anterior aspect of the cervix and then the uterus is reinverted. Robotic and laparoscopic surgeries have been recently used for chronic uterine inversion.¹⁰

CONCLUSION

The cases of non-puerperal uterine inversion are uncommon and are difficult to manage even for an experienced gynaecologist. High index of suspicion for the diagnosis and clear knowledge about surgery will permit a successful outcome.

ACKNOWLEDGMENTS

Authors would like to thank patient and her relatives for giving willful consent for publishing the case and taking photographs of intra-operative as well as follow up photographs.

Funding: No funding sources

Conflict of interest: None declared

Ethical approval: The study was approved by the Institutional Ethics Committee and the Helsinki Declaration of 1975, as revised in 2008

REFERENCES

1. Rathod S, Samal SK, Pallavee P, Ghose S. Non puerperal uterine inversion in a young female - a case report. J Clin Diagn Res. 2014;8(9):1-2.
2. Pieh-Holder KL, Bell H, Hall T, DeVente JE. Postpartum prolapsed leiomyoma with uterine inversion managed by vaginal hysterectomy. Case Rep Obstet Gynecol. 2014;2014:4351014.
3. Shabbir S, Ghayasuddin M, Younus SM, Baloch K. Chronic non puerperal uterine inversion secondary to sub-mucosal fibroid. J Pak Med Assoc. 2014;64(5):586-8.
4. De Vries M, Perquin DAM. Non-puerperal uterine inversion due to submucous myoma in a young woman: a case report. J Med Case Reports. 2010;4:21.
5. Krenning RA. Nonpuerperal uterine inversion. Review of literature. Clin Exp Obstet Gynecol. 1982;9:12-5.
6. Spinelli PG. Inversion of the uterus. Riv Ginec Comtemp. 1897;11:567-70.
7. Fofie C, Baffoe P. Non puerperal uterine inversion: A case report. Ghana Med J. 2010;44:79-81.
8. Lewin JS, Bryan PJ. MR imaging of uterine inversion. J Comput Assist Tomogr. 1989;13:357-9.
9. Anitha GS, Manjulatha VR, Ramaiah R. Non-puerperal uterine inversion: a case report. Int J Reprod Contracept Obstet Gynecol. 2015;4:1223-6.
10. Zechmeister JR, Levey KA. Successful robotically assisted laparoscopic correction of chronic uterine inversion. J Minim Invasive Gynecol. 2011;18(5):671-3.

Cite this article as: Tile R, Jamkhandi S. Chronic non-puerperal uterine inversion in the absence of risk factors: A rare case report. Int J Reprod Contracept Obstet Gynecol 2019;8:2111-4.