

DOI: <http://dx.doi.org/10.18203/2320-1770.ijrcog20193059>

Case Report

Advanced ovarian pregnancy: an elusive diagnosis

Bhanupriya*

Department of Obstetrics and Gynecology, University College of Medical Science and Guru Tegbahadur Hospital, Delhi, India

Received: 16 April 2019

Revised: 14 May 2019

Accepted: 11 June 2019

***Correspondence:**

Dr. Bhanupriya,

E-mail: drpriyabhanu@gmail.com

Copyright: © the author(s), publisher and licensee Medip Academy. This is an open-access article distributed under the terms of the Creative Commons Attribution Non-Commercial License, which permits unrestricted non-commercial use, distribution, and reproduction in any medium, provided the original work is properly cited.

ABSTRACT

Primary ovarian ectopic is a rare variant of ectopic pregnancies. It is commonly confused with tubal pregnancy aborted over ovary, hemorrhagic ovarian cyst, ruptured corpus luteal cyst. The women with ovarian ectopic generally presents early because of early onset hemorrhage in ovary. This is a rare case where woman with ectopic pregnancy presents at 13 weeks. The clinical picture is also highly unusual with just spotting and fainting attacks at the end of first trimester to make a diagnosis of ectopic pregnancy. The laparotomy done showed an unruptured ovarian ectopic pregnancy and with 350 cc hemoperitoneum. Salpingoophorectomy was done and the ectopic mass was removed as hardly any ovarian tissue was left to conserve the ovary. Hence, clinicians should be cautious enough to keep a differential diagnosis of ectopic even at advanced gestation.

Keywords: Advanced gestation, Laparotomy, Ovarian pregnancy, Salpingoophorectomy

INTRODUCTION

An ectopic pregnancy is defined as any pregnancy implanted or developed outside the uterus. The incidence of ectopic pregnancy is nearly 2-3%.^{1,2} The incidence of extra tubal ectopic pregnancy is <10%, although the incidence of such ectopic pregnancy is trending.³ Primary ectopic pregnancy is a very uncommon event with a prevalence of 1:7000 to 1:40,000.^{4,5} The ovarian ectopic pregnancy are often confused with tubal pregnancy aborted over ovary, hemorrhagic ovarian cyst, ruptured corpus luteal cyst. Despite the recent advances in modern sonography, the diagnosis of ovarian pregnancy is still difficult which necessitates reporting of this case. No

such case report with such an advanced primary ovarian pregnancy has been reported.

CASE REPORT

Twenty-six-year old G3P2L1 at 13 weeks period of gestation with previous 2 cesarean presented to antenatal opd (out-patient department) for routine checkup. Patient had a fainting episode in OPD following which she revealed history of spotting in early gestation also associated with off and on suprapubic vague pain and currently mild pain in lower abdomen for past one day. There was no history of abortifacient intake, intrauterine device insertion or history of pelvic inflammatory disease.

On examination she had hypotension and tachycardia along with guarding and tenderness all over abdomen. A vague ill-defined abdominopelvic mass of approximately 6x6 cm was palpable in right lumbar region. On bimanual pelvic examination uterus was found to be bulky and deviated to left side. The mass felt in abdominal examination was not tipped during pelvic examination. After initial resuscitation, patient was taken up for ultrasound examination. Ultrasonography revealed a gestational sac containing live fetus of 13 weeks gestation separately from uterine cavity. Uterus was examined till the cornual end and it was found to be empty. There was also mild free fluid in pouch of douglas.

Differential diagnosis of bicornuate uterus with pregnancy in one horn or abdominal pregnancy was made and patient was taken up for laparotomy after resuscitation. Intraoperatively 350 cc of hemoperitoneum was drained and uterus was found to be of normal size and shape. Right sided 7x6 cm sized ovarian gestational sac containing fetus was found which ruptured intraoperatively (Figure 1).

Right ovary was not seen separately, but, little right ovarian tissue was present at the base of the mass (Figure 2). The sac was attached to the uterus by the ovarian ligament. Anatomically normal right fallopian tube was seen stretched over the mass. The broad ligament of right side was normal. Left fallopian tube and ovary were absolutely healthy. An intraoperative impression of right ovarian ectopic gestation was made in accordance with Spiegelberg's criterion.

Hardly, any ovarian tissue was visible at base and the large primary ovarian ectopic was adherent near hilum. Therefore, the decision for right salpingoophorectomy was taken. On histopathology, the diagnosis of ovarian ectopic was confirmed. The post-operative period was uneventful and was discharged without any complications. Follow up with β hcg was done, which came down to normal within 2 weeks.

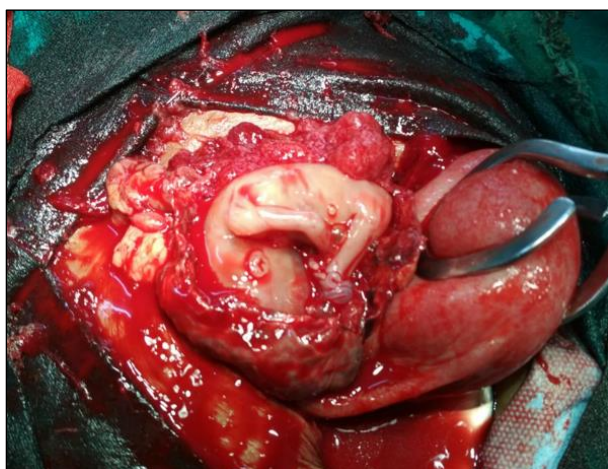

Figure 1: Fetus lying in ruptured ovarian mass, along with normal left tube.

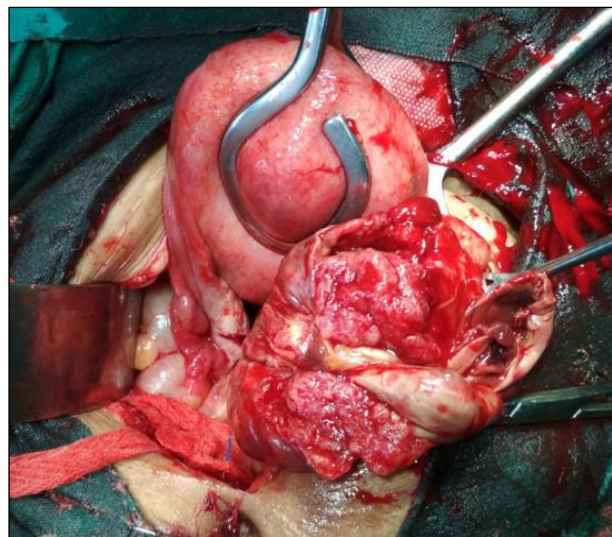


Figure 2: Ruptured ovarian ectopic with normal ovarian tissue.

DISCUSSION

Primary ectopic pregnancy is a rare variant of extrauterine ectopic pregnancy. The diagnosis often gets delayed. The ovarian pregnancy commonly presents in first trimester and are often misdiagnosed with ruptured corpus luteal cyst. In our case also, the diagnosis only could be made after laparotomy. It is rare to find advanced and also unruptured, ovarian ectopic pregnancy. The developing chorionic villi invades the highly vascularized ovarian tissue and can become a cause for the severe hemorrhage. There are many diagnostic as well as therapeutic dilemmas about the management of ovarian ectopic pregnancy. The exact cause of ovarian pregnancy is still obscured. There are a few hypotheses like, hindrance in ova release from unruptured follicle or poor ova pick up ability by tubes. However, in young patients, previous pelvic inflammatory disease, intrauterine device, endometriosis, artificial reproductive techniques are all predisposing factors for ovarian ectopic pregnancy.⁶⁻⁹

The Spielberg criteria for ovarian pregnancy includes (1878)¹⁰-

- Fallopian tube as the affected site must be intact
- The foetal sac must occupy the position of the ovary
- The ovary must be connected to the uterus by ovarian ligament and
- Ovarian tissue must be located in the sac wall.

These criteria are clearly fulfilled in early ovarian pregnancy. However, in advance gestation, the last criteria of visualization of ovarian tissue in the sac wall may not met as only compressed and laminated parenchyma of ovary is left because of the overlying pressure by developing fetus.^{11,12}

The presenting complaints can be highly variable. Most common presenting symptoms include abdominal pain and vaginal bleeding like in other ectopic pregnancies and symptoms can be widely variable from asymptomatic to hemorrhagic shock. This was true in our case also. There were no high risk factors as revealed by our patient. Hence, an intrafollicular fertilization can be postulated as a cause of primary ovarian ectopic pregnancy. The accurate preoperative diagnosis is difficult to establish. The combination of, history of amenorrhea, empty uterus on ultrasonography and adnexal mass with thin sac is not only suggestive of tubal ectopic but also of an ovarian ectopic. Comstock et al, observed ultrasonography of six ovarian pregnancy patients and concluded the presence of hypoechoic ring on or within the surface of ovary in five out of six patients.¹³ Corpus luteum and ovarian pregnancy are differentiated on the basis of echogenicity of hypoechoic ring. The corpus luteum appears less echogenic than rest of ovary while the ovarian pregnancy is more echogenic than rest of the ovary. In our case, the case was misdiagnosed as abdominal pregnancy. Ultrasound revealed a live ectopic pregnancy of 13 weeks with cardiac activity surrounded by a thin sac. There was no evidence of any bowel loops around the gestational sac. Uterus was normal size and cavity was empty. The fallopian tubes also were found to be normal. Medical treatment was not possible as patient was not hemodynamically stable as well as the advanced gestation. Laparotomy was performed and salpingoophorectomy was done.

CONCLUSION

Ovarian pregnancy is a rare variant of ectopic pregnancy. Preoperative diagnosis is difficult to make. Patients generally present in low hemodynamic condition. Surgical management is the treatment of choice. Wedge resection and salpingooperectomy is surgical management of choice.

ACKNOWLEDGMENTS

Authors would like to thank Dr. Shalini Rajaram.

Funding: No funding sources

Conflict of interest: None declared

Ethical approval: Not required

REFERENCES

1. Ranji GG, Usha Rani G, Varshini S. Ectopic pregnancy: risk factors, clinical presentation and management. J Obstet Gynaecol India. 2018;68(6):487-92.
2. Mavrelou D, Nicks H, Jamil A, Hoo W, Jauniaux E, Jurkovic D. Efficacy and safety of a clinical protocol for expectant management of selected women diagnosed with a tubal ectopic pregnancy. Ultrasound Obstet Gynecol. 2013;42(1):102-7.
3. Barnhart K. Ectopic pregnancy. N Engl J Med. 2009;361(4):379-87.
4. Hasegawa L, Nascu P, McNaught J. Ovarian ectopic pregnancy as IVF complication: first report in a gestational carrier. Case Rep Obstet Gynecol. 2018;31:8190805.
5. Marcus SM, Brinsden PR. Primary ovarian pregnancy after in vitro fertilization and embryo transfer: report of seven cases. Fertil Steril. 1993;60(1):167-70.
6. Ghi T, Banfi A, Marconi R, Iaco PD, Pulu G, Aloisio DD, et al. Three-dimensional sonographic diagnosis of ovarian pregnancy. Ultrasound Obstet Gynecol. 2005;26(1):102-4.
7. Einkenkel J, Baier D, Horn LC, Alexander H. Laparoscopic therapy of an intact primary ovarian pregnancy with ovarian hyperstimulation syndrome. Hum Reprod. 2000;15(9):2037-40.
8. Bontis J, Grimbizis G, Tarlatzis B C, Miliaris D, Bili H. Intrafollicular ovarian pregnancy after ovulation induction/intrauterine insemination: pathophysiological aspects and diagnostic problems. Hum Reprod. 1997;12(2):376-8.
9. Marret H, Hamamah S, Alonso AM, Pierre F. Case report and review of the literature: primary twin ovarian pregnancy. Hum Reprod. 1997;12(8):1813-15.
10. Lajoie GL. Ovarian pregnancy. Am J Obstet Gynecol. 1951;62(4):920-9.
11. Goyal LD, Tandon R, Goel P, Sehgal A. Ovarian ectopic pregnancy: A 10 year's experience and review of literature. Iran J Reprod Med. 2014;12(12):825-30.
12. Tehrani HG, Hamoush Z, Hashemi L. Ovarian ectopic pregnancy: a rare case. Iran J Reprod Med. 2014;12(4):281-4.
13. Gupta N, Gupta A, Onyema G, Pantofel Y, Ying SC, Garon JE, et al. Accurate preoperative diagnosis of ovarian pregnancy with transvaginal scan. Case Rep Obstet Gynecol. 2012;2012:934571.

Cite this article as: Bhanupriya. Advanced ovarian pregnancy: an elusive diagnosis. Int J Reprod Contracept Obstet Gynecol 2019;8:2878-80.