

DOI: <http://dx.doi.org/10.18203/2320-1770.ijrcog20194913>

Case Report

## A rare case of conjoined twins presenting as dicephalus parapagus: a case report

Lakshmi Subburaj<sup>1\*</sup>, Rajkumar K.<sup>2</sup>

<sup>1</sup>Department of Obstetrics and Gynaecology, N. T. C. Hospital, Madurai, Tamil Nadu, India

<sup>2</sup>Department of Surgery, N. T. C. Hospital, Madurai, Tamil Nadu, India

**Received:** 06 August 2019

**Accepted:** 07 October 2019

**\*Correspondence:**

Dr. Lakshmi Subburaj,

E-mail: lakmisubburaj@gmail.com

**Copyright:** © the author(s), publisher and licensee Medip Academy. This is an open-access article distributed under the terms of the Creative Commons Attribution Non-Commercial License, which permits unrestricted non-commercial use, distribution, and reproduction in any medium, provided the original work is properly cited.

### ABSTRACT

Conjoined twinning is a congenital abnormality resulting in various presentations of the fetuses in utero. It is a rare embryological developmental disorder occurring in one in 100,000 births. We present a case of conjoined twinning, which is characterized by the presence of two heads, single vertebral column and single symphysis pubis, with single genitor-urinary tract and single gastro intestinal tract. The present condition, referred to as dicephalus parapagus, is a rare entity among the conjoined twinning and has seldom positive outcomes. The mechanism of occurrence of conjoined twinning has been proposed either through fusion or fission of the embryos. In either case, surgical separation of the conjoined twins is often unsuccessful and results in increased morbidity and mortality. However, it is essential to screen for the presence of such congenital anomalies early during pregnancy, in order to terminate and provide parental counselling.

**Keywords:** Anomaly scan, Conjoined twinning, Dicephalus parapagus, Embryology, High-risk pregnancy, Ultrasound

### INTRODUCTION

Conjoined twins is rare embryological developmental disorder which occurs in one in 50000 or one in 100000 births.<sup>1</sup> It is considered to be a malformation and is associated with secondary complications related to abnormal conjoined organs and superimposed effects of abnormal hemo dynamics. Conjoined twinning is a random event and is rarely related to heredity, maternal age or parity.<sup>2</sup>

There are two theories which have been suggested to explain the consequence of events in conjoint twinning. One theory supports fusion process which is seen in most cases with exception of the parapagus type while the

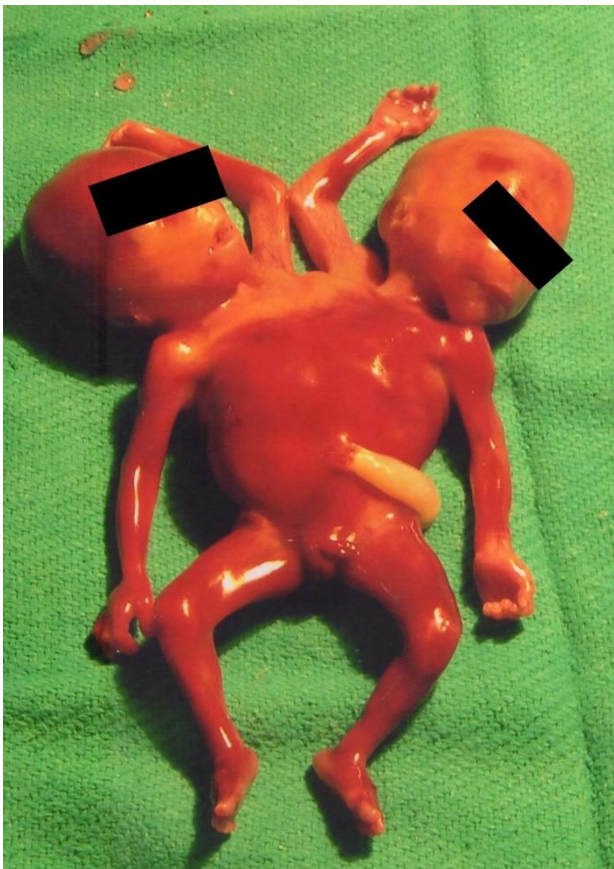
other theory is suggestive of bifurcation of a single notochord.<sup>3,4</sup>

Conjoined twins are mainly classified according to the incomplete or complete duplication of the notochord. There are eight types of conjoint twins according to the prominent sight of union. Most common types of conjoint twinning are thoracopagus or ompholopagus and is found in 42%-75% of the cases. However, it is rare to find Parapagus twins in conjoined twinning. In this case report we present a rare case of dicephalus Parapagus.

### CASE REPORT

We present a case of a pregnant woman with five months amenorrhea (G2P1L1). The first pregnancy was

uneventful and the present pregnancy showed presence of twins in the first trimester ultrasound. During the second trimester, anomaly scan was done, which showed the presence of conjoined twinning of parapagus type. The scan further showed presence of two heads, dithorax and fused abdomen, tetra brachius, single symphysis pubis and two vertebral columns were present. There was no history of any congenital abnormalities in the family and no history of maternal illnesses like diabetes mellitus, hypertension, cardiovascular diseases or any other systemic illnesses. Moreover, maternal age was <35 years. In view of the impending complications adverse outcome and complications our risk was explain to the patient and pregnancy was terminated. The specimen was sent for autopsy which confirmed the findings (Figure 1).



**Figure 1: Dicephalus parapagus autopsy specimen.**

## DISCUSSION

While conjoined twinning is rare phenomenon, it occurs in 1.6% of all pregnancies of which 1.2% are dizygotic and 0.4% are monozygotic. The development process that underlines conjoined twinning is rarely understood. However, studies have shown that the maldevelopment occurs due to secondary union of the mono-ovular embryonic discs. Parapagus twins lie side by side with venterolateral fusion. These twins are conjoined in the chest region with joined liver and diaphragm but separate respiratory and upper gastrointestinal tract, with two arms and two legs and usually complete set of spinal

cords and vertical column. However, they share the genito urinary system and lower gastrointestinal tract.<sup>5,6</sup>

Several studies have demonstrated the theories based on the mechanism of conjoined twinning. While the more widely accepted is the fusion theory, parapagus is often an event of fission of mono amniotic twins. According to the fission theory, conjoint twins occur when the fertilized ovum is split in two identical twins but the process is interrupted in some point and results in development of two partially formed individuals attached together.<sup>7</sup> In contrast, the fusion theory proposes that two mono ovular empirical discs lie adjacent to one another at various angles and become secondly united dorsally, caudally, laterally or dorsally and symmetrically or asymmetrically but always homologous.<sup>8</sup>

A study done by Mutchinick et al demonstrated that the incidence of conjoined twinning was 1.47 per 100,000 births. There has been a marked variation in the surveillance programs and has shown that highest prevalence was found to be in Finland with 3.22 per 100,000 births and it has been as low as 0.08 per 100,000 births in Italy. Besides Finland the other countries with increased prevalence were South America, Mexico, and Germany. However, there were poor records to document incidence of conjoined twinning in developing countries like India.<sup>1</sup> Out of the several types of conjoined twinning dicephalus parapagus was present in hardly 10 cases of conjoined twinning all over the World and majority of this presentation was seen in South America followed by Hungary and China and then followed by Mexico. Overall the prevalence of dicephalus parapagus was 11.6% among the conjoined twinnings.<sup>1</sup>

Although, there are very few studies which clinically establish the risk factors of such conjoined twinning there is an increase need for appropriate prenatal diagnosis in order to screen and detect the presence of anomalies early in the pregnancy. A prenatal diagnosis conjoined twinning is carried out by ultrasonographic examination which is used as a screening tool. Ultrasound findings which suggest the presence of conjoined twins include bibreech and bicephalic position, single inseperable trunk which continues in external skin contour, face to face position of fetuses, hyper extension of both cervical spines, constant relative fetal position, fetal extremities in unusual proximity, solitary large liver and heart, solitary umbilical cord with more than 3 vessels and fetal body parts at the same level etc.<sup>9-12</sup> However, the confirmatory investigations of choice are amniography and fetoscopy. Amniography has been replaced by fetography in recent times which is an oil contrast medium used for demonstrating finer details compared to amniography. Apart from this examination magnetic resonance imaging can also be carried out to detect conjoined twinning.<sup>13</sup>

The clinical outcome of conjoined twins is not often positive. Majority of the twins usually die as still born or die shortly after birth. There are several complications

involving the normal physiology and anatomy of the conjoined twins thereby resulting in severe disorders and functional abnormalities. The separation of conjoined twins has been long attempted and is rarely successful. Successful surgeries have been done for conditions like thoracopagus while it is rarely possible to succeed in separations of conjoined twins twinning like dicephalus parapagus. It is ideal to screen early for detecting the anomalies and it is always advisable to terminate the pregnancy as early as possible instead of attempting separation which not only involves cost and time but also is a painful and wasteful exercise for both physicians and the parents.

## CONCLUSION

Conjoined twinning is very rare congenital anomaly occurring in about 1 and 100,000 births. There are several types of conjoined twinning of which dicephalus parapagus is one of the rarest forms which is characterized by presence of two heads, fused abdomen and single symphysis pubis with two separate vertebral columns and share genito urinary and gastro intestinal tract. Conjoined twinning can be detected as early as during the second trimester anomaly scan with the help of the ultrasonographic findings. A confirmatory diagnosis can be obtained are MRI which gives a candid picture of the type of conjoined twin. It is very rare to have a successful separation of conjoined twins after delivery and this is associated with several systemic complications and disabilities. It is often preferable to detect early and terminate the pregnancy.

*Funding: No funding sources*

*Conflict of interest: None declared*

*Ethical approval: Not required*

## REFERENCES

1. Mutchinik OM, Luna-Munoz L, Amar E, Bakker MK, Clementi M, Cocchi G, et al. Conjoined twins: a worldwide collaborative epidemiological study of the international clearinghouse for birth defects surveillance and research. *Am J Med Genet C Semin Med Genet.* 2011;4:274-87.
2. Barth RA, Filly RA, Goldberg JD, Moore P, Silverman NH. Conjoined twins: prenatal diagnosis and assessment of associated malformations. *Radiol.* 1990;177(1):201-7.
3. Logroño R, Garcia-Lithgow C, Harris C, Kent M, Meisner L. Heteropagus conjoined twins due to fusion of two embryos: report and review. *Am J Med Genet.* 1997;73(3):239-43.
4. Machin GA. Heteropagus conjoined twins due to fusion of two embryos. *Am J Med Genet.* 1998;78(4):388-90.
5. Spencer R. Theoretical and analytical embryology of conjoined twins: part I: embryogenesis. *Clin Anat.* 2000;13(1):36-53.
6. Spencer R. Conjoined twins: theoretical embryologic basis. *Teratol.* 1992;45(6):591-602.
7. Harma M, Harma M, Mil Z, Oksuzler C Vaginal delivery of dicephalic parapagus conjoined twins: case report and literature review. *Tohoku J Exp Med.* 2005;205(2):179-85.
8. Mabogunje OA, Lawrie JH. Conjoined twins in West Africa. *Arch Dis Child.* 1980;55(8):626-30.
9. Harper RG, Kenigsberg K, Sia CG, Horn D, Stern D, Bongiovi V. Xiphopagus conjoined twins: A 300-year review of the obstetric, morphopathologic, neonatal and surgical parameters. *Am J Obstet Gynecol.* 1980;137:617-29.
10. Wedberg R, Kaplan C, Leopold G, Porreco R, Resnik R, Benirschke K. Cephalothoracopagus (Janiceps) twinning. *Obstet Gynecol.* 1979;54:392-6.
11. Wilson RL, Shaub MS, Cetrulo CJ. The antepartum findings of conjoined twins. *J Clin Ultrasound.* 1977;5:35-7.
12. Austin E, Schiffrin BS, Pomerance JJ, Gans SL, Komaiko MS. The antepartum diagnosis of conjoined twins. *J Pediatr Sur.* 1980;15:332-4.
13. Turner RJ, Hankins GDV, Weinreb JC. Magnetic resonance imaging and ultrasonography in the antenatal evaluation of conjoined twins. *Am J Obstet Gynecol.* 1986;155:645-9.

**Cite this article as:** Subburaj L, Rajkumar K. A rare case of conjoined twins presenting as dicephalus parapagus: a case report. *Int J Reprod Contracept Obstet Gynecol* 2019;8:4633-5.