

DOI: <http://dx.doi.org/10.18203/2320-1770.ijrcog20203347>

Case Report

## Xanthomatous oophoritis, a rare pathology: case report with review of literature

Basanta Manjari Hota, Kavitha Bakshi, Naimisha Movva\*, Swathi Pandirala

Department of Obstetrics and Gynecology, Mamata Medical College, Khammam, Telangana, India

Received: 05 June 2020

Accepted: 07 July 2020

### \*Correspondence:

Dr. Naimisha Movva,

E-mail: [naimishamovva@gmail.com](mailto:naimishamovva@gmail.com)

**Copyright:** © the author(s), publisher and licensee Medip Academy. This is an open-access article distributed under the terms of the Creative Commons Attribution Non-Commercial License, which permits unrestricted non-commercial use, distribution, and reproduction in any medium, provided the original work is properly cited.

### ABSTRACT

Xanthomatous oophoritis is a rare chronic inflammation of ovary characterized histologically with infiltration of lipid laden foamy macrophages, lymphocytes, plasma cells leading to tissue destruction. Though exact cause is not known, uterine artery embolization, gloves dusting powder and altered lipid metabolism are hypothesized to cause the pathology. A 28-year-old parous lady with history of multiple laparotomies, known case of hypothyroidism under treatment and history of adequately treated pulmonary tuberculosis was diagnosed to have right ovarian dermoid cyst, while undergoing investigation for secondary infertility. On examination she had pallor, healthy abdominal scar, and small tender fixed mass in right fornix on internal examination. She was subjected to laparotomy and right salpingo oophorectomy with left salpingectomy was performed. Histopathological examination of the resected specimen revealed to be xanthomatous oophoritis of right ovary. As this condition mimics tuberculosis and malignancy, clinical assessment, investigation and intra operative findings with the suspicion of inflammatory aetiology help to limit the extent of surgery. Hence, this case is presented for its rare occurrence as well as its need to be differentiated from other conditions like tuberculosis and malignancy of ovary.

**Keywords:** Histopathology, Ovarian tumors, Xanthomatous oophoritis

### INTRODUCTION

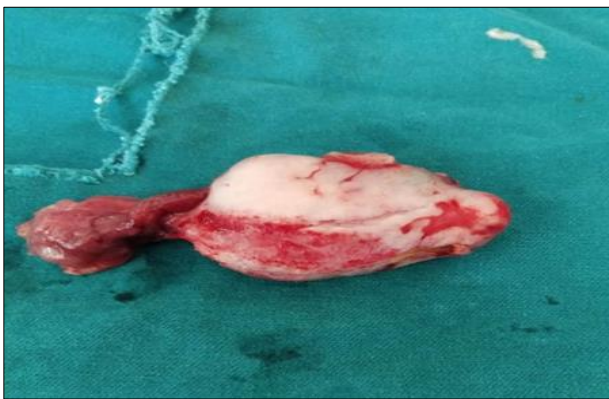
Xanthomatous oophoritis is a chronic inflammatory lesion of ovary leading to functional failure due to structural destruction of the organ.<sup>1</sup> It is diagnosed histologically by accumulation of lipid laden foamy macrophages (foamy histiocytes), lymphocytes, plasma cells.<sup>2</sup> Though exact aetiology is not clearly known, different hypothesis have been postulated for its etiopathogenesis. This inflammation may be infectious in origin. Usually organisms like *E coli*, *Staphylococcus aureus* and *Actinomyces species* are responsible for this condition.<sup>3-5</sup> Pelvic inflammatory disease, intra uterine contraceptive device, endometriosis are also courted as the cause by some authors.<sup>6-8</sup> Other inflammatory conditions like Crohn's disease, diverticulitis and response to gloves dusting powder during previous laparotomy are also thought to be responsible for this

disease.<sup>9-11</sup> Cases have been reported following uterine artery embolization.<sup>12</sup> Involvement of female genital organ is rare and if detected usually endometrium is affected.<sup>13,14</sup> Here authors report a case of xanthomatous oophoritis diagnosed by ultrasound as dermoid cyst in the process of investigation for secondary infertility.

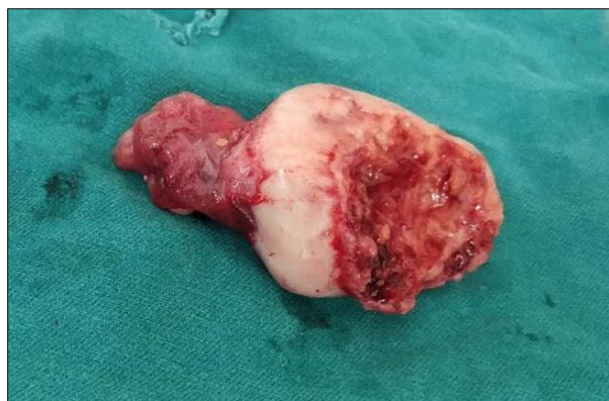### CASE REPORT

A 28-year parous lady reported to gynecology outpatient department of this institution for dermoid cyst of ovary, diagnosed incidentally by ultrasound while being investigated for secondary infertility of 2 years duration. Otherwise she was asymptomatic. She was married for last 7 years from the day of reporting to us. She was living with her husband with history of regular sexual intercourse without any contraception. Her menstrual history was within normal limit. The patient conceived

spontaneously and delivered at term by emergency lower segment caesarean section 6 years back for fetal distress in labour. Second pregnancy was terminated 5 years back by hysterotomy in second trimester for fetal congenital anomaly. Both surgeries and post-operative periods were uneventful. She was diagnosed with pulmonary tuberculosis 4 years back and completed 6 months of anti-tubercular treatment. Same year, she had small gut obstruction, for which she underwent laparotomy and resection anastomosis of small intestine. On sixth post-operative day she developed peritonitis, for which she underwent re laparotomy and repair for disrupted anastomotic leak. She responded well. Again, she had undergone mesh repair for incisional hernia 02 years back. She was a known case of hypothyroidism under treatment. There was no history suggestive of pelvic inflammatory disease.



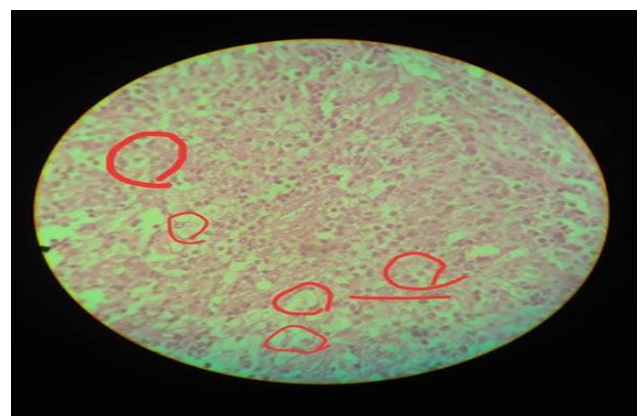
**Figure 1: Resected specimen of right ovary with right fallopian tube.**



**Figure 2: Rt. ovary inside view of ruptured cyst with right fallopian tube.**

On general examination, her height was 161 cm and weight were 52 kg. Her vital parameters were normal. Moderate Pallor was detected. No clinically detectable abnormality was found in respiratory, cardio vascular and central nervous system. Abdomen showed a healthy sub-umbilical midline vertical scar. There was no abdominal distension. No mass was found on palpation. On per speculum examination no abnormality was detected.

Bimanual digital examination found normal parous uterus. Cervical movement was non tender. A tender fixed mass of size 5×4 cms. in right fornix was noted. On investigation her haemoglobin was 8 gm%; PCV was 28%; ESR was 45 mm/1<sup>st</sup> hour and total and differential white cell count were within normal range. Peripheral smear showed iron deficiency anaemia. Biochemical parameters and urinalysis were normal. Chest X-ray PA view and ECG did not show any abnormality. Ultra sound pelvis detected right ovarian cyst of size 5×3 cms, with mixed echogenicity, internal calcification with no increased vascularity and diagnosed as dermoid cyst. Patient was transfused with 2 units of cross matched blood. As she had undergone so many surgeries the patient decided for sterilization procure. She was planned for right salpingo oophorectomy and left salpingectomy. Laparotomy was preferred to laparoscopy for history of repeated laparotomy, tuberculosis, gut surgery and peritonitis. Abdomen was opened by Pfannenstiel incision. There was no free fluid in peritoneal cavity. Uterus and both the fallopian tubes as well as the left ovary appeared healthy. Right ovarian cyst of 5×4 cms was found adherent to lateral pelvic wall and large gut. In the process of handling, it got detached and ruptured discharging about 10 ml of thin greyish white fluid. Bacteriological test including Ziehl Neelsen stain of the same was sent. There was no active bleeding from pelvic wall needing interference, but the serosal disruption on gut was repaired. Right salpingo oophorectomy with left salpingectomy was done. On gross examination surface of right ovary was greyish pink, the cavity and adherent surface was inflamed with patches of yellowish and white areas (Figures 1 and 2). The entire excised specimen was sent for histological examination with adequate information about her history specially to exclude tuberculosis. Her post-operative period was uneventful. Bacteriological test including that for acid fast bacilli came negative. Histopathology report of right ovarian mass, showed features of xanthomatous oophoritis (Figure 3). Both the fallopian tubes did not reveal any abnormality. On follow up of 1.5 years, the patient was found to be asymptomatic.



**Figure 3: Histopathology of infiltration of ovarian stroma with foamy histiocytes (marked with circles) and inflammatory cells.**

## DISCUSSION

Kunakemakorn in 1976 was the first to report a case of xanthogranulomatous inflammation of serosa of the uterus, left fallopian tube and ovary.<sup>15</sup> Total of 29 cases of xanthomatous salpingo oophoritis are reported till date.<sup>14</sup> Only 15 cases of xanthomatous lesion affecting female genital organs including a few cases involving ovary have been reported in India by now.<sup>16</sup> Though age is not a bar, it is commonly seen in reproductive age group with a median age of 38.5 years (range of 23-72 years).<sup>17</sup> The lowest age as reported in literature is a case in a 2 years old girl.<sup>18</sup> In this case patient was 28-year-old. Usual presentation of this entity is with features of chronic pelvic infection and ovarian or tubo ovarian mass. So many times, it is confused with malignancy or tuberculosis and both the conditions need to be excluded by clinical examination, investigation, intra operative findings and histopathology report. In this case patient was asymptomatic and reported with ultrasound diagnosis of dermoid cyst. As her other ovary was healthy the cause of secondary infertility might not be the present pathology. Considering her age, multiparity, history of multiple laparotomies in the past, the most probable predisposing factor in this case patient might be subclinical pelvic infection or gloves dusting powder of previous laparotomies. Xanthomatous oophoritis associated with bowel obstruction have been reported though in this case she had bowel obstruction 4 years before the ovarian pathology was detected.<sup>19</sup> Clinical finding and imaging usually mimic tubo ovarian mass or malignancy.<sup>20</sup> Like this case patient was diagnosed with dermoid cyst ovary on ultrasound.

In this case, CT or MRI was not done as there was no features of malignancy both clinically and by ultrasound. Histological features may mimic a condition called Malakoplakia, where the foamy histiocytes have eosinophilic granular cytoplasm (Von Hansemann histiocytes) and show the cytoplasmic concentric calcific bodies known as Michaelis-Gutmann bodies which are absent in xanthogranulomatous inflammation.<sup>14</sup> Immunohistochemical stains are helpful in establishing the diagnosis, including CD 68 for histiocytes, CD 20 for B lymphocytes and CD 3 for T lymphocytes. Both the conditions may share a common pathogenesis.<sup>21</sup> In this case patient recovered well postoperatively and during 1.5 years of follow-up, she was found to be asymptomatic.

## CONCLUSION

Xanthomatous oophoritis, a rare inflammatory condition of uncertain aetiology leads to functional failure of the organ. Though it mimics tuberculosis and malignancy, intra-operative findings and suspicion of the pathology in addition to pre-operative investigations help to take the decision for limited surgical excision with a good prognosis.

*Funding: No funding sources*

*Conflict of interest: None declared*

*Ethical approval: Not required*

## REFERENCES

1. Jung SE, Lee JM, Lee KY, Han KT, Hahn ST. Xanthogranulomatous Oophoritis: MR Imaging findings with pathologic correlation. *AJR.* 2002;178:749-51.
2. Franco V, Florena AM, Guarneri G, Gargano G. Xanthogranulomatous salpingitis: case report and review of literature. *Acta Europaea Fertilitatis.* 1990;21(4):197-9.
3. Edelman DA, Berger GS. Contraceptive practice and tubo ovarian abscess. *Am J Obstet Gynecol.* 1980;138:541-4.
4. Dawood MY, Birnbaum SJ. Unilateral tubo-ovarian abscess and intrauterine contraceptive device. *Obstet Gynecol.* 1975;46:429-32.
5. Niebyl JR, Parmley TH, Spence MR, Woodruff D. Unilateral ovarian abscess associated with the intrauterine device. *Obstet Gynecol.* 1978;52:165-8.
6. Abeyundara PK, Padumadasa GS, Tissera WG, Wijesinghe PS. Xanthomatous salpingitis and oophoritis associated with endometriosis and uterine leiomyoma presenting as intestinal obstruction. *J Obstet Gynaecol Res.* 2012;38:1115-7.
7. Chouairy CJ, Hajal EA, Nehme YA. Xanthomatous oophoritis secondary to talcum powder. Case report and review of the literature. *J Med Liban.* 2012;60:169-72.
8. Altanis S, Raweily E, Katesmark M. Xanthomatous endometritis and oophoritis secondary to diverticulitis. A rare cause of postmenopausal bleeding. *J Obstet Gynaecol.* 2007;27:746-7.
9. Wlodarski FM, Trainer TD. Granulomatous oophoritis and salpingitis associated with Crohn's disease of the appendix. *Am J Obstet Gynecol.* 1975;122:527-8.
10. McEntee GP, Goughlan M, Corrigan T, Dervan P. Pelvic inflammatory pseudotumor: problems in clinical and histologic diagnosis: case report. *Br J Obstet Gynaecol.* 1985;92:1067-9.
11. Singh UR, Revathi G, Gita R. Xanthogranulomatous oophoritis: an unusual complication of typhoid. *J Obstet Gynaecol.* 1995;21:433-6.
12. Singh N, Tripathi R, Mala YM, Arora S. Xanthomatous oophoritis following uterine artery embolisation: Successful conservative surgical management with favourable outcome. *Case Reports.* 2013;2013:bcr2013010184.
13. Gray Y, Libbey NP. Xanthomatous salpingitis and oophoritis. *Arch Pathol Lab Med.* 2001;125(2):260-3.
14. Khan B, Aziz AB, Ahmed R. Case of Xanthogranulomatous oophoritis. *J Ayub Med Coll Abbottabad.* 2017;29(1):162-4.

15. Kunakemakorn P, Ontai G, Balin H. Pelvic inflammatory pseudotumor: a case report. *Am J Obstet Gynecol.* 1976;126(2):286-7.
16. Bhatnagar K, Narang V, Garg B, Sood N. Xanthogranulomatous oophoritis: a rare case report. *Iran J Pathol.* 2018;13(3):372-6.
17. Zhang XS, Dong HY, Zhang LL, Desouki MM, Zhao C. Xanthogranulomatous inflammation of the female genital tract: report of three cases. *J Cancer.* 2012;3:100-6.
18. Tanwar H, Joshi A, Wagaskar V, Kini S, Bachhav M. Xanthogranulomatous salpingo-oophoritis: the youngest documented case report. *Case Rep Obstet Gynecol.* 2015.
19. Son J, Raetskaya-Solntseva O, Tirman PA, Water GS, Kelly MG. Xanthogranulomatous oophoritis presenting as an adenexal mass and bowel obstruction. A case report. *J Reprod Med.* 2015;60:273-6.
20. Sharma S, Phadnis P, Kudva R, Valiathan M, Shetty J. Xanthogranulomatous salpingo-oophoritis presenting as a tubo-ovarian mass-a case report with brief review of literature. *Int J Health Sci Res.* 2016;6(3):316-9.
21. Walther M, Glenn JF, Vellios F. Xanthogranulomatous cystitis. *J Urol.* 1985;134(4):745-6.

**Cite this article as:** Hota BM, Bakshi K, Movva N, Pandirla S. Xanthomatous oophoritis, a rare pathology: case report with review of literature. *Int J Reprod Contracept Obstet Gynecol* 2020;9:3486-9.