

DOI: <https://dx.doi.org/10.18203/2320-1770.ijrcog20205814>

## Case Report

# A case of atypical leiomyoma mimicking as endometrial cancer

Priyanka Bhadana, Abha Kiran\*, Kriti Bhkuni, Veena G. Malla

Department of Obstetrics and Gynecology, ABVIMS and Dr. RML Hospital, New Delhi, India

**Received:** 06 November 2020

**Accepted:** 10 December 2020

**\*Correspondence:**

Dr. Abha Kiran,

E-mail: [kiran.abha05@gmail.com](mailto:kiran.abha05@gmail.com)

**Copyright:** © the author(s), publisher and licensee Medip Academy. This is an open-access article distributed under the terms of the Creative Commons Attribution Non-Commercial License, which permits unrestricted non-commercial use, distribution, and reproduction in any medium, provided the original work is properly cited.

### ABSTRACT

Atypical leiomyoma or leiomyoma with bizarre nucleus is diagnosed on histopathological examination characterized by severe cytological atypia in the form of nuclear enlargement, multi nucleation, hyperchromasia, coarse chromatin and prominent nuclei. These tumours do not have typical features of necrosis or mitotic figures to characterize them as leiomyosarcoma. There are 2% risk of these tumours to convert to leiomyosarcoma. 50-year P3L3A1 postmenopausal for past 6 years presented to gynaecology outpatient department (GOPD) with complains of pain in lower abdomen for past 1 year. Patient was examined and investigated. On clinical examination there was no apparent finding. On radiological examination a well-defined hypoechoic lesion of 6.4×5.7 cm<sup>2</sup> was found arising from uterus. Contrast enhanced computed tomography (CECT) abdomen showed heterogenous mass involving endometrium and myometrium likely neoplastic. Total abdominal hysterectomy with bilateral salpingoophorectomy was done. Histopathological examination (HPE) report revealed features of atypical leiomyoma. Patient is under follow up in GOPD.

**Keywords:** Atypical leiomyoma, Endometrial cancer

### INTRODUCTION

Leiomyoma of uterus are the most common tumour of female reproductive tract.<sup>1</sup> Among all the variant atypical leiomyoma is rare variant sharing certain histopathological features and genetic mutation with leiomyosarcoma posing difficulty in preoperative diagnosis and management.<sup>2</sup> This case is unique as patient was postmenopausal and presumptive diagnosis after clinical and radiological investigation was malignancy but histopathological examination (HPE) revealed atypical leiomyoma.

### CASE REPORT

50 years old female with 3 live issues and 1 abortion, postmenopausal for last 6 years presented in gynaecological outpatient department (OPD) with lower abdominal pain which increased in intensity over one year. Pain abdomen was associated with loss of appetite, weight loss and bladder complaints. Previous menstrual cycle was normal. There was no significant past history or family history.

### Examination

General condition of the patient was stable. Patient was oriented to time person and place. Other systemic examination finding were normal.

On per abdomen examination the abdomen was soft. There were no organomegaly.

On per speculum examination there was a normal looking cervix without any discharged or growth. Vagina was healthy.

On ultrasound uterus was normal in size in hypoechoic lesion of size 6.4×5.7 cm arising from the anterior wall of uterus suggestive of either fibroid.

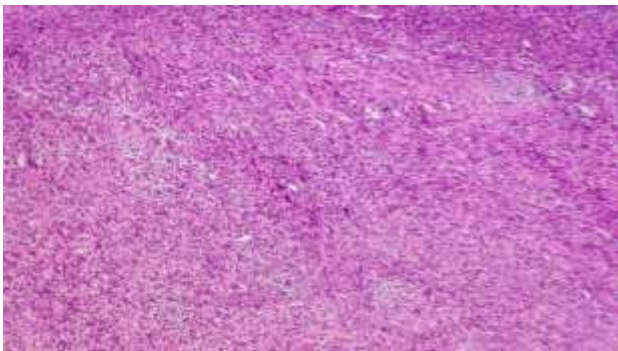
On contrast enhanced computed tomography scan (CECT) there was a mass involving endometrium and myometrium suggestive of some neoplasia.

Tumour markers like CA-125, CEA19.9 and CEA were within normal limit. PAPS study was normal. Endometrial biopsy results were inconclusive.

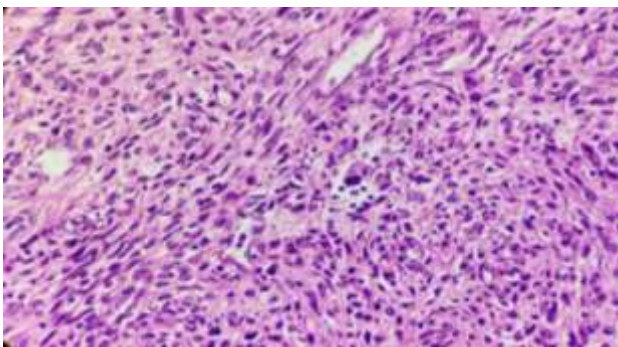
### Management

Patient was planned for total abdominal hysterectomy and bilateral salpingoophorectomy. Gross specimen was 10 weeks uniformly enlarged uterus with no evidence of any degeneration, necrotic areas and haemorrhagic spots. Specimen of bilateral fallopian tubes and ovaries were normal.

Histopathology reports revealed spindle cell tumor with moderate nuclear pleomorphism and mitotic activity 3-4/HPF suggestive of atypical leiomyoma (Figure 1 and 2).



**Figure 1: Histopathological slide at 200 magnification showing sheets of spindle shaped cells.**



**Figure 2: Histopathological slide at 400 magnification showing nuclear pleomorphism and mitotic activity.**

### DISCUSSION

Most common tumour of uterus is smooth muscle tumour. Smooth muscle tumours includes benign leiomyoma and its variants, intravenous leiomyomatosis, smooth muscle tumours of uncertain malignant potential and leiomyosarcoma.<sup>3</sup>

On gross inspection leiomyomas can vary from few centimetres to large masses. It is well circumscribed and has a firm and rubbery texture. On microscopic examinations there are sheets of smooth muscle cells.

Mitotic figures can be present. Genes most commonly mutated in leiomyoma is MED12 (located in exon 2 at the codon 44 position), HMGA1 or HMGA2 overexpression (translocation involving 6p21 and 12q14) but lacks TP53 mutation.<sup>4</sup> In 2014, World Health Organization (WHO) has classified different variant of leiomyoma; cellular leiomyoma, leiomyoma with bizarre nucleus, mitotically active leiomyoma, hydropic leiomyoma, apoplectic leiomyoma, epithelioid leiomyoma, myxoid leiomyoma and dissecting (cotyledonoid) leiomyoma. Cellular leiomyomata have heavy haematoxylin staining indicating abundance of nuclei than extracellular component. There is no TP53 mutation but have PTEN and MED12 mutation. Leiomyomata with increased mitotic activity have up to 15 mitosis/10 HPF. They have frequent MED12 mutations and less of abnormal expression of HMGA2 or FH. Epithelioid leiomyoma similar to conventional leiomyomas are masses of extracellular matrix surrounding small islands of rounded smooth muscle cells giving pseudo-epithelioid appearance. There is no cytogenetic difference from typical leiomyoma. Myxoid leiomyomas have abundant myxoid material separating smooth muscle cells. Cytological atypia, infiltrating margin and mitotic rate more than 2/HPF helps differentiating myxoid leiomyosarcoma from myxoid leiomyoma. It has to be differentiated from myxoid degeneration, myxoid leiomyosarcomas and inflammatory myofibroblastic tumor. Dissecting leiomyoma are called so because they have characteristics tongue like projections of benign appearing smooth muscle neoplasia with hydropic changes dissecting the surrounding myometrium. There is no atypia, necrosis or mitotic activity.<sup>5</sup> Leiomyosarcoma are large, grey, yellow or tan and soft with visible necrotic and/or haemorrhagic foci and demonstrates irregular infiltrate of surrounding myometrium. On microscopic examination there is hyperchromatic atypical spindle shaped tumor cells growing in fascicles and have eosinophilic cytoplasm. When tumor cell necrosis is present in a smooth muscle neoplasm with at least diffusely moderate nuclear atypia then mitotic finding is not critical for diagnosis of leiomyosarcoma but if tumor cell necrosis is absent then diffuse moderate nuclear atypia and mitotic figure more than 10/HPF is required. Leiomyosarcoma stain positive for smooth muscle markers like smooth muscle actin (SMA), desmin and caldesmon. They also express p16, p53, ki67, ER and PR.<sup>6</sup> Differential diagnosis of leiomyosarcoma includes smooth muscle tumor of unknown malignant potential (STUMP) and atypical leiomyoma. Atypical leiomyoma resembles grossly with any other leiomyoma and differentiation with radiological findings is difficult due to rare reporting of cases.<sup>7</sup> Atypical leiomyoma has cytologic atypia but no tumor necrosis and mitotic activity limited to 10/HPF. They have mutation similar to leiomyosarcomas like TP53, MED12 and PTEN deletion. In a case study of 51 cases of atypical leiomyomas by Ly et al 59% of histopathological slides had diffuse atypical cells, 41% had focal distribution of atypical cells. 72% patients had  $\leq 1$  mitotic figure/10 HPF whereas 41% had 1 to 3 mitotic figure/HPF.<sup>8</sup>

## CONCLUSION

Diagnosis usually made postoperatively by histopathological examination and immunohistochemistry. Mode of treatment is hysterectomy although myomectomy may be performed if future fertility is desired. Large number of cases and follow up is required to reach a judgment of origin of atypical leiomyoma and leiomyosarcoma.

*Funding: No funding sources*

*Conflict of interest: None declared*

*Ethical approval: Not required*

## REFERENCES

1. Stewart EA. Uterine fibroids. Lancet. 2001;375(9252):293-8.
2. Mill AM, Ly A, Balzer BL. Cell cycle regulatory markers in uterine leiomyoma with leiomyosarcoma: immunohistochemistry study of 68 cases with clinical follow up. Am J Surg Pathol. 2013;37:634-42.
3. WHO histological classification of tumor of uterine corpus. IARC publication:218.
4. Makinen N, Kampjarvi K, Frizell N, Butzow R, Vahteristo P. Charecterization of MED12 HMGA2 FH alteration reveals molecular variability in uterine smooth muscle tumors. Molecular cancer. 2017;16:101.
5. Ersoz S, Turgutalp H, Mungan S, Guvendi G, Guven S. Cotyledonoid leiomyoma of uterus a case report. Turk Patoloji Derg. 2011;27(3):257-60.
6. Atkins KA, Arronte N, Darus CJ. The use of p16 in enhancing the histologic classification of uterus smooth muscle tumors. Am J Surg Pathol. 2008;32(1):98-102.
7. Arleo E, Schwartz P, Hui P, Mccarthy S. Review of Leiomyoma variant. Am J Roentgenol. 2015;205(4):912-21.
8. Ly A, Amy MD, McKenny M, Balzer JK. Atypical Leiomyoma of the uterus A clinicopathologic study of 51 cases. Am J Surg Pathol. 2013;37(5):643-9.

**Cite this article as:** Bhadana P, Kiran A, Bhkuni K, Malla VG. A case of atypical leiomyoma mimicking as endometrial cancer. Int J Reprod Contracept Obstet Gynecol 2021;10:416-8.